

## Original Research Article

# Clinicopathological study of testicular tumors: an experience in a tertiary care hospital in Kashmir valley, Jammu and Kashmir, India

Ambreen Beigh<sup>1\*</sup>, Sheikh Junaid<sup>2</sup>, Arshi Beg<sup>1</sup>, Summyia Farooq<sup>1</sup>,  
Lateef Ahmed Wani<sup>1</sup>, Farzana Manzoor<sup>1</sup>

<sup>1</sup>Department of Pathology, Government Medical College, Srinagar, Jammu and Kashmir, India

<sup>2</sup>Department of Surgery, Government Medical College, Srinagar, Jammu and Kashmir, India

**Received:** 02 April 2017

**Accepted:** 28 April 2017

### \*Correspondence:

Dr. Ambreen Beigh,

E-mail: [Ambreenbeigh26@gmail.com](mailto:Ambreenbeigh26@gmail.com)

**Copyright:** © the author(s), publisher and licensee Medip Academy. This is an open-access article distributed under the terms of the Creative Commons Attribution Non-Commercial License, which permits unrestricted non-commercial use, distribution, and reproduction in any medium, provided the original work is properly cited.

## ABSTRACT

**Background:** Testicular and paratesticular neoplasia are rare type of tumors affecting adolescents and young adults in India, as observed by paucity of published data. This study was undertaken to analyze the patterns of testicular tumors at a tertiary level hospital in Kashmir valley, Jammu and Kashmir, India highlighting the patient's demography, clinical presentation, diagnostic evaluation and pathological finding.

**Methods:** This 5-year (retrospective and prospective) study was performed in the Department of Pathology, Government Medical College Srinagar, Jammu and Kashmir, India from January 2012 to December 2016. For the retrospective study, all cases of testicular tumors, their histopathological reports and required clinical details were searched from records maintained in the Department of Pathology, GMC Srinagar, Jammu and Kashmir, India. For the prospective study, the orchidectomy specimens received in our department were subjected to routine histopathological processing followed by a detailed gross and microscopic examination. Tumour typing and subtyping was done according to WHO classification (2004).

**Results:** A total of 37 cases of testicular and paratesticular neoplasia were included in present study with a mean age of 35.1 years. Out of these 37 cases, 31 (83.78%) were malignant and 6 cases (16.22%) were benign. Right testis was affected in 70.3% of cases. The most common clinical presentation was scrotal swelling. Germ cell tumor was the most common type accounting for 89.2% of tumors followed by lymphomas (8.1%).

**Conclusions:** It is concluded that despite new techniques in imaging and tumor marker assay, the diagnosis of testicular tumors is dependent upon histopathological examination. The present study fairly provides an insight into the clinical presentations, prevalence and patterns of testicular tumors.

**Keywords:** Germ cell tumor, Neoplasia, Seminoma, Testicular tumor

## INTRODUCTION

Tumors are the major pathology affecting testis. Testicular cancer comprises 1% of all the male cancers worldwide.<sup>1</sup> Testicular tumors are most commonly encountered in 15-35 years age group.<sup>2</sup> In western countries incidence of these tumors is on rising trend.<sup>3</sup> However, in India, its incidence is low i.e. 15.92%.<sup>4</sup>

Majority of the testicular tumors arise from germ cells and more than 50% of tumors comprise of more than one histological type of tumor. The exact cause and pathogenesis of these tumors is unknown; however, it is postulated that the disease process begins in fetal life and comprise of abnormal proliferation of primordial germ cells.<sup>5,6</sup> There are various risk factors for development of testicular cancer which include cryptorchidism (testicular

maldescent), carcinoma in situ (intratubular germ cell neoplasia), history of testicular cancer or extragonadal germ cell tumor, family history, HIV infection, Down syndrome, and testicular trauma.<sup>7</sup>

The commonest presentation of testicular tumor is a nodule or painless swelling of one gonad. Other signs and symptoms include undescended testis or cryptorchidism, epididymo-orchitis, hydrocele, dull ache or dragging sensation in the lower abdomen or scrotum, and rarely infertility.<sup>8-11</sup>

Marked advances have been achieved in the treatment of testicular tumors with complete remission possible in the early cases; thus, institution of an early and correct histopathological diagnosis is indispensable.

In 2004, WHO has classified testicular and paratesticular neoplasia into various subgroups and same were incorporated in present study.<sup>12</sup>

The objective of this study was to analyze the patterns of testicular tumors at a tertiary level hospital in Kashmir valley highlighting the patient's demography, clinical presentation, diagnostic evaluation and pathological finding.

**METHODS**

The present (retrospective and prospective) study was conducted in the Department of Pathology in collaboration with the Department of Surgery, Government Medical College, Srinagar, Jammu and Kashmir, India and included all orchidectomies done for testicular tumors received in the department over a period of five years (January 2012 to December 2016). For the retrospective study, all cases of testicular tumors, their histopathological reports and required clinical details were searched from records maintained in the Department of Pathology, GMC Srinagar. All clinically relevant data including patient's age, laterality, history of risk factors and serum tumor markers was collected from the records. For the prospective study, the orchidectomy specimens were received from department of Surgery, GMC Srinagar. Tissue specimen received by our department after proper labeling were subjected to gross and detailed histopathological examination. The specimens were fixed in 10% buffered formalin. After fixation, a comprehensive examination of the gross specimen was done under following headings: laterality, external surface, color and consistency, size of tumor, encapsulation, appearance of cut surface, presence of necrosis, cystic change or hemorrhage, surrounding testicular tissue, epididymis and spermatic cord. Lymph nodes, if any were also studied. The most representative areas of each case were found and 1.5 x 1 cm sized sections were taken from tumor. The tissue was processed as per standard procedure. 3-4 micron thick sections were cut on microtome and stained by

haematoxylin and eosin stain. The tumors were classified according to WHO classification (2004).<sup>12</sup>

**Inclusion criteria**

All patients attending the surgery OPD who presented with testicular swelling and those admitted in the wards with a solid, firm intratesticular mass that can't be transilluminated.

**Exclusion criteria**

Patients in whom swelling was found to be non-neoplastic on clinicopathological examination were excluded from study.

**RESULTS**

A total of 37 cases of clinically recognized testicular masses were evaluated during the study period of 5 years. All these cases were studied clinically and detailed histopathological examination was done. Preoperative assay of relevant tumor markers were also noted from case records.

**Table 1: Mode of presentation of testicular tumors.**

Clinical presentation	No. of cases	Percentage (%)
Scrotal swelling	19	51.35
Scrotal swelling with pain	4	10.81
Scrotal swelling with hydrocele	2	5.40
Pain with dragging sensation	2	5.40
Undescended testis	9	24.32
Family history of testicular neoplasia	1	3.23

Various aspects of clinical presentation were studied. Out of 37 cases studied, 51.35 % of patients presented with scrotal swelling only. Swelling was associated with pain in 4 cases and with hydrocoele in 2 cases. A history of cryptorchidism (undescended testis) was noted in 9 cases and family history of testicular neoplasm in 1 case (Table 1).

**Table 2: Laterality distribution of testicular tumors.**

Laterality	No. of cases	Percentage (%)
Right	26	70.3
Left	11	29.7
Total	37	100

In the present study predominant right side involvement was seen comprising of 26 cases (70.3%). There was no bilateral involvement in present study (Table 2).

Preoperative assay of tumour markers showed elevated  $\alpha$ -fetoprotein and  $\beta$ -human chorionic gonadotrophin levels in 3 (8.10%) and 16 cases (43.24%) respectively.

The present study witnessed a wide range of age distribution ranging from 2 years to 70 years. Maximum number of cases was seen in the age group of 41-50 years followed by 31-40 years with a mean age of 35.1 years.

All cases of mature cystic teratoma were seen in 1<sup>st</sup> and 2<sup>nd</sup> decade, whereas, lymphomas were seen in 60-70 year age group (Table 3).

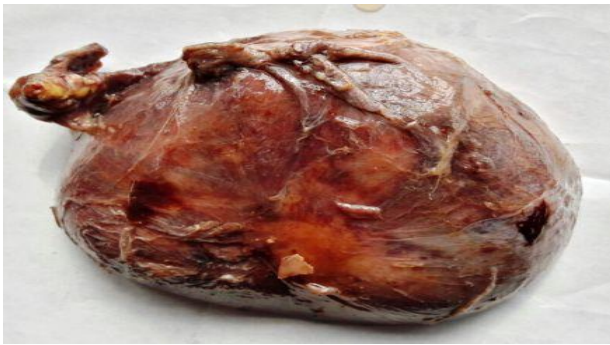**Table 3: Age distribution of testicular tumours.**

Age group (yrs)	Seminoma-classical	Sp. semi	Mixed GCT	YST	Emb. ca	Mat cystera	Imm teratoma	Lymphoma	Sarcoma
0-10	-	-	-	1	-	1	-	-	-
11-20	-	-	-	-	1	5	-	-	-
21-30	2	-	2	-	1	-	1	-	-
31-40	4	-	2	-	-	-	1	-	-
41-50	7	1	1	-	-	-	-	-	1
51-60	2	1	-	-	-	-	-	-	-
61-70	-	-	-	-	-	-	-	3	-
Total	15	2	5	1	2	6	2	3	1

The study work comprised of 37 cases of testicular tumors among which 31 (83.78%) cases were malignant and 6 (16.22%) were benign (Table 4).

**Table 4: Distribution of cases.**

Lesion	No. of cases (%)
Benign	6 (16.22%)
Malignant	31 (83.38%)
Total	37

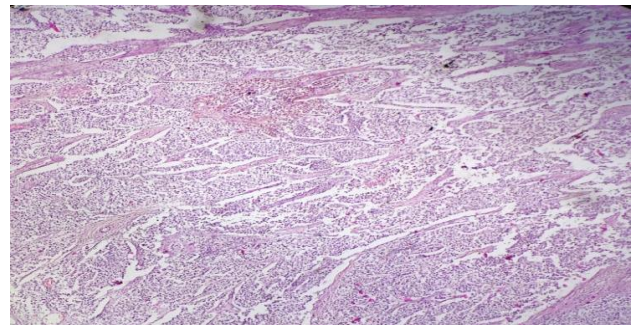


**Figure 1: Gross showing testicular tumour.**

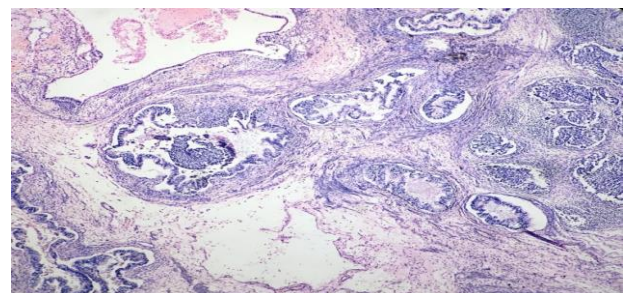


**Figure 2: Cut surface of seminoma.**

Out of total 37 cases, 36 (97.3%) cases were testicular and 1 (2.7%) was a paratesticular neoplasm. On histologic typing of the 37 cases according to the WHO classification, a predominance of Germ cell tumors was seen. Of the 37 cases, 28 (75.7%) were Germ cell tumors of one histological types including 15 cases of Classical Seminoma, 8 cases of Teratoma, 2 cases each of embryonal carcinoma and spermatocytic seminoma and 1 case of yolk sac tumor and 5 (13.51%) were testicular germ cell tumors of mixed histological types. A single case of paratesticular neoplasm was reported as Leiomyosarcoma (Table 5).



**Figure 3: 10X showing Seminoma (H and E stain).**



**Figure 4: Mixed germ cell tumour (Teratocarcinoma; 10X).**



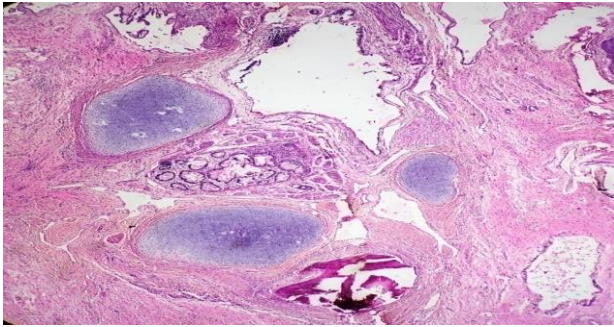


Figure 5: Mature cystic teratoma (10X).

Table 5: Histological typing of testicular and paratesticular tumors.

Histologic type	No. of cases	Percentage (%)
<b>Germ cell tumours</b>	33	89.2
<i>Tumors of one histologic type</i>	28	75.7
Seminoma	15	40.54
Spermatocytic seminoma	2	5.4
Embryonal carcinoma	2	5.4
Yolk sac tumour	1	2.7
Teratoma	6	16.22
-Mature	2	5.4
-Immature	2	5.4
<i>Tumors of more than one histologic type</i>	5	13.51
Seminoma with teratoma	1	2.7
Embryonal carcinoma with teratoma	2	5.4
Yolk sac tumor with embryonal carcinoma	1	2.7
<b>Hematopoietic tumor</b>		
Lymphoma	3	8.1
<b>Mesenchymal tumors of testicular adnexa</b>		
Leiomyosarcoma	1	2.7
<b>Total</b>	<b>37</b>	<b>100</b>

## DISCUSSION

In the present study, 37 patients of testicular and paratesticular tumors were studied. Various parameters relating to clinicopathological aspect were studied thoroughly and findings were compared with the various other renowned authors who studied testicular tumors. In our study, wide age range was observed ranging from 2-70 years with a mean age of 35.1 years age. Our findings were quite similar to the findings of Salako AA et al who found age variation from 4-70 years of age.<sup>13</sup> Peak age incidence was seen in the age group of 41-50 years followed by 31-40 years. Lattin H et al also found the peak prevalence to be in the 3<sup>rd</sup> and 4<sup>th</sup> decade.<sup>14</sup>

Testicular tumors in present study were predominantly right sided (70.3%). Right sided predominance for testicular tumors was observed by various other authors

in their studies as Deotra et al (60%) and Shirish et al (56%).<sup>15,16</sup> There was no bilateral involvement in present study.

Scrotal swelling was the commonest mode of presentation seen in 25 (67.57%) patients. Tan et al found testicular swelling in 100% of cases.<sup>17</sup> In present study undescended testis was seen in 9 cases (24.32%). The incidence of undescended testis in our study was slightly higher as compared to study by Woodward (3.5-14.5%).<sup>18</sup>

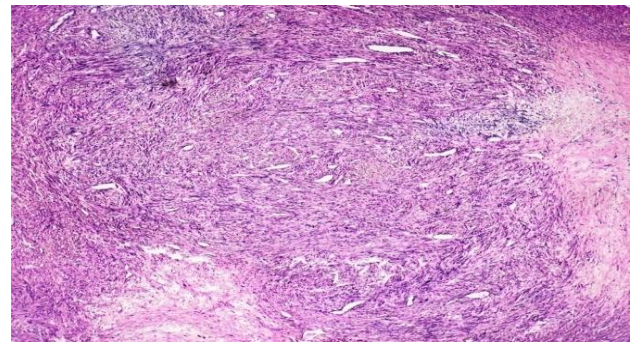


Figure 6: Microscopy showing leiomyosarcoma (10X).

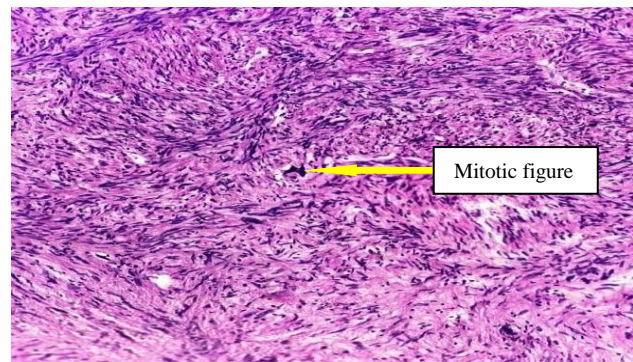


Figure 7: Microscopy showing leiomyosarcoma (40X).

In this study, germ cell tumors were the commonest testicular tumors. Of 33 germ cell tumors, 28 (84.48 %) tumors were of one histological type, and 5 (15.15%) tumors were of more than one histological type comparable to the findings of Naqvi et al and Chandanwale et al.<sup>19,20</sup> Among the tumors of one histologic type, seminoma was the most common neoplasm in the present study constituting about 40.54 % of all tumors. Our finding was comparable with the studies of Moghe et al (41.6%) and Mushtaq et al (44.4%).<sup>21,22</sup>

In present study, most common non-seminomatous germ cell tumor of one histologic type was found to be teratoma which constituted 21.62% of all testicular tumors. Salako et al found 12.5% of teratomas out of 26 cases of testicular and paratesticular tumors studied over 17 years.<sup>13</sup> The most common combination of germ cell tumors in present study was teratocarcinoma (immature teratoma with embryonal carcinoma) accounting for 3/5

cases (60%) followed by 1 case (20%) of yolk sac tumor with embryonal carcinoma and 1 case (20%) of seminoma with teratoma. Our findings were in accordance with previous study in which teratocarcinoma was commonest subtype.<sup>15</sup>

Primary malignant lymphomas of testis are rare and constitute about 5% of all testicular neoplasm.<sup>23</sup> In present study lymphomas were second most common tumour constituting about 8.1% of all testicular tumors with mean age of 66.66 years. These findings were in accordance with the series from Pakistan which showed Non Hodgkin's lymphoma were quite frequent, which was reason for second peak in over 60 year's age group.<sup>22,24</sup>

In present study we also observed 1 case of paratesticular neoplasm in a 50 year old person which on histology was seen to be leiomyosarcoma (Figure 6 and 7). Immunohistochemistry was also done for confirmation. In contrast to our study, rhabdomyosarcomas were most common variety of paratesticular neoplasm in a study from south western Nigeria.<sup>13</sup>

## CONCLUSION

The incidence of testicular neoplasm still remains low in India. Peak age incidence was seen in the age group of 41-50 years followed by 31-40 years. Testicular tumors in our study were predominantly right sided and the commonest presentation was a painless scrotal swelling. Histologically germ cell tumours accounted for highest percentage of cases with a commonest subtype of seminoma followed by mixed germ cell tumour. 6 cases were reported as benign in present study, which highlights that any testicular swelling should be evaluated thoroughly with clinicopathological correlation to rule out malignancy. From this study we conclude that despite new techniques in imaging and tumor marker assay, the diagnosis of testicular tumors is dependent upon histopathological examination.

*Funding: No funding sources*

*Conflict of interest: None declared*

*Ethical approval: The study was approved by the Institutional Ethics Committee*

## REFERENCES

- Purdue MP, Devesa SS, Sigurdson AJ, McGlynn KA. International patterns and trends in testis cancer incidence. *Int J Cancer*. 2005;15:822-7.
- Power DA, Brown RS, Brock CS. Trends in testicular carcinoma in England and wales, 1971-1999. *BJU Int*. 2001;87:361-5.
- Adami HO, Bergström R, Möhner M, Zatoński W, Storm H, Ekblom A, et al. Testicular cancer in nine northern European countries. *Int J Cancer*. 1994;59(1):33-8.
- Yeole BB, Jussawalla DJ. Descriptive epidemiology of the cancers of the male genital organs in Greater Bombay. *Indian J Cancer*. 1997;31:30-9.
- Bray F, Richiardi L, Ekblom A, Pukkala E, Cuninkova M, Moller H. Trends in testicular cancer incidence and mortality in 22 European countries: continuing increase in incidence and declines in mortality. *Int J Cancer*. 2006;118(12):3099-111.
- McGlynn KA, Devesa SS, Graubard BI, Castle PE. Increasing incidence of testicular germ cell tumours among black men in the United States. *J Clin Oncol*. 2005;23:575-61.
- Garner MJ, Turner MC, Ghadirian P, Krewski D. Epidemiology of testicular cancer: an overview. *Int J Cancer*. 2005;116(3):331-9.
- Sabiston DC. *Sabiston Textbook of Surgery: The Biological Basis of Modern Surgical Practice*, 18th ed. Philadelphia: Elsevier Saunders, 2007;2:2280-2285.
- Wein AJ. Neoplasm of testis. In: *Cambell-Walsh Urology*, 9th ed. Philadelphia: Elsevier Saunders; 2007:893-958.
- Tanagho EA, McAninch JW, Eds. Genital tumours. In: *Smith's General Urology*, 17th ed. Newyork: Tata McGraw-Hill Education; 2007:375-387.
- Bailey, Love. *Tumours of Testis*, 25th ed. London: Taylor and Francis Ltd; 1997:1384-1387.
- Eble JN, Sauter G, Epstein JI. *Pathology and genetics of tumours of the urinary system and male genital organs*. IARC Press, Lyon; 2004.
- Salako AA. Testicular and para-testicular tumours in south western Nigeria. *Afr Health Sci*. 2010;10(1):14-7.
- Hayes-Lattin B, Nichols CR. Testicular cancer: a prototypic tumor of young adults. In: *Seminars in oncology*. WB Saunders. 2009;36(5):432-8.
- Deotra A, Mathur DR, Vyas MC. A 18 years study of testicular tumours in Jodhpur, western Rajasthan. *J Postgrad Med*. 1994;40:68-70.
- Collins DH, Pugh RCB. Classification and frequency of testicular cancer. *Br J Urol*. 1964;36(1):1-11.
- Tan GH, Arzif M, Shamsul AS, Ho CC, Praveen S, Goh EH, et al. Clinicopathological features and survival of testicular tumours in a Southeast Asian university hospital: a ten-year review. *Asian Pac J Cancer Prev*. 2011;12(10):2727-30.
- Woodward PJ. Case 70: seminoma in an undescended testis. *Radiology*. 2004;231:388-92.
- Naqvi SQH, Ansari AL, Memon NA, Memon JM, Akhund AA. Correlation of age with histopathological type of testicular tumors. *Gomal J Med Sci*. 2006;4(1):24-7.
- Chandanwale S, Chawla R, Buch A, Dharwadkar A, Gore C, Rajpal M. Pathology of testicular tumors-review of 50 cases. *Int J Pharm Biomed Sci*. 2012;3(4):167-76.
- Moghe KV, Agrawal RV, Junnerkar RV. Testicular tumors. *Indian J Cancer*; 1970:90-7.

22. Mushtaq S, Jamal S, Mamoon N, Akbar N, Khadim T. The pathological spectrum of malignant testicular tumours in northern Pakistan. *J Pak Med Assoc.* 2007;57(10):499-500.
23. Sussman EB, Hajdu SI, Lieberman PH. Malignant lymphoma of testis: a clinicopathologic study of 37 cases. *J Urol.* 1977;118:1004-7.
24. Jamal S, Moghal S, Mamoon N, Mushtaq S, Luqman M, Anwar M. The pattern of malignant tumours: Tumour registry data analysis, AFIP,

Rawalpindi, Pakistan (1992-2001). *J Pak Med Assoc.* 2006;56:359-62.

**Cite this article as:** Beigh A, Junaid S, Beg A, Farooq S, Wani LA, Manzoor F. Clinicopathological study of testicular tumors: an experience in a tertiary care hospital in Kashmir valley, Jammu and Kashmir, India. *Int J Res Med Sci* 2017;5:2741-6.