

## Original Research Article

# A light microscopic study of placentae in eclamptic mothers at term

Rudradev Meyur<sup>1</sup>, Anirban Sadhu<sup>1\*</sup>, Hironmoy Mondal<sup>2</sup>, Santanu Kumar Khanra<sup>1</sup>

<sup>1</sup>Department of Anatomy, R G Kar Medical College, 1 Khudiram Bose Sarani, Kolkata-700004, West Bengal, India

<sup>2</sup>Department of Anatomy, North Bengal Medical College, P.O. Sushruta Nagar, Siliguri, Darjeeling-734012, West Bengal, India

**Received:** 24 June 2017

**Accepted:** 22 July 2017

### \*Correspondence:

Dr. Anirban Sadhu,

E-mail: anir\_sd@rediffmail.com

**Copyright:** © the author(s), publisher and licensee Medip Academy. This is an open-access article distributed under the terms of the Creative Commons Attribution Non-Commercial License, which permits unrestricted non-commercial use, distribution, and reproduction in any medium, provided the original work is properly cited.

## ABSTRACT

**Background:** Eclampsia is one of the leading causes of maternal and consequent foetal mortality in India. Studies on the histology of eclampsia are relatively uncommon, more so in the eastern region of India. The present study therefore is an attempt to analyse the changes which occur in placentae of eclamptic mothers with the help of light microscope as it is considered to be the epicentre of the disease. These findings are useful to understand the pathology of the killer disease and improve morbidity and mortality.

**Methods:** 60 cases were selected for the study. 30 were non-eclamptic and 30 were eclamptic. Abnormalities in blood vessels, villi and basement membrane of placentae were searched for after routine H and E staining.

**Results:** Eclamptic cases recorded with higher incidences of fibrinoid necrosis of villi, cytotrophoblastic proliferation, increased syncytial knots, hypo vascular villi and thickening of basement membrane. Non-eclamptic cases recorded only fibrinoid necrosis. Other features were not observed in the latter cases.

**Conclusions:** Light microscopic changes observed in eclamptic placentae may contribute to the pathogenesis of the condition and serve as the baseline for further studies.

**Keywords:** Eclampsia, Fibrinoid necrosis, Villi

## INTRODUCTION

Eclampsia is defined as the development of convulsions and/or unexplained coma during pregnancy or postpartum in patients with signs and symptoms of preeclampsia. The diagnosis of eclampsia is confirmed in the presence of generalized oedema, hypertension, proteinuria, and convulsions.<sup>1</sup> Almost all cases (91%) of eclampsia develop at or beyond 28 weeks.<sup>2</sup> It is a serious complication of hypertensive disorder in pregnancy and is a leading contributor of maternal death.<sup>3,4</sup>

Simply stated eclampsia means preeclampsia with superimposed seizures. In eclampsia, the typical clinical picture is of generalized tonic-clonic seizures during third

trimester, during labour, or puerperium in women who already have hypertension, proteinuria, and oedema. Criteria for the diagnosis of preeclampsia is systolic blood pressure  $\geq 140$  mmHg or diastolic blood pressure  $\geq 90$  mmHg and proteinuria of 0.3 g or greater in a 24-hour urine specimen. When convulsions also occur, the condition is referred to as eclampsia.<sup>5,6</sup> The aetiology and the only known cure for this condition involve the placenta which is essentially an allograft.<sup>7</sup> Placenta is therefore considered the organ which is involved in the pathogenesis of eclampsia and its removal usually ameliorates the condition.

The incidence of eclampsia in India has been quoted as 1.56%.<sup>8</sup> According to the WHO, eclampsia is responsible

for 12% of all maternal death globally.<sup>9</sup> In India, reported incidence of eclampsia varies from 0.179 to 3.7% and maternal mortality varies from 2.2 to 23% of all eclamptic women.<sup>10-14</sup> The estimated incidence of eclampsia in Western countries is 1 in 2000-3448 deliveries.<sup>15</sup> These data unequivocally point to the graveness and importance of this potentially curable disease. This study was therefore done to investigate the pathological changes of placenta under light microscope which might give an insight into the measures required for managing this condition.

## METHODS

A comparative study for a period of one year was done with 60 cases from the Department of Obstetrics and Gynaecology of a medical college in Kolkata, West Bangal, India. All were primigravida. Of these 30 were non-eclamptic (controls) and 30 were eclamptic. Eclampsia was confirmed by hypertension, proteinuria and generalized oedema along with at least one episode of generalized tonic clonic convulsion (seizure) after 20 weeks of gestation. Institutional ethics clearance and consent of patients were obtained prior to commencement of the study. All were booked cases (with minimum three antenatal visits) who had attended the emergency room with a history of seizure.

Investigations such as blood grouping and Rh typing, blood haemoglobin percentage, fasting blood sugar, blood tests for HIV and VDRL and urine for routine and microbiological examination were done for all cases. Cases with anaemia and diabetes mellitus were excluded from the study. Personal information such as name, age and address were obtained. The height, weight, pulse, blood pressure was recorded. Systemic and obstetrical examinations were also done. All were delivered vaginally without major complications. Mother and baby were discharged eventually.

The placentae of all cases were collected intact with the cord, cleared of blood with water and preserved in buffered isotonic solution of 4% formaldehyde for 24 hours. Slices from three areas of each placenta were prepared-one each from central, peripheral and intermediate areas which included its entire thickness. Sections were then prepared from the central zone of each slice. Sections were also made from areas appearing to be abnormal on gross examination.

All the sections were carefully examined for presence of calcification, infarcts, intervillous thrombosis and cysts. Sections were treated successively with a graded series of mixtures of ethanol and water (usually from 70% to 100%) to extract the water. The ethanol was then replaced by xylene as it is a solvent miscible with the embedding medium. The tissues were then impregnated with melting paraffin in a hot air oven, typically at 58-60°C. The hard blocks of tissues so obtained were sectioned to a thickness of 5µm using a rotary microtome.

The latter sections were floated on water and transferred to glass slides to be stained with Hematoxylin and Eosin according to the method proposed by Bancroft and Stevens, 1982. The stained slides were examined under the light microscope. 100 terminal villi were counted in the maternal subdivision of each section from 8 random fields. The following criteria were selected to identify certain pathologic features reported to be common in eclamptic placentae by previous investigators (Table 1).

**Table 1: Histopathological features studied along with criteria.**

Histopathological feature studied	Criteria considered to be significant
Cytotrophoblastic proliferation	>20% villi in one field
Fibrinoid necrosis	>5% villi in one field
Hypo vascular villi	As evidenced by hyalinization
Syncytial knots	>30% villi in one field
Thickening of basement membrane	>3% villi in one field

## RESULTS

Eclamptic cases recorded all the abnormalities considered for the study. Among the features studied cytotrophoblastic proliferation had the lowest incidence of 3.33%. Cytotrophoblastic proliferation is detected beneath the syncytiotrophoblast. It lies external to the basement membrane. The nuclei stain lightly and are present in a single row.

Fibrinoid necrosis recorded the highest incidence of 76.67%. Fibrinoid refers to any non-cellular, eosinophilic, homogeneous material that can be identified in the placenta. Intravillous fibrinoid is described as a distinct fibrinoid material appearing in the sub trophoblastic space that finally occupies the whole villous stroma. Fibrinoid necrosis is also observed in the tunica intima and media of spiral arteries of placentae because of increased blood pressure.

Hypo vascular villi and thickening of basement membrane both recorded an incidence of 13.33% each. Hypo vascular villi were identified by total loss of villous capillaries and hyaline fibrosis of the villous stroma in terminal villi. Basement membrane thickening was observed between the trophoblast and the mesenchymal core.

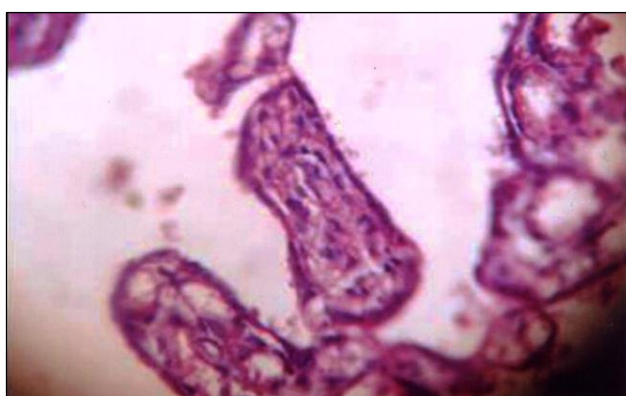Syncytial knots had the next highest incidence with 6.67%. These were present as focal aggregates of syncytial nuclei in almost all terminal villi and are evident by their protrusion from villous surface. The nuclei within true syncytial knots possess highly condensed chromatin. It may either be dispersed throughout the nucleus or in the form of a dense peripheral ring. The nuclei are often closely juxtaposed,

with smooth outlines and little intervening cytoplasm. Non-eclamptic cases presented with only one type of

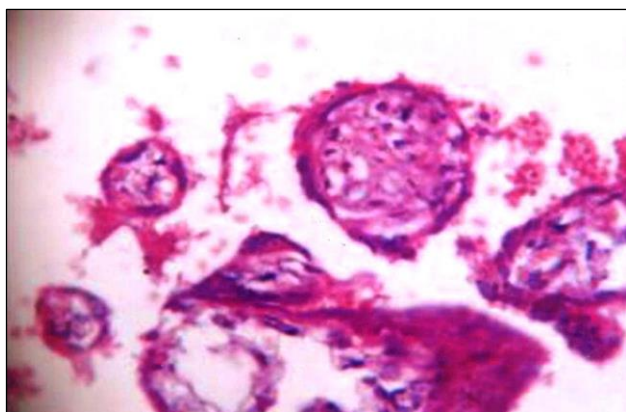
abnormality: two cases (6.67%) presented with fibrinoid necrosis of villi. The results are displayed in Table 2.

**Table 2: Incidence of histopathologic features in non-eclamptic and eclamptic cases.**

Histopathological feature	Incidence in non-eclamptic cases (%) n=30	Incidence in eclamptic cases (%) n=30
Cytotrophoblastic proliferation	0	1 (3.33)
Fibrinoid necrosis	2 (6.67)	23 (76.67)
Hypo vascular villi	0	4 (13.33)
Syncytial knots	0	2 (6.67)
Thickening of basement membrane	0	4 (13.33)



**Figure 1: Cytotrophoblastic proliferation.**



**Figure 2: Thickening of villous trophoblast membrane (above) and fibrinoid necrosis (lower right).**

## DISCUSSION

### *Cytotrophoblastic proliferation*

Proliferation and subsequent increase of villous cytotrophoblast serve as an indicator of severity and duration of ischaemia to the placenta. The present study observed it in a single (3.33%) case. No controls were observed to display this feature. Singh et al observed that

the number of placentae with this condition increased with the severity of hypertension.<sup>15</sup> Jones and Fox observed this in 69% of villi.<sup>16</sup> Narasimha A et al, observed villous cytotrophoblast proliferation in all 9 (100%) cases. The latter reported their findings in >40% villi.<sup>17</sup> The study by Navbir P et al, was no exception and also recorded similar results with all 6 (100%) cases displaying this pathology in >20% villi.<sup>18</sup> The latter study also observed a higher incidence of adverse foetal outcome in eclamptic mothers when compared to normal cases.

The proliferation of villous cytotrophoblastic cells as a reaction to toxemia of pregnancy have been reported by Wigglesworth and Kalra et al in their respective studies.<sup>19,20</sup> The noticeable differences between the incidences of the present and other studies may be due to some distinct traits of the population. This could have led to a lower incidence inspite of greater number of cases.

### *Fibrinoid necrosis*

It is a mass of structure less, homogenous, acidophilic material around the periphery of which are a few degenerate syncytial nuclei.<sup>21</sup> Fibrinoid necrosis of more than 3% villi was observed in all 9 (100%) cases of eclampsia by Narasimha A et al, whereas the same was found in 11 (29.72%) controls.<sup>17</sup> Rest of the controls had fibrinoid necrosis in less than 3% of villi. Similarly, Navbir P et al, observed fibrinoid necrosis of more than 3% villi in all 6 (100%) cases of eclampsia.

However, the control group had 22 (73.33%) mothers with same findings- a sharp rise when compared to that of Narasimha A et al. Only 8 (26.67%) controls had fibrinoid necrosis in less than 3% of villi.<sup>18</sup> The present study observed it in 23 (76.67%) cases of eclampsia and 2 (6.67%) of controls. This is consistent with previous authors and may point to a mechanism which is common to most cases of eclampsia. Burstein et al, have found that fibrinoid necrosis is a form of senile amyloid. It is due to immune attachment on trophoblastic cells and contains mis- specified proteins because of ageing process.<sup>22</sup>

### **Hypovascular villi**

Narasimha A et al, observed decreased and normal villous vascularity in 7 (77.77%) and 2 (22.22%) cases of eclampsia respectively.<sup>17</sup> Kalra et al, also reported similar findings.<sup>20</sup> In the present study decreased villous vascularity was observed in 4 (13.33%) out of 30 cases whereas no such finding was present in controls. The differences may be attributed to the varying degrees of vascularity affecting the different study groups. The mechanism involved in producing hypo vascular villi is not fully understood. Dhabhai P et al, who considered hyalinization of villi as hypo vascularity reported statistically significant count of hyalinised villi in cases of toxemia.<sup>21</sup> Teasdale and Udainia et al, considered fibrinoid necrosis, endothelial proliferation of arteries and hyalinization to be mosaicism of placenta.<sup>23,24</sup> The latter is the end- result of hypertension. Zacutti suggested that the mosaicism of the placenta probably lead to a vicious cycle of placental insufficiency and ultimately to foetal growth retardation.<sup>25</sup>

### **Syncytial knots**

These are foetal clumps of syncytial nuclei protruding from the outer surface of villous trophoblasts<sup>21</sup>. Syncytial knots were observed with increased frequency in eclampsia by Narasimha A et al.<sup>17</sup> Whereas these were observed with a frequency of up to 50% in controls (37 cases) the same ranged from more than 50% to more than 90% in eclampsia (9 cases).

Navbir P et al observed syncytial knots count of less than or equal to 30% and more than 30% in 28 (93.33%) and 2 (6.67%) mothers respectively belonging to the control group. Among eclamptic mothers all 6 (100%) cases had syncytial knots count of more than 30%. Out of the 66.67% (20/30) cases of hypertensive pregnancies with excess syncytial knot counts, 3 cases (18.75%) had infants with neonatal asphyxia and 5 cases (35%) had low birth weight babies.<sup>18</sup> Fox failed to demonstrate any relationship between variations in the incidence of syncytial knot formation and foetal parameters like foetal distress, birth weight and neonatal asphyxia.<sup>26</sup>

In the present study increased syncytial knots count was observed in 2 (6.677%) cases whereas none were observed in the control group. Syncytial knots increase in frequency in last weeks of pregnancy and are more common in toxemia.<sup>27-29</sup> It is due to decreased villous perfusion, in post maturity or placental insufficiency.<sup>19,20,30</sup> Bhatia et al, Mathews et al, Masodkar et al and Mehrotra et al have reported similar findings.<sup>31-34</sup>

### **Thickening of basement membrane**

Basement membrane thickening was observed in all 9 (100%) cases by Narasimha A et al.<sup>17</sup> No placentae from the control group showed undue basement membrane

thickening in the latter study. Navbir P et al, received similar results with all 6 (100%) cases exhibiting this feature.<sup>18</sup> However, none from the control group featured basement membrane thickening. The present study recorded 4 (13.33%) cases with this abnormality and none among the controls. This is in accordance with that of Narasimha et al as far as the control groups are considered. The difference in the findings among the cases may be due to sample size between the three studies. Placentae from eclamptic mothers commonly display this feature and an incidence of more than 3% is considered abnormal.<sup>17</sup> These findings concurred with those of other authors.<sup>33,35</sup>

Hyperplasia of cells of the cytotrophoblast leads to excessive secretion of basement membrane proteins which subsequently causes thickening of the membrane. The normal width of villous sub trophoblastic basement membrane is 1000-3000 angstrom.<sup>36</sup> Increase is commonly seen in toxemic placentae. Although considered to be a consequence of utero- placental ischaemia this change is non-specific as it is also seen in other conditions without reduced maternal blood flow through the placenta.<sup>37</sup> Regarding foetal outcome investigators like Fox and Mirchandani et al, have noted similar association of poor foetal outcome with thickening of basement membrane.<sup>29,38</sup>

*Funding: No funding sources*

*Conflict of interest: None declared*

*Ethical approval: The study was approved by the Institutional Ethics Committee*

### **REFERENCES**

1. Sibai BM. Diagnosis, prevention, and management of eclampsia. *Obstet Gynecol.* 2005;105(2):402-10.
2. Mattar F, Sibai BM. Eclampsia. VIII. Risk factors for maternal morbidity. *Am J Obstet Gynecol.* 2000;182:307-12.
3. Obed SA, Wilson JB, Sakay A. Determinants of maternal mortality in eclampsia at Karle Bu teaching Hospital in Accra, Ghana. *Ghana Med J.* 1999;33:88-9.
4. Ogunbode O. Clinical aspects of eclampsia at Ibadan, Nigeria. *Nigeria Med J.* 1997;7:162-6.
5. Emedicine.mescope.com. Campbell DE, editor. Preeclampsia (Last updated on 2009 January 06) Available at <http://www.emedicine.medscope.com/article/953579-overview>. (Last cited on 2009 June 18).
6. Subramaniam, V. Seasonal variation in the incidence of preeclampsia and eclampsia in tropical climatic conditions. *BMC Women's Health.* 2007;7:1-18.
7. Akhlaq M, Nagi AH, Yousaf AW. Placental morphology in pre-eclampsia and eclampsia and the likely role of NK cell. *Indian J Pathol Microbiol.* 2012;55:17-21.



8. Nobis PN, Hajong A. Eclampsia in India Through the Decades. *J Obstet Gynecol India.* 2016;66(S1):S172-6.
9. WHO Reduction of maternal mortality. A joint WHO/UNEP/ UNICEF/World Bank Statement, Geneva, 1999. Available at [http://apps.who.int/iris/bitstream/10665/42191/1/9241561955\\_eng.pdf](http://apps.who.int/iris/bitstream/10665/42191/1/9241561955_eng.pdf).
10. Vanawalla NY, Ghamande S, Ingle KM. A five year Analysis of Eclampsia. *J Obstet Gynecol India.* 1989;39:513-5.
11. Suman G, Somegowda S. Maternal and perinatal outcome in Eclampsia in a District Hospital. *J ObstetGynecol India.* 2007;57:324.
12. Sing K, Medhi R, Bhattacharjee AK, et al. Book of Abstract, 53rd AICOG, Guwahati 2010;17.
13. Chandriole N, Singh S, Dhillon BS. Eclampsia, care hood and management practices at tertiary hospital in India (ICMR), New Delhi. Book of Abstract AICOG, Guwahati; 2010;33.
14. Pal A, Bhattacharjee R, Bannerjee C. Maternal mortality over a decade in a referral medical college hospital, West Bengal. *Indian J Perinatol Reprod Biol.* 2001;04:10-3.
15. Singh S, Gugapriya TS. Microanatomical analysis of hypertensive placentae- a retrospective case control study. *Nat Jour Clinical Anatomy.* 2013;2(1):5-10.
16. Jones CJP, Fox H. An ultrastructural and ultra-histochemical study of human placenta in maternal preeclampsia. *Placenta.* 1980;1:61-76.
17. Narasimha A, Vasudeva DS. Spectrum of changes in placenta in toxemia of pregnancy. *Ind J Pathol Microbiol.* 2011;54(1):15-20.
18. Navbir P, Alka N, Antima G. Histological changes in placentae in pregnancies complicated by pre-eclampsia and eclampsia and corelation with foetal outcome. *Int J Pharm Bio Sci.* 2012;3(2):551-60.
19. Wigglesworth JS, The Langhans layer in late pregnancy. A histological study of normal and abnormal cases. *J Obstet Gynaec Brit C'wealth.* 1962;69:355.
20. Kalra VB, Aggarwal A, Sareen PM. Histopathological changes in placenta in toxemia of pregnancy. *J Obstet Gynaecol India.* 1985;35:86.
21. Dhabhai P, Gupta G, Bapna N. Histological study of human placenta in normal and pregnancy induced hypertension (PIH) cases. *Int J Pharmaceut Sci Invention.* 2013;2(1):30-5.
22. Burstein R, Frankel S, Soule SD, Blumenthal HT. Aging of the placenta: Autoimmune theory of senescence. *Am J Obstet Gynaecol.* 1973;116:271.
23. Teasdale F. Gestational changes in functional structure of the human placenta in relation to foetal growth. *Am J Obst.* 1980;137:560-2.
24. Udainia A, Bhagwat SS, Mehta CD. Relation between placental surface area, infarction and foetal distress in pregnancy induced hypertension with its clinical relevance. *J Anat Soc Ind.* 2004;53;1:27-30.
25. Zacutti A, Borruto F, Bottacci G, Giannoni ML, Manzin A, Pallini M, et al. Umbilical blood flow and placental pathology. *Clin Exp Obst Gynaecol.* 1992;19:63-9.
26. Fox H. The significance of villous syncytial knots in the human placenta. *J Obstet Gynaec Brit C' Wealth.* 1965;72:347.
27. Mallik GB, Mirchandani JJ, Chitra S. Placenta in intrauterine growth retardation. *J Obstet Gynaecol India.* 1979;29:805-10.
28. Mirchandani JJ, Mallik GB, Chitra S. Correlation of foetal outcome with some pathological changes of placenta. *J Obstet Gynaecol India.* 1979;29:1131-9.
29. Mirchandani JJ, Mallik GB, Chitra S. Villous fibrinoid necrosis and basement membrane thickening in toxemia of pregnancy and in intrauterine growth retardation. *J Obstet Gynaecol India.* 1979;29:407-11.
30. Benirschke K, Kaufmann P. Pathology of the human placenta. 2<sup>nd</sup> ed. New York: Springer Verlag; 1990.
31. Bhatia A, Sharma SD, Jalnawalla SF, A comparative study of placental pathology and fetal outcome. *Indian J Pathol Microbiol.* 1981; 24:277.
32. Mathews R, Aikat M, Aikat BK. Morphological studies of placenta in abnormal pregnancies. *Indian J Pathol Microbiol.* 1973;16:15.
33. Masodkar AR, Kalamkar LR, Patki PS. Histopathology of placenta and its correlation with foetal outcome. *J Obstet Gynaecol India.* 1985; 35:294.
34. Mehrotra VG, Mukherjee K, Pande M, Gurtu M. The histological study of placenta in normal and abnormal pregnancy. *J Obstet Gynaecol India.* 1972;22:248.
35. Sodhi S, Mohan H, Jaiswal TS, Mohan PS, Rathee S. Placental pathology in pre-eclampsia eclampsia syndrome. *Indian J Pathol Microbiol.* 1990;33:11-6.
36. Salgado SS, Salgado MKR. Structural changes in pre-eclamptic and eclamptic placentas-an ultrastructural study. *J Coll Physicians Surg Pak.* 2011;2(8)482-6.
37. Burstein R, Berns AW, Hirata Y, Blumenthal HT. A comparative histo and immunopathological study of the placenta in diabetes mellitus and in erythroblastosis fetal. *Am J Obstet Gynaecol.* 1963;86:66-72.
38. Fox H, Basement membrane changes in the villi of human placenta. *J Obstet Gynaecol Brit C'wealth.* 1968;75:302.

**Cite this article as:** Meyur R, Sadhu A, Mondal H, Khanra SK. A light microscopic study of placentae in eclamptic mothers at term. *Int J Res Med Sci* 2017;5:4082-6.