

Original Research Article

A comparative study of conjunctival autograft with fibrin glue or glueless sutureless conjunctival autograft after pterygium surgery

Kalpna Jain*, J. M. Manohar

Department of Ophthalmology, S. P. Medical College and P. B. M. Hospital, Bikaner, Rajasthan, India

Received: 02 November 2017

Accepted: 30 November 2017

***Correspondence:**

Dr. Kalpna Jain,

E-mail: kalpnadaga@gmail.com

Copyright: © the author(s), publisher and licensee Medip Academy. This is an open-access article distributed under the terms of the Creative Commons Attribution Non-Commercial License, which permits unrestricted non-commercial use, distribution, and reproduction in any medium, provided the original work is properly cited.

ABSTRACT

Background: Conjunctival autografting after Pterygium excision can be done by fibrin glue or sutures but use of foreign material can cause discomfort and infection. Fibrin glue may cause hypersensitivity reaction and also have risk of viral transmission. To avoid these conjunctival autograft can be applied without suture or glue. Patient's own blood act as a bioadhesive.

Methods: We done a prospective randomized control study of 70 patients, 35 patients allocated in each group. Group A had conjunctival autograft with fibrin glue while group B had conjunctival autografting without glue or sutures.

Results: In group A 31 and group B 26 patients had well placed conjunctival autograft while 4 in group A and 9 patients in group B had either displaced or dislodged graft. The results were statistically insignificant with P value of 0.219 and No complication was reported in any patient except recurrence. The 5 patients in group A and 6 in group B had recurrence which is not statistically significant.

Conclusions: Graft stability is more with fibrin glue as compare to glueless and sutureless conjunctival autografting but using patients own blood as bioadhesive is safer and cost effective. The rate of recurrence is similar in both the groups.

Keywords: Conjunctival autograft, Fibrin glue, Glueless, Pterygium

INTRODUCTION

Pterygium is a triangular wing shape proliferation of conjunctiva on the cornea in interpalpebral area. The subconjunctival tissue proliferates as vascularised granulation tissue to invade and destroy superficial layers of cornea including bowman's membrane and stroma. Mostly the condition is asymptomatic and only causes cosmetic disfigurement but sometimes it may cause variety of symptoms. Etiology is multifactorial with features indicative of both degenerative process and disordered growth. The epidemiological studies have reported strong correlation between pterygium and ultraviolet (UV) radiations, hot, dry, sunny and sandy

climates. The prevalence rate varies widely (2% to 29%) but generally higher in the tropics than temperate countries.¹⁻³ There are association with rural regions, increasing age and male gender, which correlate with outdoor work.⁴ Measures such as wearing sunglasses or prescription glasses have been described as protective factors against pterygium development.^{3,5-7} Treatment is surgical excision. The bare sclera and primary closure technique both have unacceptable recurrence. There are various methods to prevent its recurrence following surgical excision. These are conjunctival autografting, amniotic membrane grafting, use of mitomycin-c or 5-fluorouracil as adjuvant, Anti VEGF agents or beta radiations. In conjunctival autografting, the pterygium is

excised and remaining defect is covered by patient's own conjunctiva by using fibrin glue, sutures or may left sutureless and glueless.

METHODS

We had done a prospective randomized controlled study of 70 patients who undergone pterygium excision followed by conjunctival autografting with help of fibrin glue or without glue or sutures. The patients were randomly allocated in two groups. Each group having 35 patients. Group A had undergone pterygium excision followed by conjunctival autografting with the help of fibrin glue and group B underwent pterygium excision followed by glueless, sutureless conjunctival autografting. All patient had primary pterygium and informed consent of patients had taken. The exclusion criteria were recurrent pterygium or other associated ocular disease. Most of the patient comes due to ocular discomfort, watering, redness, irritation and cosmetic disfigurement.

A complete ophthalmic examination including visual acuity, slit lamp examination, keratometry, Intraocular pressure measurement, ocular movements and grading of pterygium was done. All patients were treated on outpatient basis and after preoperative evaluation antibiotic drops were prescribed. Group A patients undergone pterygium excision followed by conjunctival autografting with help of fibrin glue. The conjunctival autograft was taken from superotemporal bulbar conjunctiva of same eye near limbus. Fibrin glue tissue adhesive was applied on bare sclera after natural hemostasis. Conjunctival autograft was then slid on it.

The limbal side of graft corresponds to limbus of bare sclera and maintain correct orientation with epithelial side up and stromal side down. The fibrin glue was allowed to act for 5minutes. Graft adherence and positioning was examined at the end of the surgery. In group B patients the excision of pterygium was done, and conjunctival autograft of appropriate size was applied over bare sclera without glue or sutures. The graft applied with proper orientation after hemostasis. Graft adherence and position was examined at and of surgery. The follow ups of patients were done at first postoperative day, first week, first month, 3month, 6month and one year.

RESULTS

The maximum numbers of patients were in age group between 31-40years (Table 1).

Table 1: Age distribution.

Age (years)	No. of patients	Percentage (%)
20-30	8	11.43
31-40	34	48.57
41-50	26	37.14
51-60	2	2.86

The common preoperative complaints were ocular discomfort, irritation, watering, redness and cosmetic disfigurement. At first postoperative day patients had redness, pain, discomfort and watering but in subsequent follow up these resolved. These are almost equal in both groups but at one-year group B, is more symptoms free (Table 2).

Table 2: Post-operative complaints.

Groups	Post-operative complaints	No. of patients					
		1 day	1 week	1 month	3 months	6 months	1 year
Group A	Pain	10	1	0	0	0	0
	Redness	33	15	0	0	1	1
	Discomfort	4	5	2	2	1	1
	Watering	4	7	2	1	2	2
Group B	Pain	9	2	0	0	0	0
	Redness	35	17	2	1	1	1
	Discomfort	8	4	2	0	0	0
	Watering	3	1	0	0	1	1

In group A, 31 patients had well placed conjunctival autograft (Figure 1) while 4 patients had either displaced or dislodged graft (Figure 2). In group B, 26 patients had well placed graft (Figure 3) and 9 patients had either displaced or dislodged graft in all visits of follow up. The results were statistically insignificant with p value of 0.219 and no complication was reported in any patient except recurrence (Figure 4). The recurrence in group A,

occurs in 5 patients while group B had recurrence in 6 patients (Table 3). The results were statistically insignificant with p value of 0.956. In these only one patient in each group has well placed graft rest had displaced or dislodged graft.

Conjunctival autograft with fibrin glue had better graft stability than sutureless and glueless conjunctival

autografting but statistically insignificant. Recurrence rate is similar in both group and more in case of displaced or dislodged graft. Glueless conjunctival autograft is more cost effective but poor graft stability.

Table 3: Graft position and recurrence.

Groups	Well placed graft	Displaced graft	Recurrence
Group A	31	4	5
Group B	26	9	6

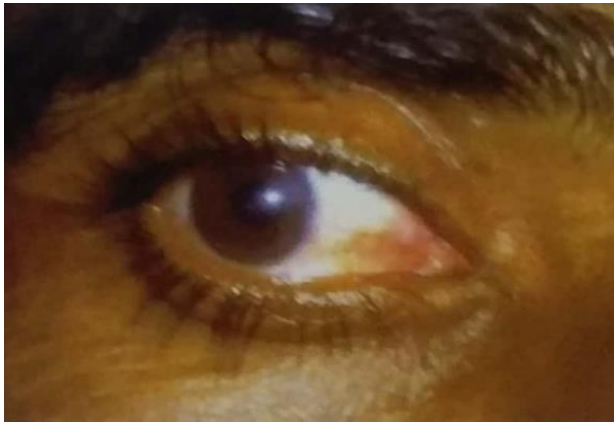

Figure 1: Conjunctival autograft with fibrin glue at 1 year post-operative showing no recurrence.

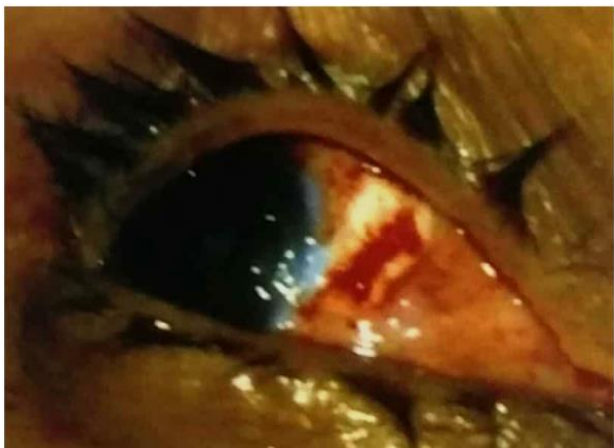

Figure 2: Conjunctival autograft with fibrin glue at 1st day post-operative showing dislodged graft.

DISCUSSION

The pterygium is elastotic degeneration of conjunctiva in which wing like fibrovascular tissue extending from conjunctiva to cornea. It is usually present in inter palpebral area. It has three parts cap, head, body or tail. The stocker’s line of iron deposition may have found on leading edge where tear flow is abnormal, it indicates chronicity and stable position. The cap of leading edge is flat gray zone on cornea which invade and destroy bowman’s layer. This zone consists mainly fibroblasts.

Thick, vascular firmly attached tissue behind the cap is known as head.

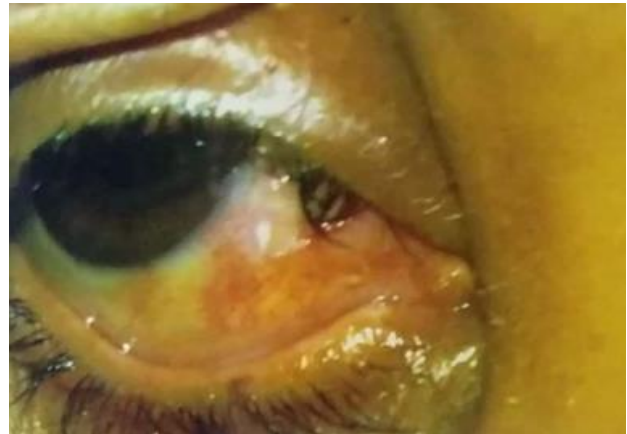


Figure 3: Glueless, sutureless conjunctival autograft at 1 week post-operative showing well placed graft.

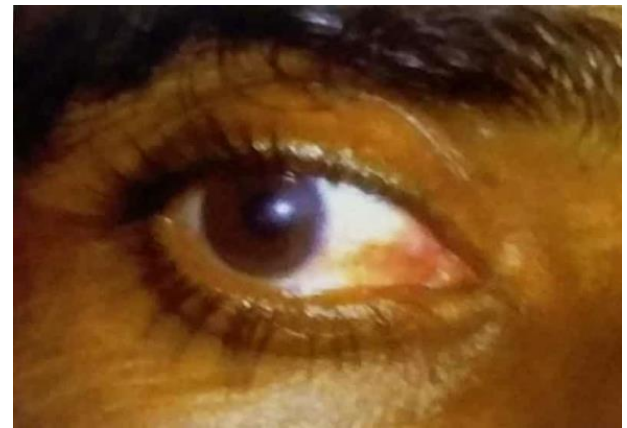

Figure 4: Glueless, sutureless conjunctival autograft at 6 months showing recurrence.

The fleshy, mobile vascular bulbar conjunctiva behind the head is known as body or tail. Patient is usually asymptomatic except cosmetic disfigurement but may present with redness, irritation, foreign body sensations, watering, dryness, itching and decrease vision due to astigmatism or involvement of pupillary area. Large lesion may cause diplopia, mostly in lateral zone due to tethering effect. This is more common in recurrent pterygium with scar tissue formation. Pterygium may be primary or recurrent following regrowth after excision. It has two stages. In progressive stage, it is thick and vascular and continue to grow on cornea. In atrophic stage, it is thin, pale and ceases to grow. Etiology of pterygium is uncertain. The features indicative of both degenerative process and disordered growth. Histopathologically the pterygium is elastotic degeneration of conjunctiva.⁸ Pterygium also shows tumour like features. These are tendency to invade normal tissue, high recurrence rate following resection, ultraviolet radiation exposure as an etiology and may have secondary premalignant features. Chronic UV light

exposure lead to damage to limbal stem cells. In 2001 Di Girolamo suggest possibility of limbal stem cell damage by ultraviolet light and activation of matrix metalloproteinase which lead to development of Pterygium.⁹ The abnormal P53 gene expression in the epithelium of Pterygium increase the possibility that it is due to uncontrolled cell proliferation.¹⁰ Microtrauma induced by dust, sand, wind or drying may also contributing factor. Pterygium is present in interpalpebral area and more common nasally due to increase UV damage in this area. The epidemiological studies also show its correlation with hot, dry, sunny, sandy climate and exposure to UV radiation. Pterygium is more common in periequatorial region. It is endemic in South East Asia, Mexico, Australia and in Eskimos. Pterygium was twice more common in outdoor workers but only one fifth in those who used sunglasses in outdoor.¹¹ The Barbados eye studies also shows that incidence of pterygium was high in black and outdoor workers, but protective eye wears and darker skin complexion decreases the risk. The only treatment of pterygium is surgical excision.

However, none of surgical method is perfect because recurrence is quite common. The recurrence usually occurs within one year. The various methods of treatment are bare sclera technique, redirection of pterygium head, pterygium excision with conjunctival autografting or amniotic membrane grafting, use of antimetabolites and beta radiations to prevent recurrence. The ideal procedure is which have minimum recurrence and complications. The conjunctival autografting described by Kenyon et al probably closest to this goal.¹² The conjunctival epithelium trans differentiate to cornea like epithelium.¹³ In 1943 Bangerter use movable conjunctival flap to prevent pterygium recurrence.¹⁴ Kenyon in 1985 used superotemporal bulbar conjunctival autograft from same eye in 57 eyes and found excellent results with very low recurrence rate (5.3%).¹² Conjunctival autograft can have placed with fibrin glue, sutures or sutureless glueless. The fibrin glue is biological tissue adhesive. It contains coagulation factors and act as a local haemostatic. The fibrin glue has fibrinogen and thrombin. Both components are prepared by processing human plasma. The components are mixed just at the site of application on the recipient surface by specially designed applicator. The resultant mixture stimulates the natural physiological phenomenon of blood clotting at the bleeding site and forms a firm viscous clot. This formed clot acts like a seal to arrest bleeding and glue tissue.

It also supports wound healing process and absorbed over several days to weeks by the naturally occurring endogenous fibrinolytic enzymes. First use of fibrin as a glue was done in 1909. There are various techniques to prepare fibrin glue. It can be prepared from homologous or autologous source. In homologous source, screened donors were taken, and inactivation of viruses was done by solvents or detergents. In autologous source there is no source of infection the product is sterilized by gamma

radiations. The use of fibrin glue result into shorter operative time, less postoperative discomfort and inflammation, less risk of wound infection contrary to sutures, smooth seal in entire length of wound edge, so provide higher tensile strength. As the risk of viral transmission and hypersensitivity reaction to fibrin glue the conjunctival autografting without sutures and fibrin glue can be done. The resident fibrin act as adhesive so graft can be transplanted without glue or sutures. This also decrease the discomfort, scarring and risk of infection due to foreign material. Karalezli A et al compared fibrin glue with suture in fifty eye they show that fibrin group had less operative time and less recurrence as compared to suture group.¹⁵ The Shrinivasan et al also compared in 40 eyes with conjunctival autografting with fibrin glue and sutures. They show that glue is effective and safe procedure with fewer complications.^{16,17} De Wit D et al in 2010 done a study on 15 eyes and shows good cosmosis and no intra-operative or post-operative complications with sutureless and glueless conjunctival autografting.¹⁸ The metanalysis by Pan HW et al in 2011 shows fibrin glue is superior to suturing autograft in terms of operative time and recurrence rate.¹⁹ While in 2013 a study done by Singh Punit K et al shows rate of recurrence same in both the groups but graft displacement and retraction more with sutureless and glueless conjunctival autograft. The difference is not statistically significant and complication more with larger grafts.²⁰

CONCLUSION

Our study shows that graft displacement is more in Sutureless and glueless conjunctival autograft which is statistically insignificant. The rate of recurrence is almost similar in both group and statistically insignificant. Conjunctival autograft is probable source of stem cells. graft stability is more with use of fibrin glue as compared to glueless and sutureless conjunctival autografting but using patients own blood as bioadhesive is safer and cost effective.

Funding: No funding sources

Conflict of interest: None declared

Ethical approval: The study was approved by the Institutional Ethics Committee

REFERENCES

1. Ang LP, Chua JL, Tan DT. Current concepts and techniques in pterygium treatment. *Curr Opin Ophthalmol.* 2007;18(4):308-13.
2. Gazzard G, Saw SM, Farook M, Koh D, Widjaja D, Chia SE, et al. Pterygium in Indonesia: prevalence, severity and risk factors. *Br J Ophthalmol.* 2002;86(12):1341-6.
3. Luthra R, Nemesure BB, Wu SY, Xie SH, Leske MC. Barbados Eye Studies Group. Frequency and risk factors for pterygium in the Barbados Eye Study. *Arch Ophthalmol.* 2001;119(12):1827-32.

4. Ma K, Xu L, Jie Y, Jonas JB. Prevalence of and factors associated with pterygium in adult Chinese: the Beijing Eye Study. *Cornea.* 2007;26(10):1184-6.
5. Threlfall TJ, English DR. Sun exposure and pterygium of the eye: a dose-response curve. *Am J Ophthalmol.* 1999;128(3):280-7.
6. Al-Bdour M, Al-Latayfeh MM. Risk factors for pterygium in an adult Jordanian population. *Acta Ophthalmol Scand.* 2004;82(1):64-7.
7. Mackenzie FD, Hirst LW, Battistutta D, Green A. Risk analysis in the development of pterygia. *Ophthalmology.* 1992;99(7):1056-61.
8. Austin P, Jakobiec FA, Iwamoto T. Elastodysplasia and elastodystrophy as the pathologic bases of ocular pterygia and pinguecula. *Ophthalmology.* 1983;90(1):96-109.
9. Di Girolamo N, Chui J, Coroneo MT, Wakefield D. Pathogenesis of pterygium: role of cytokines, growth factors and matrix metalloproteinases. *Prog Retin Eye Res.* 2004;23(2):195-228.
10. Weinstein O, Rosenthal G, Zirkin H, Monos T, Lifshitz T, Argov S. Overexpression of p53 tumor suppressor gene in pterygia. *Eye (Lond).* 2002;16(5):619-21.
11. Luthra R, Nemesure BB, Wu SY, Xie SH, Leske MC. Barbados Eye Studies Group. Frequency and risk factors for pterygium in the Barbados Eye Study. *Arch Ophthalmol.* 2001;119(12):1827-32.
12. Kenyon KR, Wagoner MD, Hettinger ME. Conjunctival autograft transplantation for advanced and recurrent pterygium. *Ophthalmology.* 1985;92(11):1461-70.
13. Tseng SCG, Hirst LW, Farazdaghi M, Green WR. Goblet cell density and vascularization during conjunctival transdifferentiation. *Investigative Ophthalmology Visual Science* October 1984;(25):1168-76.
14. Bengartar. Pterygium excision followed by movable conjunctival autograft to prevent recurrence. *Arch Ophthalmol.* 1950;44(6):854-69.
15. Karalezli A, Kucukerdonmez C, Akova YA, Altan-Yaycioglu R, Borazan M. Fibrin glue versus sutures for conjunctival autografting in pterygium surgery: a prospective comparative study. *Br J Ophthalmol.* 2008;92(9):1206-10.
16. Srinivasan S1, Dollin M, McAllum P, Berger Y, Rootman DS, Slomovic AR. Fibrin glue versus sutures for attaching the conjunctival autograft Pterygium surgery: a prospective observer masked clinical trial. *Br J Ophthalmol.* 2009;93(2):215-8.
17. Yüksel B1, Unsal SK, Onat S. Comparison of fibrin glue and suture technique in Pterygium surgery performed with limbal autograft. *Int J Ophthalmol.* 2010;3(4):316-20.
18. De Wit D, Athanasiadis I, Sharma A, Moore J. Singh Punit K. Sutureless and glue-free conjunctival autograft in pterygium surgery: a case series. *Eye (Lond).* 2010;24(9):1474-7.
19. Pan HW, Zhong JX, Jing CX. Comparison of fibrin glue versus suture for conjunctival autografting in Pterygium surgery: a meta-analysis. *Ophthalmology.* 2011;118(6):1049-54.
20. Singh PK, Singh S, Vyas C, Singh M. Conjunctival autografting without fibrin glue or sutures for pterygium surgery. *Cornea.* 2013;32(1):104-7.

Cite this article as: Jain K, Manohar JM. A comparative study of conjunctival autograft with fibrin glue or glueless sutureless conjunctival autograft after pterygium surgery. *Int J Res Med Sci* 2018;6:557-61.