

Original Research Article

A clinicopathological study of vernal conjunctivitis in urban and rural areas of Eastern India: A hospital based study

Suman Adhikari¹, Asok Kumar Naskar^{1*}, Samarendra Kabasi², Sujata Deb²,
R. K. Deb², Sukanta Sen³

¹Department of Ophthalmology, ICARE Institute of Medical Sciences and Research, Banbishnupur, Purba Medinipur, Haldia, West Bengal, India

²Department of Ophthalmology, Mata Gujari Memorial Medical College, Purabbali, Dinajpur Road, Kishanganj, Bihar, India

³Department of Pharmacology, ICARE Institute of Medical Sciences and Research, Haldia, West Bengal, India

Received: 07 January 2018

Accepted: 03 February 2018

*Correspondence:

Dr. Ashok Kumar Naskar,

E-mail: dranaskar1962@gmail.com

Copyright: © the author(s), publisher and licensee Medip Academy. This is an open-access article distributed under the terms of the Creative Commons Attribution Non-Commercial License, which permits unrestricted non-commercial use, distribution, and reproduction in any medium, provided the original work is properly cited.

ABSTRACT

Background: Vernal keratoconjunctivitis (VKC) is a relatively rare, chronic form of ocular allergy that can potentially cause severe visual complications.

Methods: The present study was carried out amongst the patients suffering from vernal conjunctivitis and attending the Outpatient Department of Ophthalmology of Mata Gujri Memorial Medical College & Lions Seva Kendra Hospital, Kishanganj (Bihar). The conjunctiva and cornea were examined for any complication of the disease. The patients were categorized into two treatment groups, each group treated with one topical drug. As the total number of patients in the study was 100, each treatment group consisted of 50 patients, one group of patients was treated with 0.05% azelastine eye drop and the other group treated with 2% sodium cromoglycate eye drop.

Results: Greater incidence during the period from March to June (59%) and the highest number in the month of May (18%). Of the 100 patients in the study group, the largest group of 89 patients presented with limbal vernal conjunctivitis; 7 patients presented with palpebral vernal conjunctivitis and 4 patients suffered from a mixed type (both limbal and palpebral) type of the disease.

Conclusions: Examination of the conjunctival biopsy specimens of the patients showed chronic nonspecific inflammatory reaction, mostly confined to the subepithelial region. Patients in both groups showed dramatic results of the treatment proving the efficacy of steroids.

Keywords: Azelastine eye drop, Prognosis, Sodium cromoglycate eye drop, Vernal keratoconjunctivitis

INTRODUCTION

Vernal keratoconjunctivitis (VKC) is a chronic, bilateral allergic disease of the external eye that leads to chronic irritation, watering, and discharge. It occurs universally but is more common in hot and dry environments. It typically affects children in their first two decades and although the majority of cases have a good prognosis and

resolve spontaneously after puberty, potentially sight-threatening corneal changes occur in up to 10% of patients.¹⁻⁵ It is an important cause of hospital referral among children in many parts of Asia with a prevalence of 5% reported for children in their first decade in Chad and Djibouti.⁶⁻⁸ The pathogenesis of VKC is complex and involves environmental, endocrine, racial, and genetic factors.⁹ Many studies of allergic diseases show a rural

environment to be protective but the mechanism of this effect is unknown.^{10,11} Allergic conjunctivitis may be divided into 5 major subcategories. Seasonal allergic conjunctivitis (SAC) and perennial allergic conjunctivitis (PAC) are commonly grouped together. Vernal keratoconjunctivitis (VKC), atopic keratoconjunctivitis (AKC), and giant papillary conjunctivitis (GPC) constitute the remaining subtypes of allergic conjunctivitis. Early diagnosis and treatment will help prevent the rare complications that can occur with this disease.¹²

Clinically, the three main types of vernal conjunctivitis are: Palpebral-primarily involves the upper tarsal conjunctiva. It may be associated with significant corneal disease as a result of the close apposition between the inflamed conjunctiva and the corneal epithelium. Limbal-typically affects blacks and Asian patients. Mixed-has features of both palpebral and mixed disease.

The main symptoms consist of ocular itching, lacrimation, photophobia, and redness of eyes, grittiness, foreign body sensation and thick mucoid ropy discharge. Vision is generally normal, but a slight blurring may occur if excess secretions form a film over the cornea. Vernal catarrh is characterized by signs such as conjunctival hyperaemia, papillary hypertrophy of the tarsal conjunctiva (pavement blocks), limbal papillae and Horner-Trantas' dots. The disease is of great concern because of its complications in the form of corneal involvement and neovascularization with those arising from chronic use of steroid.¹³

The present study was undertaken to find the seasonal variation, age distribution and sex predominance, the character of disease presentation, associated symptoms, general condition, complications and rate of recurrence and response to different treatment regimes.

METHODS

The present study was carried out amongst the patients suffering from vernal conjunctivitis and attending the Outpatient Department of Ophthalmology of Mata Gujri Memorial Medical College and Lions Seva Kendra Hospital, Kishanganj (Bihar), during the period 1st July 2011 to 30th June 2013 after taking approval from institutional ethics committee. The cases were selected on the basis of the following criteria:

Symptoms of ocular itching, photophobia, foreign body sensation, lacrimation and ropy discharge. Patients having the following signs: limbal papillae, gelatinous limbal swelling, Horner Trantas' dots, Giant papillae on the palpebral conjunctiva, corneal findings like superficial corneal ulcers, plaque like deposits, micropannus.

The ophthalmological examination composed of: recording of visual acuity with the Snellen's test types,

Slit-lamp examination and special emphasis was paid on the conjunctiva and cornea. The conjunctiva was examined for the following signs: Milky appearance or congestion of the conjunctiva, limbal papillary hypertrophy appearing as gelatinous swelling bordering mostly the superior limbus, white dots called Trantas' dots over the apices of the limbal papillae, giant papillae on the palpebral conjunctiva thick appear as flat topped, polygonal with tufts of capillaries giving rise to a cobblestone appearance and pseudomembrane in severe cases (Maxwell-Lyons sign).

The cornea was examined for any complication of the disease: Plaque like deposits over the cornea, superficial corneal ulcers called shield ulcers, diffuse epithelial keratitis, micropannus, pseudogerontoxon and corneal opacities. Bio microscopic examination of the cornea at slit lamp after 2% fluorescein staining was also an integral part of the examination in patients with corneal involvement. Fluorescein staining of the cornea was done using fluorescein strip. When examined using cobalt blue light the area denuded of epithelium appeared green. Routine investigations like total leucocyte count (TLC), differential leucocyte count (DLC), erythrocyte sedimentation rate or ESR (Wintergreen method), haemoglobin estimation (Helliges method), routine examination of stool and examination of urine and culture sensitivity.

Special investigations like cytological examination of conjunctival scrapings (conjunctival scrapings were taken with a spatula from the site of maximum involvement (limbus or everted tarsus) after the instillation of topical anaesthetic (4% Xylocaine)) was done. Histological study of conjunctival biopsies was done to study the types of cellular infiltrate. A peritomy (9 mm bordering the limbus and 5mm in breadth) was done to obtain a conjunctival specimen after infiltration of a local anaesthetic (2% xylocaine). As regards treatment, the patients were divided into two groups based on the type of drug received. Group I: Topical 0.05% Azelastine drops (topical antihistamine). Group II: Topical 2% cromolyn sodium drops (topical mast cell stabilizer).

The patients were followed up in the outpatient department at the end of a period of 1 week, 3 months, 6 months and 1 year. Routine recording of patient response, how he or she was facing during therapy and whether or not there was any complaint as felt by the patient was recorded and this was correlated by a full clinical eye examination including slit lamp examination. The aim of the follow up was to evaluate the efficacy and safety of the drugs depending on the response to the treatment. Another purpose was to look out for recurrences.

RESULTS

In the present study, altogether 100 cases of vernal conjunctivitis were examined. The case selection, investigations, documentation and analyses of the results

were done as per materials and methodologies of the study. Total duration of the study was 2 years. All the patients were selected on the basis of the eligibility criteria for diagnosis with 85% of the patients having past history of symptoms before entering the study. Vernal conjunctivitis consisted of 5.03% of the total patients of all types of conjunctivitis attending the outpatient department of Ophthalmology of Mata Gujri Memorial Medical College and Lions Seva Kendra Hospital, Kishanganj (Bihar) during the said period.

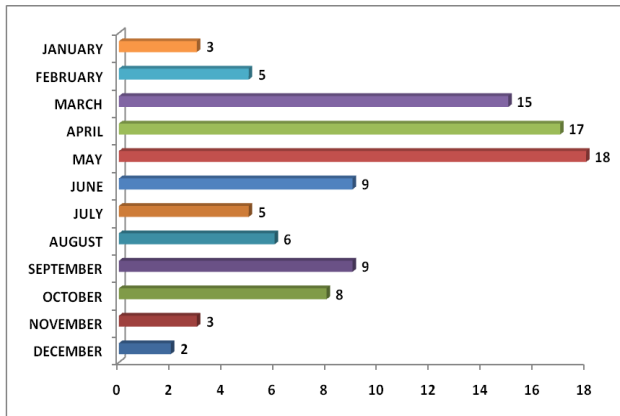


Figure 1: Showing distribution of the patients at different months of the year (n=100).

One hundred patients with clinically diagnosed active bilateral vernal conjunctivitis were entered in the study, of which, the maximum number of patients were in the 5-9 years age group (50 patients). The mean age of the patients was 9.65 years with a range between 3 and 38 years. Out of the total of 100 patients, there were seventy-four (74) male patients and twenty-six (26) female patients. Male patients thereby comprised 74% of the study group and female patients amounted to 26%. The patients attended the out-patient department almost all throughout the year presenting with signs and symptoms of vernal conjunctivitis, but with a greater incidence during the period from March to June (59%) and the highest number in the month of May (18%). There was a decline in the number of patients during the winter months. The patients presented with symptoms of itching, redness of the eyes, lacrimation, ropy discharge or photophobia. The symptoms of itching and redness were common to all patients with a variation in the prevalence of the other symptoms. The next common symptom was lacrimation (Table 1).

Table 1: Showing the prevalence of symptoms in patients (n=100).

Symptoms	Number of patients	Percentage
Itching	100	100
Redness	100	100
Lacrimation	67	67
Discharge	10	10
Photophobia	5	5

Table 2: Showing categories of the disease.

Severity of disease	Number of patients	%
Mild	33	33
Moderate	57	57
Severe	10	10

Table 3: Showing the outcome of treatment with the two drugs (n=100).

Name of the drug	Number of patients		
	Responding	Not responding	Total
Azelastine (0.05%)	41	9	50
Cromoline sodium (2%)	37	13	50

The sign of conjunctival congestion was noted in 100% of patients. The second most common sign in patients diagnosed with vernal conjunctivitis was limbal papillae (93%) followed by papillary hypertrophy of the palpebral conjunctiva (11%). Corneal complications were noted in 10 patients (10%), out of which one patient with corneal ulcer (10% of corneal complications) and two patients with corneal opacities (10% of corneal complications).

The disease was graded based on the symptoms score; as stated below:

Grade I: Mild: Patients having a history of one or two symptoms.

Grade II: Moderate: Patients presenting with three or more symptoms.

Grade III: Patient having corneal complications which added to the morbidity of the disease in this category of patients.

Patients with moderate and severe manifestations of the disease complained of the disease interfering with their activities, mainly attending school, as 95% of the patients included in the study group were students (3 to 19 years age range).

The clinical findings in the patients enable us to group the patients according to the types of the disease. Of the 100 patients in the study group, the largest group of 89 patients presented with limbal vernal conjunctivitis; 7 patients presented with palpebral vernal conjunctivitis and 4 patients suffered from a mixed type (both limbal and palpebral) type of the disease (Figure 5).

The routine blood examination revealed normal total leukocyte count in all patients. The differential count showed slight increase in the number of eosinophils in 20 of the hundred patients. The number of eosinophils in the patients with a high eosinophil count ranged between 7% and 14% with an average of 10%. Stool examination of

the patients showed hook worm ova in one patient and round worm ova in three patients. Routine examination of urine in the patients revealed no abnormality.

Examination of the conjunctival biopsy specimens of the patients showed chronic nonspecific inflammatory reaction, mostly confined to the subepithelial region. Section of the conjunctiva in one patient showed mild hyperplasia of squamous epithelium with very little sub-epithelial tissue. The result of a conjunctival biopsy in another patient revealed hyperplasia of the lining epithelium and proliferation of fibrovascular connective tissue along with an infiltration of inflammatory cells mostly lymphocytes, plasma cells and eosinophils, the picture fully suggestive of vernal conjunctivitis.

The patients were categorized into two treatment groups, each group treated with one topical drug. As the total number of patients in the study was 100, each treatment group consisted of 50 patients, one group of patients was treated with 0.05% azelastine eye drop and the other group treated with 2% sodium cromoglycate eye drop. The patients in the first group showed a better response, with forty-one patients relieved of their symptoms. So, the treatment failure cases in the first group comprised 18% of the total patients in the group. In the latter group treated with 2% sodium cromoglycate, 37 patients experienced an effective outcome of treatment. Here in this second group, treatment failure at the end of one week of application of the drug amounted to 26%. Therefore, topical application of azelastine was found to be a more effective form of treatment of active vernal conjunctivitis compared to sodium cromoglycate.

No adverse effect was reported by any patient in the two treatment groups, indicating that both drugs were safe. As no patient had any untoward reaction, withdrawal of the drug was not required in any patient. One patient in the study group exhibited Bitot's spots in both eyes. The patient was 9 years old and was included in the group for limbal type of vernal conjunctivitis. The child was treated with vitamin A supplementation beside conventional treatment. Antihelminthic therapy was also instituted as the stool examination of the child revealed round worm ova. No other patient was administered any systemic therapy.

The patients not responding to Azelastine eye drops were treated with fluorometholone 0.01% eye drops, one drop four times daily for one week. Same treatment was administered in patients not responding to sodium cromoglycate eye drop. Patients in both groups showed dramatic results of the treatment proving the efficacy of

steroids. A total of 44 patients reported to the outpatient department within the study period with the same complaints as in the previous visit. So, recurrence of the disease was found in 44% of the total patients of 100.

DISCUSSION

Vernal keratoconjunctivitis (VKC) is an allergic eye disease that especially affects young boys. The most common symptoms are itching, photophobia, burning, and tearing. The most common signs are giant papillae, superficial keratitis, and conjunctival hyperaemia. Patients with VKC frequently have a family or medical history of atopic diseases, such as asthma, rhinitis, and eczema. The pathogenesis of VKC is probably multifactorial, with the interaction of the immune, nervous, and endocrine systems. The clinical management of VKC requires a swift diagnosis, correct therapy, and evaluation of the prognosis. The diagnosis is generally based on the signs and symptoms of the disease, but in difficult cases can be aided by conjunctival scraping, demonstrating the presence of infiltrating eosinophils. Therapeutic options are many, in most cases topical, and should be chosen on the basis of the severity of the disease. The most effective drugs, steroids, should however be carefully administered, and only for brief periods, to avoid secondary development of glaucoma. A 2% solution of cyclosporine in olive oil or in castor oil should be considered as an alternative. The long-term prognosis of patients is generally good; however, 6% of patients develop corneal damage.¹⁴⁻¹⁶

Saboo US et al showed Mean age at presentation was 12 years.¹⁷ Majority of the patients had mixed pattern disease (72%). Chronic perennial disease was seen in 36% patients. Personal or family history of allergies was noted in 5% patients. Severe disease based on clinical grading was present in 37% patients. Moderate to severe vision loss was seen in 12% of total population. Persistent disease beyond 20 years of age was found in 12% patients. VKC-related complications such as corneal scarring (11%), shield ulcer (3%), keratoconus (6%), and limbal stem cell deficiency (1.2%) were seen. Treatment-related complications like corticosteroid-induced cataract and glaucoma were seen in 6% and 4% of patients, respectively.

VKC is a chronic allergic inflammation of the ocular surface mediated mainly by Th2-lymphocyte; in a complex pathogenesis have a role also the over-expression of mast cells, eosinophils, neutrophils, Th2-derived cytokines, chemokines, adhesion molecules, growth factors, fibroblast and lymphocytes. IL-4 and IL-13 are involved in the formation of giant papillae by inducing the production of extra-cellular matrix and the proliferation of conjunctival fibroblasts.^{14,18} VKC has three clinical forms: palpebral, limbal, and mixed, with an overall preponderance in males.¹⁸

Symptoms include ocular itching, redness, swelling and discharge. Itching may be quite severe, and even incapacitating. Patients have often photophobia, sometimes very severe. The most characteristic sign is giant papillae on the upper tarsal conjunctiva (Figure 2, 3). These ‘cobblestone-like’ swellings may be several millimeters in diameter. Usually, 10-20 are found on the tarsal conjunctiva, and they can be seen easily by ‘flipping’ the upper eyelid.¹⁹

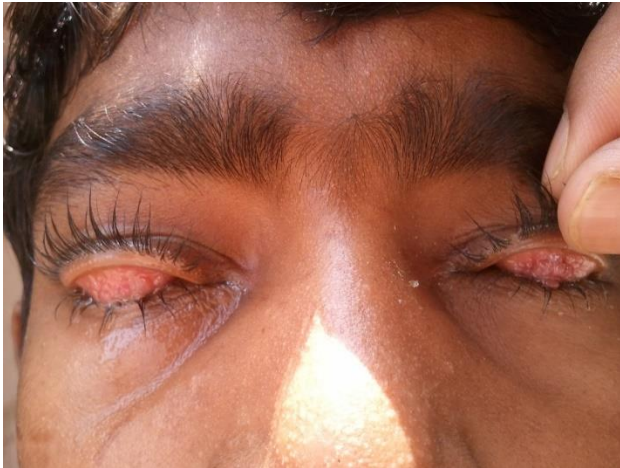

Figure 2: Giant papillary hypertrophy (after everting upper eye lids).

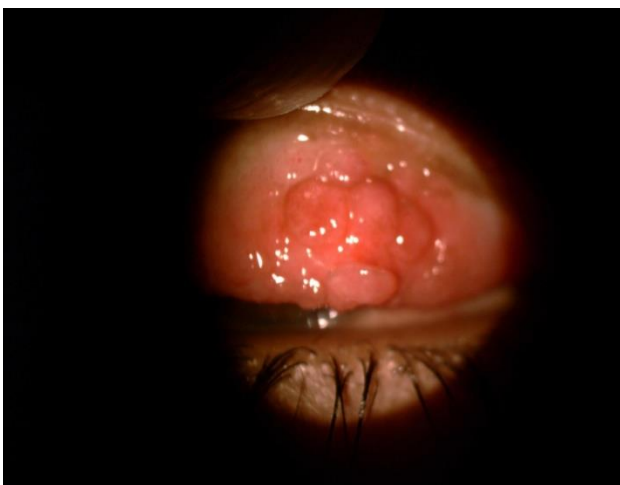

Figure 3: Giant papillary hypertrophy (on slit lamp examination).

Of the 100 patients included in the study group, the mean age of the patients was 9.65 years with a range between 3 and 38 years.

A study conducted by Mark Ballow et al showed that the age of the patients ranged from 8 to 34 years with a mean age of 13 years.²⁰ M. Srinivasan and S. Srinivasan reported a study of 76 patients with vernal conjunctivitis in which the age ranged from 3 to 43 years.²¹ Bleik and Tabbara demonstrated a range of 5 to 19 years with a mean age of 9.7 years.²²

Table 4: Demonstrating comparison of age distribution in different study groups.

Author	Age range	Mean age
Mark Ballow et al (1985) ²⁰	8-34 years	13 years
M. Srinivasan (1990) ²¹	3-4 years	-
Bleik and Tabbara (1991) ²²	5-19 years	9.7 years
Present study	3 -38 years	9.65 years

The number of male patients in the study group of 100 was 74 and the number of female patients was 26, proving again the preponderance of the disease in males. The sex distribution in a study conducted by Mark Ballow et al consisting of 30 patients was 25 males and 5 female cases.²⁰ M. Srinivasan in a study conducted in 1990 found 60 male cases and 16 female cases in a study group of 76 patients.²¹ Bleik et al found 19 males and 1 female enrolled in a study of 20 patients with vernal conjunctivitis.²²

Table 5: Demonstrating comparison of sex distribution in different study groups.

Author	% male cases	% of female cases
Mark Ballow et al (1985) ²⁰	83.3	16.6
M Srinivasan (1990) ²¹	78.9	21.05
Bleik and Tabbara (1991) ²²	95	5
Present study	74	26

An analysis of the distribution of patients with vernal conjunctivitis in the present study indicated occurrence of the disease throughout the year with a peak during the summer months from March to June reached 59 %. The results of seasonal distribution in this study correlates with the reports by the other authors. Friedlaender MH states that patients with vernal keratoconjunctivitis may suffer from symptoms throughout the year, but the intensity of the disease increases in spring and summer.^{23,24} This view is supported by McGill J. et al who comment that there is a seasonal peak in incidence in spring when exposure to tree grass pollens increases, suggesting an extrinsic element in the disease.²⁵ Eleven patients in the study group of hundred patients presented with a history of other atopic diseases as eczema or asthma, besides vernal conjunctivitis. Personal history of atopic disease is important as vernal conjunctivitis being an allergic disorder, is likely to occur concomitantly with other allergic diseases. According to Esen Karamursel Akpek, there is a history of eczema or asthma in 75% of patients.²⁶ In the study only 10.7% of the cases had an associated history of asthma or eczema.

Every patient in the 100-member study group complained of itching. Esen Karamursel Akpek stated that the 'sine-qua-non' symptom of vernal keratoconjunctivitis is itching.²⁶ This statement is proved in this study as 100%

of the patients complained of the problem which disrupted their normal day-to-day activities. Redness of the eyes was also complained of by 100% of the patients, lacrimation by 67% and photophobia by 5%. Eight patients complained of redness of the eyes, six patients complained of photophobia, three patients presented with lacrimation and one patient complained of foreign body sensation.

Table 6: Demonstrating comparison of the prevalence of clinical signs in different study groups.

Clinical signs	Percentage of patients		
	C.S. Foster	M. Srinivasan	Present study
Conjunctival	98.6	-	100
Papillary hypertrophy	100	100	100
Corneal involvement	70.6	72.36	10

In this study group comprising 100 patients, each patient presented with conjunctival congestion. This was followed by papillary hypertrophy either limbal or palpebral by each patient. Corneal involvement was diagnosed on examination in 10 patients, 3 patients presenting with corneal ulcer and 7 patients presenting with corneal opacities. These findings in the present study were similar to those stated in the report by C.S. Foster et al.²⁷ He found 64 of the 65 patients in his study presenting with conjunctival injection, experiencing it to some degree at some point during the study. All 65 patients exhibited papillary hypertrophy, and 46 of the 65 patients had superficial punctate keratitis at some point of

the study; this second finding did not tally with the present study as only 3 patients of the present study group of 56 demonstrated corneal involvements. The reason behind this may be the less number presenting of cases with palpebral type of the disease in the present study. M Srinivasan et al states that vernal ulcer was found more in the palpebral type of vernal conjunctivitis.²¹ The disease is classified into three types: limbal type of vernal conjunctivitis, palpebral type of vernal conjunctivitis and mixed type of vernal conjunctivitis. In the present study, 89% of the patients presented with limbal type of vernal conjunctivitis, 7% presented with palpebral type of vernal conjunctivitis and 4% presented with the mixed type of vernal conjunctivitis. C.

Stephen Foster et al reported 8 patients of his study group of 65 patients as suffering from limbal type of vernal conjunctivitis.²⁸ Palpebral type of the disease comprised 51 patients in his study and mixed type was the smallest group with 6 patients presenting with this manifestation.

According to a study conducted by M Srinivasan et al, 36 patients of his group of 76 presented with the palpebral type, 32 had limbal type and 8 had a mixed type of vernal conjunctivitis.²¹ The result derived from the present study indicated that a less number of patients presented with palpebral type of the disease. This view is supported by J McGill et al according to whom the palpebral type predominated in white patients.²⁵ This finding is evident since Sir Stewart Duke-Elder stated that colored races are particularly prone to the limbal form of the disease, back in 1965. A Asrar et al (1996) holds a similar view. According to him, limbal form of the disease appears to be found more frequently in the black population.²⁸

Table 7: Percentage distribution of patients in the three types of the disease as found by authors in different countries and in India.

Type of vernal Conjunctivitis	In the United States			In Egypt		In India
	Posey (1924) ²⁹	Lehrfeld (1932) ³⁰	C.S. Foster (1988) ²⁷	Tobgy (1933) ³¹	M. srinivasan et al (1990) ²¹	Present study
Palpebral	60%	55%	78.46%	17.4%	47.36%	7%
Limbal	40%	45%	12.3%	11.2%	42.10%	89%
Mixed	-	-	9.23%	71.4%	10.5%	4%

Ciprandi G. et al conducted a study on the effects of azelastine eye drops after allergen specific conjunctival challenge (ASCC).³² Results showed that when administered 30 min after ASCC, Azelastine produced a clinical effect ranging between 10 and 20 min after eye drops administration. After 7 days of treatment, 30 min after ASCC, Azelastine induced a reduction of symptom scores, a reduction of inflammatory cell infiltration and a reduction of ICAM-1 (Inter cellular adhesion molecule-1) expression on conjunctival epithelial cells. This study

therefore had very clearly demonstrated the efficacy of azelastine in reducing the symptoms of allergic conjunctivitis. The present study also supports the efficacy of azelastine as treatment of vernal conjunctivitis which is nothing but a form of allergic conjunctivitis.

The efficacy of azelastine in the therapy of allergic conjunctivitis was also supported by a study conducted by Mitchell H. Friedlaender et al.²³ No untoward effect of

topical Azelastine as a cause of discontinuation of the drug was noted in the present study.

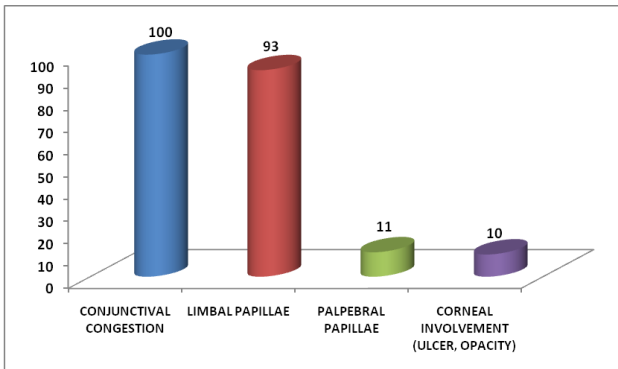


Figure 4: Showing prevalence of ocular signs (n=100).

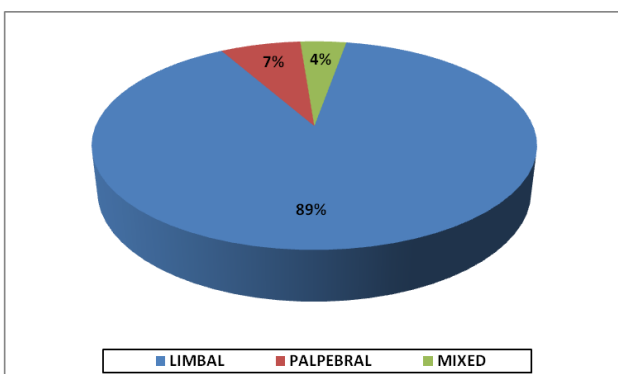


Figure 5: Showing percentage distribution of patients in the three types of vernal conjunctivitis.

CONCLUSION

Vernal keratoconjunctivitis (VKC) is a bilateral, usually seasonally recurrent, allergic inflammation of the conjunctiva, characterised by limbal gelatinous hypertrophy and/or upper tarsal giant conjunctival papillae. Several predisposing conditions include endocrine, genetic, neurogenic, environmental and socioeconomic risk factors.

Mast cell stabilizers, antihistamines and topical corticosteroids are often used during acute flare-ups in VKC; however, this approach is unsatisfactory for controlling severe cases and avoiding recurrences. Recurrences of inflammation are characterized by intense ocular symptoms of itching; redness and photophobia associated with corneal involvement ranging from punctate keratitis to corneal shield ulcers with risk of visual impairment. The goals of VKC treatment are to control inflammation, improve quality of life and avoid corneal complications.

Funding: No funding sources

Conflict of interest: None declared

Ethical approval: The study was approved by the Institutional Ethics Committee

REFERENCES

1. Tabbara KF. Ocular complications of vernal keratoconjunctivitis. *Can J Ophthalmol.* 1999;34:88-92.
2. Cameron JA. Shield ulcers and plaques of the cornea in vernal keratoconjunctivitis. *Ophthalmol.* 1995;102:985-993.
3. Dahan E, Appel R. Vernal keratoconjunctivitis in the black child and its response to therapy. *Br J Ophthalmol.* 1983;67:688-692.
4. BenEzra D, Pe'er J, Brodsky M, Cohen E. Cyclosporine eye drops for the treatment of severe vernal keratoconjunctivitis. *Am J Ophthalmol.* 1986;101:278-282.
5. De Smedt S, Nkurikiye J, Fonteyne Y, Hogewoning A, Van Esbroeck M, De Bacquer D, Tuft S, Gilbert C, Delanghe J, Kestelyn P. Vernal keratoconjunctivitis in school children in Rwanda and its association with socio-economic status: a population-based survey. *American J Trop Med Hyg.* 2011;85(4):711-7.
6. Khan MD, Kundi N, Saeed N, Gulab A, Nazeer AF. A study of 530 cases of vernal conjunctivitis from the North West Frontier Province of Pakistan. *Pak J Ophthalmol.* 1986;2:111-114.
7. Resnikoff S, Cornand G, Filliard G, Hugard L. Limbal vernal conjunctivitis in the tropics. *Rev Int Trach.* 1988;3-4:53-71.
8. Sethi M, Nanda R, Bali AS, Sadhotra P. Hospital based study of demography and clinical picture of vernal keratoconjunctivitis. *Int J Res Med Sci.* 2018;6:65-8.
9. Bonini S, Bonini S, Lambiase A, Marchi S, Pasqualetti P, Zuccaro O, et al. Vernal keratoconjunctivitis revisited. A case series of 195 patients with long-term followup. *Ophthalmol.* 2000;107:1157-1163.
10. Yemaneberhan H, Bekele Z, Venn A, Lewis S, Parry E, Britton J. Prevalence of wheeze and asthma and relation to atopy in urban and rural Ethiopia. *Lancet.* 1997;350:85-90.
11. Viinanen A, Munhbayarlah S, Zevgee T, Narantsetseg L, Naidansuren T, Koskenvuo M, et al. The protective effect of rural living against atopy in Mongolia. *Allergy.* 2007;62:272-280.
12. Williams PB, Crandall E, Sheppard JD. Azelastine hydrochloride, a dual-acting anti-inflammatory ophthalmic solution, for treatment of allergic conjunctivitis. *Clin Ophthalmol.* 2010;4:993-1001.
13. La Rosa M, Lionetti E, Reibaldi M, Russo A, Longo A, Leonardi S, et al. Allergic conjunctivitis: a comprehensive review of the literature. *Ita J pediatrics.* 2013;39(1):18.
14. Bonini S, Coassin M, Aronni S, Lambiase A. Vernal keratoconjunctivitis. *Eye (Lond).* 2004;18(4):345-51.
15. Pleyer U, Leonardi A. Vernal keratoconjunctivitis. *Ophthalmol.* 2015;112(2):177-89.

16. Vichyanond P, Pacharn P, Pleyer U, Leonardi A. Vernal keratoconjunctivitis: a severe allergic eye disease with remodeling changes. *Pediatr Allergy Immunol.* 2014;25(4):314-22.
17. Saboo US, Jain M, Reddy JC, Sangwan VS. Demographic and clinical profile of vernal keratoconjunctivitis at a tertiary eye care center in India. *Ind J Ophthalmol.* 2013;61(9):486-9.
18. Leonardi A, Secchi AG. Vernal keratoconjunctivitis. *Int Ophthalmol Clin.* 2003;43(1):41-58.
19. Bielory L, Frohman L. Allergic and immunologic disorders of the eye. *J Allergy Clin Immunol.* 1992;86:1-20.
20. Ballow, Mark et al. Complement proteins and C3 anaphylatoxin in the tears of patients with conjunctivitis. *J Allergy Clinical Immunol.* 1985;76(3):473-6.
21. Srinivasan M, Srinivasan S. Vernal ulcer. *Ind J Ophthalmol.* 1990;38:33-4.
22. Bleik JH, Tabbara KF. Topical cyclosporine in vernal keratoconjunctivitis. *Ophthalmol.* 1991;98(11):1679-84.
23. Friedlaender M, Harris J, Lavalley N, Russell H, Shilstone J. Evaluation of the onset and duration of effect of azelastine eye drops [0.05%] versus placebo in patients with allergic conjunctivitis using an allergen challenge model. *Ophthalmol.* 2000;107:2152-7.
24. Friedlaender MH, Okumoto M, Kelley J. Diagnosis of allergic conjunctivitis. *Arch Ophthalmol.* 1984;102(8):1198-9.
25. McGILL J, Holgate S, Church M, Anderson D, Bacon A. Allergic eye disease mechanisms. *The Brit J Ophthalmol.* 1998;82(10):1203-14.
26. Akpek EK, Hasiripi H, Christen WG, Kalayci D. A randomized trial of low-dose, topical mitomycin-C in the treatment of severe vernal keratoconjunctivitis. *Ophthalmol.* 2000;107:263-9.
27. Foster CS. Evaluation of cromolyn sodium in the treatment of vernal keratoconjunctivitis. *Ophthalmol.* 1988;95:194-201.
28. EL-Asrar AM, Tabbara KF, Geboes K, Missotten L, Desmet V. An immunohistochemical study of topical cyclosporine in vernal keratoconjunctivitis. *Ame J Ophthalmol.* 1996;121(2):156-61.
29. Posey WC. Vernal Conjunctivitis. *Atlantic Med J.* 1924;27:215-9.
30. Lehrfeld L. Vernal conjunctivitis observations on eighty-seven cases at the Wills Hospital (1929-1931). *Arch Ophthalmol.* 1932;8(3):380-404.
31. Tobgy R. *Folia Ophthal. Orient,* 1933;1:168.
32. Ciprandi G, Buscaglia S, Catrullo A, Pesce G, Fiorino N, Montagna P, et al. Azelastine eye drops reduce and prevent allergic conjunctival reaction and exert anti-allergic activity. *Clin Exp Allergy.* 1997;27(2):182-91.

Cite this article as: Adhikari S, Naskar AK, Kabasi S, Deb S, Deb RK, Sen S. A clinicopathological study of vernal conjunctivitis in urban and rural areas of Kishanganj district: a hospital based study. *Int J Res Med Sci* 2018;6:966-73.