

## Original Research Article

# Investigation the effect of propranolol, metoprolol and carvedilol on spermatogenesis in rat testis

Huseyin Eren<sup>1\*</sup>, Abdullah Sivrikaya<sup>2</sup>, Umit Cobanoglu<sup>3</sup>, Nuri Ihsan Kalyoncu<sup>4</sup>,  
Ersagun Karaguzel<sup>2</sup>, Murat Topbaş<sup>5</sup>, Ilke Onur Kazaz<sup>2</sup>,  
Mustafa Ozan Horsanali<sup>1</sup>, Omer Kutlu<sup>6</sup>

<sup>1</sup>Department of Urology, Recep Tayyip Erdogan University School of Medicine, Turkey

<sup>2</sup>Department of Urology, <sup>3</sup>Department of Pathology, <sup>4</sup>Department of Pharmacology, <sup>5</sup>Department of Public Health, Karadeniz Technical University, School of Medicine, Trabzon, Turkey

<sup>6</sup>Department of Urology, Akdeniz University, School of Medicine, Antalya, Turkey

**Received:** 30 January 2018

**Accepted:** 26 February 2018

### \*Correspondence:

Dr. Huseyin Eren,

E-mail: [huseyin.eren@erdogan.edu.tr](mailto:huseyin.eren@erdogan.edu.tr)

**Copyright:** © the author(s), publisher and licensee Medip Academy. This is an open-access article distributed under the terms of the Creative Commons Attribution Non-Commercial License, which permits unrestricted non-commercial use, distribution, and reproduction in any medium, provided the original work is properly cited.

## ABSTRACT

**Background:** Coronary arterial diseases are one of the increasing disease around the worldwide. Because of common using of the beta blockers, we aimed to investigate the effect of different beta-adrenergic receptor blockers on spermatogenesis in male rats.

**Methods:** Adult male Sprague Dawley rats were obtained. Totally 32 rats homogenized according to their weight and divided into four groups that each one includes eight rats. Three of groups were determined as drug groups and remained groups were determined as a control group. Propranolol 40mg/kg, Metoprolol succinate 60mg/kg, Carvedilol 30mg/kg dosage was given by oral gavage within the saline solution, and the only saline solution was given to control group for 21 days, respectively. After 21 days rats were sacrificed, and testis were extracted. Then, histopathologic evaluation was performed.

**Results:** There was statistical significance both right and left testis volume of experimental between control and carvedilol groups ( $p < 0.05$ ). There was statistical histopathological significance between control and carvedilol ( $p < 0.05$ ), control and propranolol ( $p < 0.05$ ), metoprolol succinate and propranolol ( $p < 0.05$ ), metoprolol succinate and carvedilol groups ( $p < 0.05$ ), respectively.

**Conclusions:** Beta-adrenergic receptor blockers have adverse effects on spermatogenesis. Especially propranolol and carvedilol that were non-selective, effects spermatogenesis worse than selective beta blockers such as metoprolol succinate. Extensive use of these drugs may affect spermatogenesis in male, so male patients who have a complaint of infertility should be questioned regarding the use of beta blockers.

**Keywords:** Carvedilol, Metoprolol succinate, Propranolol, Spermatogenesis, Testis

## INTRODUCTION

Coronary arterial diseases are one of the increasingly common chronic diseases around the worldwide. Both selective and non-selective adrenergic receptor blockers, especially selective  $\beta_1$ -adrenoceptor antagonists, are

often used to treat cardiovascular disease, even when complicated by chronic obstructive pulmonary disease.<sup>1</sup> Most studies reported that sexual adverse effects were increased as if lumbal sympathectomy was performed by increasing clinical use of beta-blockers.<sup>2-4</sup> These adverse effects of beta-blockers are considered that depends on

their chemical structure. Sexual adverse effects are more common in propranolol which has lipophilic structure.<sup>5,6</sup>

Propranolol is a  $\beta_1$ - $\beta_2$  selective receptor blockers. Most studies revealed that propranolol had a histopathologically toxic effect on the testis. Animal model studies showed that propranolol could involve degeneration, necrosis, fibrosis, hypocellularity in germinal epithelium and dystrophic calcification in seminiferous tubules. It is considered that beta blockers impair spermatogenesis via  $\beta_2$ -receptors.<sup>7,8</sup>

Metoprolol is a selective  $\beta_1$ -adrenergic antagonist, extensively used since 1975. Metoprolol has proven its efficacy in reducing cardiovascular events and mortality in patients with hypertension and coronary heart disease.<sup>9</sup> So, it is considered that cardiovascular, respiratory and metabolic and also adverse effects are less than other beta-blockers.<sup>10</sup>

Carvedilol is a  $\alpha_1/\beta$ -adrenoreceptors blocker, used in the treatment of hypertension and congestive heart failure.<sup>11</sup> It selectively blocks  $\alpha_1$ -receptors, and non-selectively antagonizes  $\beta_1$  and  $\beta_2$ -adrenoreceptors.<sup>12</sup> Carvedilol and some of its metabolites also display antioxidant activity. This antioxidant characteristic of carvedilol has been shown in previous in vitro studies and animal models.<sup>13-16</sup> In the present study, we aimed to investigate the histopathological effect of the different kind adrenergic receptor blockers (propranolol, metoprolol, and carvedilol) on spermatogenesis, used the treatment of cardiovascular diseases, in rat testis.

## METHODS

### Animal study

Adult male Sprague Dawley rats weighed between 250-350g, were obtained from Karadeniz Technical University, Faculty of Medicine, Surgical Research Center, Animal Experiment Laboratory (Trabzon, Turkey). All animals received humane care according to the criteria outlined in the 'Guide for the Care and Use of Laboratory Animals' prepared by the National Academy of Sciences and published by the National Institutes of Health.

The study was approved by Karadeniz Technical University Animal Ethical Committee (2010/46). Animals were kept under controlled temperature ( $23 \pm 2$  C) and relative humidity ( $60 \pm 10\%$ ) conditions, with a 12/12h light/dark cycle and fed lab chow and water ad libitum.

One day after the last treatment, rats were weighed and anesthetized. Totally 32 rats homogenized according to their weight and divided into four groups that each one includes eight rats. Three of groups were determined as drug groups, and remaining group was determined as a control group. Propranolol 40mg/kg, metoprolol

succinate 60mg/kg, carvedilol 30mg/kg dosages were given by oral gavage within the saline solution, respectively. Saline solution was given to control group. All drugs and saline were given to experimental animals by oral gavage in every 24 hours. The application was continued 21 days. When 21 days completed, after a day, rats were sacrificed with high dosage ketamine. After a midline incision, testis was extracted from inguinal canal and epididymis were removed, then they were put in Bouin solution.

### Histopathological procedure

Testis were fixed in Bouin solution for 24 hours. After paraffin blocks were prepared, 4-5 micron sections were performed and painted with Haematoxylin-Eosin (HandE). Sections were evaluated with Nikon E200 light microscope (Nikon, Tokyo, Japan). Histopathological evaluation criteria were performed according to references of Creasy's testis toxicity score method [16]. Toxicologic classification of the testis is summarized in Table 1.

**Table 1: Toxicologic classification of testis (Creasy's criteria).**

0	Normal
1	Presence of retained spermatids
2	Missing germ cell thickness
3	Multi-nucleated giant cells
4	The presence of severed spermatogenic cells
5	A change in the interstitial structure

### Statistical analysis

The package used for statistical analyses was the SPSS Statistics 18.00 (IBM Inc., Chicago, USA). The testis weights data were expressed as a mean $\pm$ standart deviation. Statistical analysis was performed using one-way analysis of variance followed by Tukey test (Table 2). Histological damage Creasy's testis toxicity were expressed as a median $\pm$ standart deviation. Statistical analysis was performed using nonparametric Kruskal-Wallis test. Between groups differences were performed using Tamhane's T2 test (Table 4). ( $p < 0.05$ , which is considered to be significant).

## RESULTS

### Testis weights results

No statistical significance were found between right and left testis weights in the all groups rat. There was statistical significance between control and carvedilol groups for both right and left testis. Results of all groups were summarized in Table 2 ( $p < 0.05$ ).

For the right testis, there was statistical significance between control and carvedilol group regarding right

testicular volume ( $p < 0.05$ ). Similar results were observed for left testis between control and carvedilol group, as well ( $p < 0.05$ ). There was no statistically significant in terms of both rights and left testicular volume between propranolol and metoprolol, metoprolol and carvedilol, propranolol and carvedilol, propranolol and control, metoprolol and control group, respectively ( $p > 0.05$ ). Data of histopathological evaluation was summarised in Table 3.

**Table 2: Testis weights statistical analysis.**

Groups	Right testis volume	Left testis volume
Propranolol	314±23 <sup>b,d,f</sup>	315±24 <sup>b,d,f</sup>
Metoprolol Succinate	313±28 <sup>b,c,f</sup>	313±27 <sup>b,c,f</sup>
Carvedilol	295±27 <sup>a,c,d</sup>	313±23 <sup>a,c,d</sup>
Control	346±27 <sup>c,d,e</sup>	343±27 <sup>c,d,e</sup>

ap<0.05 versus to control group, bp>0.05 versus to control group, cp>0.05 versus to propranolol group, dp>0.05 versus to metoprolol succinate, ep<0.05 versus to carvedilol, fp>0.05 versus to carvedilol, One-way ANOVA-Tukey test

**Table 3: Histological damage Creasy's criteria scores data.**

	Numbers of rats							
	1	2	3	4	5	6	7	8
Control	0	1	2	1	1	0	1	2
Propranolol	4	5	3	4	3	4	4	5
Metoprolol succinate	1	2	1	0	2	1	1	2
Carvedilol	3	5	4	4	3	3	4	4

**Table 4: Histological damage Creasy's criteria scores analysis.**

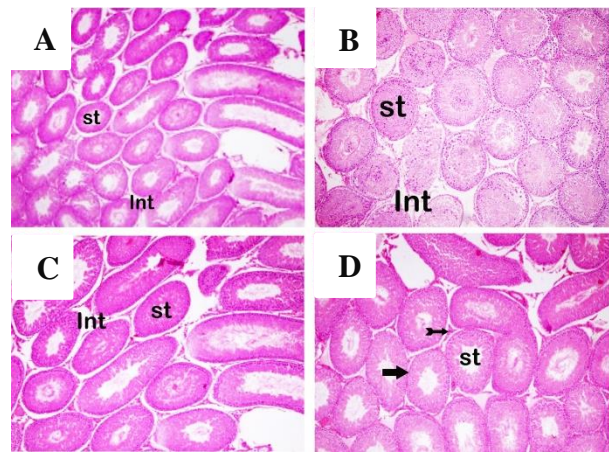
Groups	Creasy's criteria scores (Median±Standard deviation)
Control	1.00±0.76 <sup>b,d</sup>
Propranolol	4.00±0.76 <sup>a</sup>
Metoprolol Succinate	1.00±0.71 <sup>b,c</sup>
Carvedilol	4.00±0.71 <sup>a,c,d</sup>

aP<0.05 versus to Control group, bP<0.05 versus to Propranolol group, cP<0.05 versus to Metoprolol Suc. group, dP <0.05 versus to Carvedilol group, Kruskal-Wallis,Tamhane's T2 test, Histological damage creasy's testis toxicity score results.

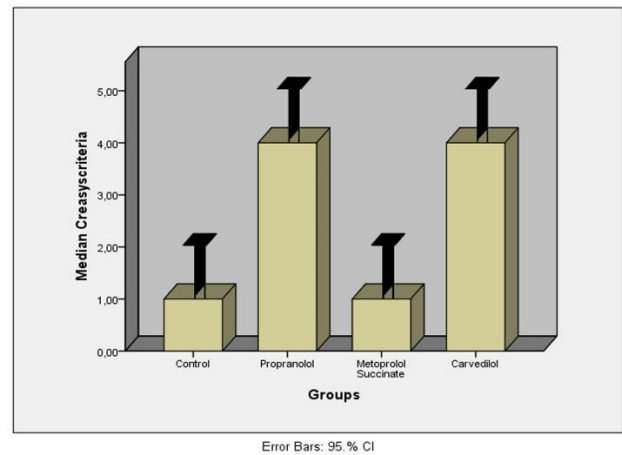
Statistical significance was observed between groups with Kruskal-Wallis test regarding histopathological evaluation ( $p < 0.05$ ). Between groups differences were performed Tamhane's T2 test was adjusted for post hoc test, there was statistical significance between control and carvedilol ( $p < 0.05$ ), control and propranolol ( $p < 0.05$ ), metoprolol succinate and propranolol ( $P < 0.05$ ), metoprolol succinate and carvedilol groups ( $p < 0.05$ ), respectively. No significance was observed between metoprolol and other drugs groups ( $p > 0.05$ ) (Table 4), (Figure 1, 2).

**DISCUSSION**

Beta-adrenergic receptor blockers bind its adrenergic receptors irreversible. So that, they antagonize the effect of sympathoadrenal system stimulation or beta mimetic (agonist) drugs on variable structures. There are two main types of Beta-receptors;  $\beta_1$  and  $\beta_2$  adrenergic receptors. Then, an atypical beta-receptor  $\beta_3$  and  $\beta_4$  receptor types were defined. Beta-adrenergic receptors have different affinity to various agonists and antagonists.



**Figure 1: Representative light microscopic photographs from testis tissue sections stained with H and E. x10. A-Control group (normal histologic appearance), B-Propranolol, C-Metoprolol Succinate group, D-Carvedilol group. Seminiferous tubules (St). Interstitial area (Int).**



**Figure 2: Histological damage Creasy's criteria scores graphs.**

Most important fundamental pharmacological properties of these drugs are their selectivity. Some Beta-blockers have an equally high affinity to  $\beta_1$  and  $\beta_2$  receptors and blocks both receptors equally. These drugs are described as non-selective beta-blockers. Propranolol is the most important example of these non-selective beta blockers.

Moreover, also, carvedilol is an example which blocks  $\alpha_1$  receptor in addition to  $\beta_1$  and  $\beta_2$  receptors. However, there are some selective drugs which have higher affinity to  $\beta_1$  receptors compared against  $\beta_2$  receptors. Metoprolol succinate is a striking example of this drug. So that, these drugs have less adverse effects such as broncho-constriction, vasoconstriction, and metabolic effects because do not block the  $\beta_2$  receptor.

Propranolol is a  $\beta_1$ - $\beta_2$  selective and complete antagonist. It has no intrinsic sympathomimetic activity. It is a lipophilic drug and turns to its active metabolite in the liver. It stabilizes the cell membrane against the depolarization by blocking the  $\text{Na}^+$  channels over the cytoplasmic membrane.

Carvedilol is a  $\beta_1$ - $\beta_2$  and  $\alpha_1$  selective beta blocker. It has no intrinsic sympathomimetic activity and does not have a lipophilic structure like propranolol. It does not engage membrane stabilization.<sup>17</sup> Carvedilol is the almost completely blocked increased sympathetic activity, unlike other beta-antagonists. Also, carvedilol blocks presynaptic  $\beta_2$  stimulation and do not increase myocardial  $\beta_1$  receptor density like selective  $\beta_1$ -blockers.<sup>18</sup>

Metoprolol succinate, unlike propranolol and carvedilol, is a selective beta-blockers and blocking  $\beta_1$  receptors. According to this, it has a little adverse effect on the respiratory system, cardiovascular system, and metabolism, clinically.<sup>19</sup> It is thought that these adverse effects occur via  $\beta_2$  receptors. Toxic effects of propranolol on testis were demonstrated with several histopathological studies. It is conceivable that similar adverse effects could occur in the testis.<sup>7,8</sup>

Bandmann revealed in his study that atrophy on testis and loss of libido occurred after unilateral lumbal sympathectomy and sperm parameters decreased.<sup>20</sup> Increased sexual adverse effects similar to lumbal sympathectomy were reported after increasing clinical use of beta-blockers.<sup>2,3</sup> Increased adverse effects of beta-blockers are seen to be due to their chemical properties. Sexual adverse effects can be seen more common with lipophilic beta-blockers like propranolol.<sup>5,6</sup>

Several studies reported the effect of beta-blockers on testis. Semczuk showed in his study on humans that sperm motility was decreased after 60 minutes from the application of propranolol and reported that increasing adverse effects were dose-dependent.<sup>21</sup> El-Sayed and colleagues searched the effect of oral beta-adrenergic receptor blockers on male fertility parameters. They gave oral metoprolol, propranolol, and atenolol to the rats for 60 days and measured testis, epididymis, seminal vesicle weight and sperm motility. They reported that atenolol did not affect testis, epididymis and seminal vesicle weight. After the last dose of drug application, they examined the sperm motility, and they also observed all three drugs reduced the percentage of sperm motility

progressively. Sperm head and tail anomalies were increased in all treatment groups. However, testosterone levels were decreased in rats applied beta-blockers, but this effect of beta-blockers decrease after 60 days from stopping the drug.<sup>22</sup> Martinez and colleagues demonstrated that application of propranolol intraperitoneally in male rats results with impaired testicular histology, necrosis and desquamation in germinal cells in seminiferous tubules.<sup>7</sup> Liaquat and colleagues reported that 1mg, 2mg, and 4mg propranolol was applied intraperitoneally during 60 days to 56 rats. Half of the experiments in every three groups were sacrificed on 60<sup>th</sup> days, and the remaining half were sustained for 60 more days. In their study, they did not find a significant difference between testicular weight, seminiferous tubules sizes, and the Leydig cells numbers, but on histopathological examination, in the group given 4mg propranolol, degeneration in the seminiferous tubules, necrosis, fibrinous material increase, hypocellularity in germinal epithelium and dystrophic calcification were observed.

They reported that histopathological changes were returned after stopping the drug.<sup>8</sup> Hassan and colleagues revealed beta-blockers-induced focal seminiferous tubular destruction, degeneration, necrosis and fibrinous material increase in the testis.<sup>23</sup> Razzak and colleagues investigated the effects of pindolol and propranolol on spermatogenesis in dogs and demonstrated that it had adverse effects on sperm motility and morphology. They considered that these effects of beta-blockers decreased insulin secretion from the beta cells in the islets of Langerhans and caused increased blood sugar levels.<sup>24</sup> Alexander considered that toxic effect of propranolol on spermatogenesis and sperm maturation was based on vasoconstriction in testicular vessels.<sup>25</sup> Suzuki and colleagues reported similar results that effect of atenolol on spermatogenesis.<sup>26</sup>

According to the data in the literature, beta-blockers have toxic effects on spermatogenesis and sperm maturation. It is considered that these effects are occurred by reduction of insulin secretion from the beta cells in the islets of Langerhans and vasoconstriction in testicular vessels. Additionally, there were studies showed that beta-blockers impaired sperm motility. It is revealed that propranolol damages to the germinal cells and causes defects in sperm head and tail. Similarly, studies on beta-blockers demonstrated the morphological deterioration on the structure of testis.

In this study, we investigated the histopathological effects of propranolol, metoprolol succinate and carvedilol in rat testis. Propranolol blocks  $\beta_1$ - $\beta_2$  receptors, metoprolol succinate, blocks  $\beta_1$  receptors, and carvedilol blocks  $\beta_1$ - $\beta_2$  and  $\alpha_1$  receptors. We observed that carvedilol decreased testicular weight in rats. While there were no differences in the group of propranolol regarding testicular weights, we observed deterioration in testicular morphology and germ cells. We detected adverse changes



in histopathological score according to Creasy's testis toxicity score. According to Creasy's testis toxicity score, in the group of metoprolol succinate, we demonstrated no significant changes in terms of morphology and weight. In the light of the data obtained, we consider that this adverse effect of beta-blockers on testis occurs via  $\beta_2$  receptors which carvedilol and propranolol block and metoprolol succinate do not.

There are certainly a few limitations that are worth noting with this study. The main limitation of our study is that this is a histopathological study. More assays such as MDA, GSH or SOD could be used to evaluate the oxidant and antioxidant effects and serum testosterone levels could be measured. Furthermore, the molecular mechanism of beta blockers need to be elucidated by further studies.

## CONCLUSION

Propranolol and metoprolol succinate caused no significant changes in rat testis weights. It was observed that carvedilol caused a decrease in the weight of the testis. Beta-1 selective metoprolol succinate did not cause significant deterioration in testicular histology. Propranolol and carvedilol caused significant deterioration in testicular histology, and it was considered that these effects occurred via  $\beta_2$  receptors. So, we consider that wide clinical use of adrenergic receptor blockers, especially Beta-blockers, may result in infertility in male, but these effect of drugs are reversible.

*Funding: No funding sources*

*Conflict of interest: None declared*

*Ethical approval: The study was approved by the Institutional Ethics Committee*

## REFERENCES

- Zhou Y, Xu M, Zhang Y, Guo Y, Zhang Y, He B. Effects of long-term application of metoprolol and propranolol in a rat model of smoking. *Clinical Experimental Pharmacology Physiology*. 2014;41(9):708-15.
- Moss HB, Procci WR. Sexual dysfunction associated with oral antihypertensive medication: a critical survey of the literature. *General hospital psychiatry*. 1982;4(2):121-9.
- Poloniecki J, Hamilton M. Subjective costs of antihypertensive treatment. *Human toxicology*. 1985;4(3):287-91.
- Croog SH, Levine S, Testa MA, Brown B, Bulpitt CJ, Jenkins CD, et al. The effects of antihypertensive therapy on the quality of life. *New Eng J Med*. 1986;314(26):1657-64.
- Heel R, Brogden R, Speight T, Avery G. Atenolol: A review of its pharmacological properties and therapeutic efficacy in angina pectoris and hypertension. *Drugs*. 1979;17(6):425-60.
- Mann KV, Abbott E, Gray J, Thiebaut H, Belzer Jr E. Sexual dysfunction with beta-blocker therapy: More common than we think? *Sexuality and disability*. 1982;5(2):67-77.
- Martinez D, Barthe D. Histological study of the action of propranolol on the genital tract of the male rat. *Acta anatomica*. 1980;109(4):346-54.
- Liaqat Ali AKN, Liaqat Ali M, Tahir M. Effects of the propranolol on morphology of adult rats testis. *Inter J Pathol*. 2008;6(1):19-22.
- Vidt DG. Contributing factors in resistant hypertension: truly refractory disease is rarely found in a properly conducted workup. *Postgraduate Med*. 2000;107(5):57-70.
- Barron AJ, Zaman N, Cole GD, Wensel R, Okonko DO, Francis DP. Systematic review of genuine versus spurious side-effects of beta-blockers in heart failure using placebo control: recommendations for patient information. *Inter J Cardiol*. 2013;168(4):3572-9.
- Leonetti G, Egan CG. Use of carvedilol in hypertension: an update. *Vasc Health Risk Manag*. 2012;8:307-22.
- Hayashi T, De Velasco MA, Saitou Y, Nose K, Nishioka T, Ishii T, Uemura H. Carvedilol protects tubular epithelial cells from ischemia-reperfusion injury by inhibiting oxidative stress. *Inter J Urol*. 2010;17(12):989-95.
- Yasar A, Erdemir F, Parlaktas BS, Atilgan D, Koseoglu RD, Saylan O, et al. The effect of carvedilol on serum and tissue oxidative stress parameters in partial ureteral obstruction induced rat model. *Kaohsiung J Med Sci*. 2013;29(1):19-25.
- Hayashi T, Saitou Y, Nose K, Nishioka T, Ishii T, Uemura H. Efficacy of carvedilol for ischemia/reperfusion-induced oxidative renal injury in rats. *Elsevier*. 2008;40(7):2139-41.
- Singh D, Chander V, Chopra K. Carvedilol attenuates ischemia-reperfusion-induced oxidative renal injury in rats. *Fundamental clinical Pharmacol*. 2004;18(6):627-634.
- Creasy DM. Evaluation of testicular toxicity in safety evaluation studies: the appropriate use of spermatogenic staging. *Toxicologic pathology*. 1997;25(2):119-31.
- Prichard B, Tomlinson B. The additional properties of beta adrenoceptor blocking drugs. *J Cardiovas Pharmacol*. 1986;8:S1.
- Morgan T. Clinical pharmacokinetics and pharmacodynamics of carvedilol. *Clinical pharmacokinetics*. 1994;26(5):335-46.
- McDevitt DG. Pharmacological Characteristics of [beta] Blockers and Their Role in Clinical Practice. *J cardiovascular pharmacology*. 1986;8:S5.
- Bandmann F. Weitere Beobachtungen über die Hodenfunktion nach lumbaler Grenzstrangresektion. *Brun's Beitr klin Chir*. 1950;181:419.
- Semczuk M. The Effects of  $\beta$ -adrenergic Drugs on the Human Sperm Motility in Vitro. I. The Effects

- of Propranolol and Isoprenaline. *Andrologia.* 1987;19(S1):256-61.
22. El-Sayed M, El-Sayed M, Elazab AeS, Hafeiz M, El-Komy A, Hassan E. Effects of some beta-adrenergic blockers on male fertility parameters in rats. *DTW Deutsche tierärztliche Wochenschrift.* 1998;105(1):10-2.
23. Hassan AB E-sM, Shkry IM, Mahdy MY. Effect of beta-adrenergic blocker on male rat fertility. *Proc VII Annual Conf Egypt Soc Pharmacol Expt Ther.* 1981.
24. Razzak MA. Beta-adrenergic blockade and blood sugar in dogs. *J Egypt Med Assoc.* 1976;59:65-75.
25. Alexander NJ. Animal models for research on contraception and fertility: proceedings of a Symposium on Animal Models for Research on Contraception and Fertility held at the National Academy of Sciences, Washington, DC, United States of America, sponsored by the Institute of Laboratory Animal Resources, Assembly of Life Sciences, National Research Council. Harper and Row;1979.
26. Suzuki H, Tominaga T, Kumagai H, Saruta T. Effects of first-line antihypertensive agents on sexual function and sex hormones. *J Hypertension.* 1988;6(4):S649-651.

**Cite this article as:** Eren H, Sivrikaya A, Cobanoglu U, Kalyoncu NI, Karaguzel E, Topbaş M, et al. Investigation the effect of propranolol, metoprolol and carvedilol on spermatogenesis in rat testis. *Int J Res Med Sci* 2018;6:1082-7.