

## Research Article

# Comparative study of modified open technique and closed technique for primary trocar insertion in laparoscopic surgery

Vikas Bathla\*, Pukur I. Thekdi, Pratik Koradia, Dushyantsinh Jhala, Udit Gadhvi

Department of General Surgery, C. U. Shah Medical College, Surendranagar, Gujarat, India

**Received:** 05 November 2015

**Accepted:** 17 December 2015

### \*Correspondence:

Dr. Vikas Bathla,

E-mail: [drvikasbathla@gmail.com](mailto:drvikasbathla@gmail.com)

**Copyright:** © the author(s), publisher and licensee Medip Academy. This is an open-access article distributed under the terms of the Creative Commons Attribution Non-Commercial License, which permits unrestricted non-commercial use, distribution, and reproduction in any medium, provided the original work is properly cited.

## ABSTRACT

**Background:** The objective of this study was to compare the safety and efficacy of modified open technique and closed technique for gaining entry [primary trocar insertion] and establishing pneumoperitoneum in laparoscopic surgery.

**Methods:** The present study was prospective, observational and longitudinal. Protocol of the procedure was formed along with Performa, Patient Information Sheet and Informed Consent Form. The present study was carried out in surgery department of C.U Shah medical college, Surendranagar, Gujarat state. The study was carried out from 1st October 2012 till 31st May 2014. A total of two hundred patients undergoing emergency and elective laparoscopic surgery were included in our study. Case records of patients was recorded in the Performa containing demographic details, size and site of trocar insertion, technique of trocar insertion, intraoperative, early postoperative and late post operative complications were noted.

**Results:** Total of 200 cases was included in our study. The age of patients ranges from 10-70 years. Out of 200 cases 90% were females suffering from different ailments and 105 were males in group A while in Group b 80% were females and 20% were males. In terms of on table complications; gastrointestinal injury is more in close method of trocar insertion.

**Conclusions:** We would advocate the modified open technique of trocar insertion as a technique of choice in primary trocar insertion as it is more efficacious and counts more on patient safety as compared to the close technique.

**Keywords:** Open access pneumoperitoneum, Laparoscopy, Modified open technique, Closed technique, Umbilical cicatrix pillar

## INTRODUCTION

Creating pneumoperitoneum is the first step in carrying out laparoscopic surgery for diagnostic and therapeutic purposes.<sup>1</sup> The establishment of pneumoperitoneum requires the introduction of a sharp insufflating needle or trocar. Peritoneal access and creation of pneumoperitoneum are key initial steps of laparoscopic surgery. Methods available for creating pneumoperitoneum and inserting the laparoscope at the beginning of laparoscopic procedure can be divided into open or closed entry technique.<sup>1</sup> There are five basic technique used to create pneumoperitoneum: blind veres

needle insertion, direct trocar insertion, optical trocar insertion, open method and modified open technique.<sup>1</sup> Most commonly used method of peritoneal access is blind insertion of veres needle through infra umbilical stab incision and then creating pneumoperitoneum.<sup>2,3</sup> Although it is safe method but outcomes of the studies have been found slightly increased complication because of its 'blind' nature. Another technique which is modification of open technique begins with small infra umbilical incision followed by gradual dissection exposing umbilical stalk (umbilical cicatrix pillar) and making a vertical incision at umbilical stalk and then insertion of Hassan's cannula or port under direct vision.<sup>4</sup>

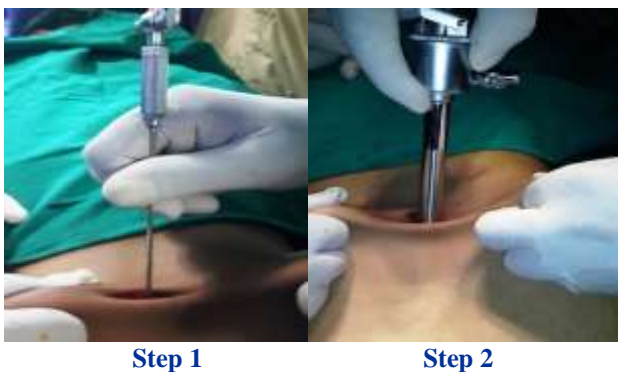
The objective of this study was to compare the safety and efficacy of modified open technique and blind verrees needle insertion techniques for gaining entry and establishing pneumoperitoneum.

## METHODS

The study was carried out in surgery department of C.U Shah Medical College, Surendranagar; Gujarat state from 1<sup>st</sup> October 2012 till 31<sup>st</sup> May 2014. The study was prospective, observational and longitudinal. Study protocol of the procedure was formed along with Performa, Patient Information Sheet and Informed Consent Form. All those patients who attended Surgery department of C U Shah Medical College for laparoscopic surgery (elective and emergency) were included in our study. Patient enrolled in study were all admitted patients of both genders requiring laparoscopic surgery. Females with third trimester pregnancy, patients with co morbid conditions like chronic liver disease, chronic renal failure, malignancy and those refused to be a part of study were excluded. Two hundred patients were selected on random basis for modified open and close method of trocar insertion. They were divided in two equal groups using ran.dom number table; Group A=Modified open technique and Group B=Closed technique using verrees needle insertion. Patients were assessed in the immediate postoperative period; six months and one year of discharge to assess for complications. The complications were graded on intra operative, early and late post operative complications.

### Comparison of two techniques

#### Closed technique



**Closed technique in laparoscopic surgery.**

#### Step 1:

With stab knife skin is incised just sub umbilical about 5 to 6 mm, then subcutaneous tissue bluntly dissected until the umbilical fascia is palpable the abdominal wall inferior to the umbilicus, then it lifted.

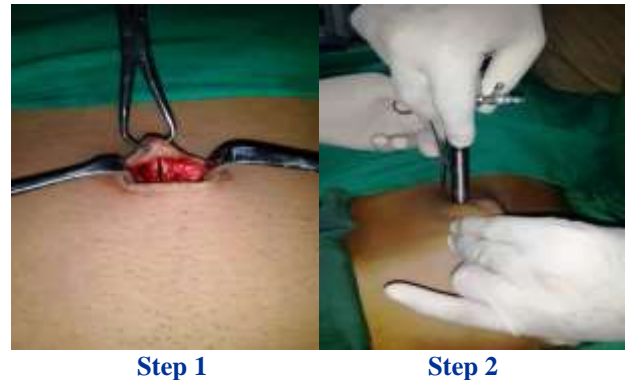
Lifting abdominal wall with one hand, while the verrees needle is in other hand and inserted through the fascia at

the base of the umbilicus at 45° angle toward the pelvis, so it prevent injury to aorta and inferior vena cava. Two clicks of the verrees needle will be appreciated as it penetrates first the umbilical fascia and then peritoneum.

#### Step 2:

Now pneumoperitoneum is created through Verres needle and 10 mm sharp trocar is inserted blindly.

#### Modified open technique



**Modified open technique in laparoscopic surgery.**

#### Step 1:

Umbilical cicatrix is grasped with Backhaus towel clip which everts the umbilicus as well as lifts the abdominal wall. One centimeter transverse infra umbilical incision is kept. Using a sharp mosquito forceps subcutaneous tissue is dissected to expose the umbilical cicatrix. Now a vertical incision is made over the umbilical cicatrix to enter the peritoneal cavity.

#### Step 2:

The entry wound is enlarged with a small or medium sized artery forceps. 10 mm port with blunt trocar is inserted under vision.

## RESULTS

**Table 1: Gender distribution in each group.**

Group	Females (%)	Males (%)
A	90	10
B	80	20

A total of 200 cases were included in the study. The age of the patient ranges from 10-70years. Regarding gender distribution 90% were females suffering from different ailment and 10%were males in group while in group B 80% were females and 20% were males (Table 1).

Out of 200 cases, the cases which underwent laparoscopic appendectomy were 26% in A group and

22.5% in group B and the cases who underwent laparoscopic cholecystectomy were 11% in group A and 11.5% in group B (Table 2).

**Table 2: Percentage of different cases in each group.**

Surgery	Group A	Group B
Laparoscopic appendectomy	51 / 25.5%	46/ 23%
Laparoscopic cholecystectomy	20/ 10%	25/12.5%
Diagnostic laparoscopy	21/10.5%	15/7.5%
Laparoscopic hernia (TAPP)	4/2%	11/5.5%
Laparoscopic varicelectomy	4/2%	01/0.5%
Laparoscopic hydatid cyst removal	0/0%	2/1%

On table complications like port site hematoma were 0.5% in group A and 2% in group B and gastrointestinal injury were 0% in group A and 1% in group B.

**Table 3: Percentage of on table complications in each group.**

Complication	Group A	Group B
Port site hematoma	01/0.5%	04/2%
Gastrointestinal injury	00	02/1%
Bladder injury	00	00
Laceration to solid organ	00	00
Major vascular injury	00	00

Post operative complications like subcutaneous emphysema ,port site wound infection and port site hernia were 0.5%,2%,0% in group A and 5%'7.5%,2% in group (Table 4).

**Table 4: The post operative complications in each group.**

Complications	Group A	Group B
Sub cutaneous emphysema	0.1/0.5%	10/5%
Pneumothorax	00	00
Pneumomediastinum	00	00
Port site wound infection	4/2%	15/7.5%
Port site hernia	00	4/2%

Wound infection was more common in closed technique. It was superficial and involved only skin and subcutaneous tissue. They resolve by antibiotics and anti inflammatory agent. It didn't require any surgical intervention.

## DISCUSSION

In the era of modern surgery, laparoscopic surgery has gained much popularity amongst the doctor as well as the

patients due its advantages like minimal access approach, shorter hospital stay, early return to daily activity and minimal post operative morbidity and good cosmesis. However, in laparoscopic surgery, adequate training and surgical expertise is a must. Primary trocar insertion is a crucial step in laparoscopic surgery.

Port placement and creation of pneumoperitoneum is the essential key step in laparoscopic surgery.<sup>4,6</sup> Most commonly it is performed by introducing verrees needle.<sup>7,8</sup> It is a safer technique but it is essentially a blind procedure. It is also associated with complications like bowel perforation, major vessels injury, subcutaneous emphysema, etc. Thus a proper technique of trocar insertion must be implemented. In our study we have compared the two basic techniques –MODIFIED OPEN and CLOSED; of primary trocar insertion.

In our study, most laparoscopic surgery were done on elective basis i.e. 65 (65%) and 35 (35%) procedure done on emergency basis, similar to study of String A, Berber E, Foroutani A, Macho JR, Pearl JM, Siperstein AE.<sup>9</sup> Most common provisional diagnosis was appendicitis and most common surgery performed was laparoscopic appendectomy 56 (56%), which was also documented by Harmeet Singh Rehan, Ashish Kumar Kakkar et al, (2010).<sup>10</sup>

There are two techniques of primary trocar insertion. Out of 200 patients, 100 patients were subjected to modified open trocar insertion technique and 100 patients were subjected to close trocar insertion technique. Though both modified open and close technique were commonly used according to surgeon preference, closed technique has known to have more complications as compared to modified open technique. This is similar to study done by Merlin TL, Hiller JE, Maddern GJ, Jamieson GG, Brown AR, Kolbe A(2003).<sup>11</sup>

Modified open technique comprises insertion of trocar in peritoneal cavity under vision, thus it is more advantageous in hands of inexperienced surgeon, in presence of intra abdominal adhesions and there are fewer chances of bowel and major vascular injuries. The appeal of entering the peritoneal cavity through a stab at the depth of umbilical cicatrix lies in its simplicity and relative safety and can be easily mastered<sup>12-15</sup> The success of this technique depends on identifying the umbilical cicatrix pillar and the junction of the pillar with linea alba<sup>16,17</sup>. After making a one cm vertical incision at the junction of umbilical cicatrix pillar with the linea alba is possible to have the peritoneal cavity opened.<sup>16,17</sup> The vertical incision at this point provides a rapid, safe and easy access to peritoneal cavity. This technique is safe, effective, easy to learn and quick to perform this technique clearly displays the point on the abdominal wall where the peritoneum is tightly fused and adherent to the peritoneal cavity in the majority of the cases, while the abdominal wall is kept away from the underlying viscera at all times using Backhaus towel clamp.<sup>16,17</sup> This

technique has been used for more than 1000 consecutive laparoscopic procedures over a period of four years and there was only one intraabdominal injury to the small bowel in a patient with multiple previous midline laprotomy and a prosthetic mesh closure in the study done by J. L. Antevil, S. Bhojru et al in 2005.<sup>16,17</sup> Similar technique has been described before and begins with infra umbilical skin incision and grasping the umbilical stalk at the depth of wound with an Alley's forceps.<sup>6,7,19</sup> Comparison between close and modified open techniques is inevitable, desirable, and essentially revolves around ease of execution and attendant complications.<sup>13</sup> Extensive meta analysis has shown that the modified open technique, on an average is associated with lower incidence of complications and is cheaper and faster than veress needle technique.<sup>20</sup>

## CONCLUSION

In the present study, we have compared the two technique of primary insertion of trocar and they are –

- Modified open technique
- Close technique

When we weighed the above two techniques on basis of various parameters like – patient safety, intra operative complications and post operative complications; we found that the modified open technique of trocar insertion was far better than the close technique, as it was done under direct vision. The most common dangerous complications of which surgeon is worried during the primary trocar insertion, like gastrointestinal perforation, major vascular injury and bladder perforation were very less rather nil as compared to the close technique of trocar insertion.

Hence, we would advocate that the modified open technique of trocar insertion as a technique of choice in primary trocar insertion as it counts more on patient safety as compared to the close technique.

*Funding: No funding sources*

*Conflict of interest: None declared*

*Ethical approval: The study was approved by the Institutional Ethics Committee*

## REFERENCES

1. Hamayun M, Saba N, Bilal M, Mehsud N. comparison of open versus closed pneumoperitoneum in laparoscopic surgery. Gomal J Med Sci. 2015;13:115-7.
2. Agresta F, DeSimon P, Gardo LF, Bedin N. Direct trocar insertion v/s veress needle in non obese patient undergoing laparoscopy procedure. Surgery Endosc. 18:1778-81.
3. Bernik Tr, Trocciola SM, Mayer DA, Patane J, Czura CJ, Wal- lack MK. Ball on blunt-tip trocar for laparoscopic cholecystectomy: improvement over the traditional Hasson and Veress needle methods. J Laparoendosc Adv SurgTech. 2001;11:73-8.
4. Bonjer HJ, Hazebroek EJ, Kazemier G, Giuffrida MC, Meijer WS, Lange JF. Open v/s closed establishment of pneumoperitoneum in laparoscopic surgery. Br J Surg. 1997; 84:599-602.
5. Merlin TL, Hiller JE, Maddern GJ, Jamieson GG, Brown Ar, Kolbe A. Systematic review of the safety and effectiveness of methods used to establish pneumoperitoneum in laparoscopic surgery. Br J Surg. 2003;90:668–79.
6. Pawanindra L, Sharma r, Chander J, ramteke VK. A technique for open trocar placement in laparoscopic surgery using the umbilical cicatrix tube. Surg Endosc. 2002;16:1366-70.
7. Carbonwill AM, Harold KL, Smith TI, Matther BD, Sing RF, Kercher KW et al. Umbilical stalk technique for establishing pneumoperitoneum. J Laproendosc Advan Surg Tech. 12(3):203-6.
8. Fitzgibbons RJ, Marsh RE. Method of creating a pneumoperitoneum. 2nd ed. Lipincott, Williams & Wilkins, Philadelphia. 2001:28-9.
9. String A, Berber E, Foroutani A, Macho JR, Pearl JM, Siperstein AE. Use of the optical access trocar for safe and rapid entry in various laparoscopic procedures. Surg Endosc. 2001;15(6):570-3.
10. Rehan HS, Kakkar AK. 2010.
11. Merlin TL, Hiller JE, Maddern GJ, Jamieson GG, Brown AR, Kolbe A. Systematic review of the safety and effectiveness of methods used to establish pneumoperitoneum in laparoscopic surgery. British Journal of Surgery. 2003;90(6):668-79.
12. Agresta F, DeSimon P, Gardo LF, Bedin N. Direct trochar insertin v/s veress needle in non obese patient undergoing laparoscopy procedure. Surgery Endosc. 18:1778-81.
13. Champault G, Cazacu F, Taffinder N. Serious trocar accidents in laparoscopic surgery: a French survey of 103852 operations. Surg Laparosc Endosc. 1996;6:367-70.
14. Cogliandodlo A, Manganaro T, Saitta FP, Micali B. Blind v/s open approach to laparoscopic cholecystectomy: a randomized study. Surg Laparosc Endosc. 1998;8:353-5.
15. Hurd WW, Randolph JF, Holmbergr A, Pearl ML, Hubbell GP. Open laparoscopy without special instruments or sutures, comparison with a closed technique. J Reprod Med. 1994;39:393–7.
16. Lal P, Vindal A, Sharma R, Chander J Ramteke VK. Safety of open technique for first trocar placement in laparoscopic surgery; a series of 6000 cases, Surgical Endoscopy. 2012;26(1):182-8.
17. Antevil JL, Bhojru S, Brusuo ME, Vierra MA, Swadia MD. safe and rapid laparoscopic access. A new approach. World Journal of Surgery. 2005;29(6):800-3.
18. Taro A, Mannino M, Cappello G, Di Stefano A, Di Carlo I. Comparison of two entry methods for laparoscopic port entry: Technical point of view.

Diagnostic and Therapeutic Endoscopy.  
2012;305428:7.

19. Vilos GA, Ternamian A, Dempster J, Laberge P. Laparoscopic entry: a review of technique, technology and complications. *J Obstet Gynecol.* 2001;29(5):433-65.
20. Gray's Anatomy 38th edition: umbilicus:850-1.

**Cite this article as:** Bathla V, Thekdi PI, Koradia P, Jhala D, Gadhvi U. Comparative study of modified open technique and closed technique for primary trocar insertion in laparoscopic surgery. *Int J Res Med Sci* 2016;4:160-4.