

Case Report

Metastases to the craniovertebral junction: illustrative case report and review of literature

Chandramouleeswaran Venkatraman*, Sindhuja Lakshminarasimhan, Pratheep Kumar S.,
Krishnaprasad Thuvrapalayam Periasamy

Institute of Neurology, Madras Medical College, Chennai, Tamilnadu, India

Received: 18 February 2018

Accepted: 29 March 2018

*Correspondence:

Dr. Chandramouleeswaran Venkatraman,
E-mail: drvcmdp@gmail.com

Copyright: © the author(s), publisher and licensee Medip Academy. This is an open-access article distributed under the terms of the Creative Commons Attribution Non-Commercial License, which permits unrestricted non-commercial use, distribution, and reproduction in any medium, provided the original work is properly cited.

ABSTRACT

Metastases at the craniovertebral junction represent 0.5-1% of spinal metastatic lesions. Common primary sites include breast, lung and prostate carcinoma. Initial presenting features include neck pain and occipital neuralgia. High index of suspicion is required to recognize this entity in patients presenting with neck pain. If left unrecognized, these metastatic lesions have the propensity to cause catastrophic collapse leading to significant morbidity and mortality due to fracture subluxation and spinal cord compression. Here we discuss such a patient who presented with acute onset quadriplegia and lower cranial nerve palsies due to metastatic lesion involving the C1 and C2 vertebra causing medullary and cervical cord compression. Early detection and timely intervention are key to improving outcomes in such patients.

Keywords: Craniovertebral junction, Quadriplegia, Metastases

INTRODUCTION

Craniovertebral junction anomalies usually result from congenital malformations such as an Arnold chiari or basilar invagination. Acquired causes of a craniovertebral junction compression are trauma, primary bony involvement or a cord tumor. After the lungs and liver, spine is the third most common site of metastases. Tumours of the cranio vertebral junction are defined by the anatomical involvement of occipital condyles and /or atlantoaxial spine.

The mean age of presentation in patients with metastases to upper cervical cord is 60 years. Metastasis involving the C1, C2 vertebrae is rare, with literature limited to few case reports and case series. Common primary sources include breast carcinoma, lung carcinoma and prostate carcinoma. Other less common primary sites include renal cell carcinoma, thyroid carcinoma, multiple myeloma and lymphoma. Tumours at the craniovertebral

junction may present with an indolent course causing neck pain and restricted neck movements.¹ Pain on flexion and extension of neck and occipital neuralgia are common symptoms. 90% of patients with craniovertebral junction disease have a rotational pain component.⁴ Occipital neuralgia is due to compression of C2 nerve root and it may be the presenting feature of craniovertebral junction in the absence neck pain. Up to 22% of patients develop myelopathy from spinal cord compression.⁴ When left unattended to, they have the potential to cause catastrophic collapse due to instability. MRI is the imaging modality of choice for diagnosis. CT scans can identify bony destruction and are used for surgical planning to look for spinal alignment. Nuclear studies such as FDG-PET and bone scan help to identify the source of the primary. Treatment modalities include surgery, radiotherapy and chemotherapy. Here we describe a patient with craniovertebral junction metastases who had an acute presentation and fulminant course.

CASE REPORT

A 55-year-old gentleman presented with four days history of weakness of both upper limbs and lower limbs with dysarthria and dysphagia for both solids and liquids. There was no bladder or bowel disturbance in the history. He had a prior history of neck pain and restriction of neck movements for four months for which he did not seek any medical attention. On examination he had spastic quadriparesis with muscle power of 3/5 in both upper and lower limbs in pyramidal pattern with exaggerated deep tendon reflexes and extensor plantar response bilaterally.

His higher mental functions, sensory system and cerebellum were normal. He had diffuse tongue wasting and tongue fasciculations with dysarthria for lingual and guttural words, deviation of uvula to the left, depressed gag reflex and restricted neck movements. His weakness was progressively worsening and within the next three days his power decreased to 1/5 in all 4 limbs with a single breath count of 8.

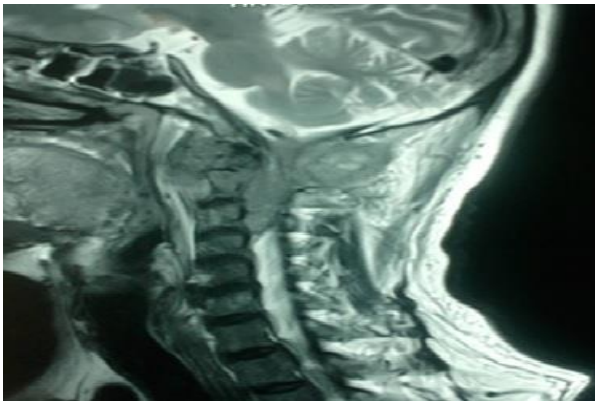


Figure 1: T2 sagittal view showing a heterogeneous mass lesion involving the C1 and C2 body with cord compression near the foramen magnum.

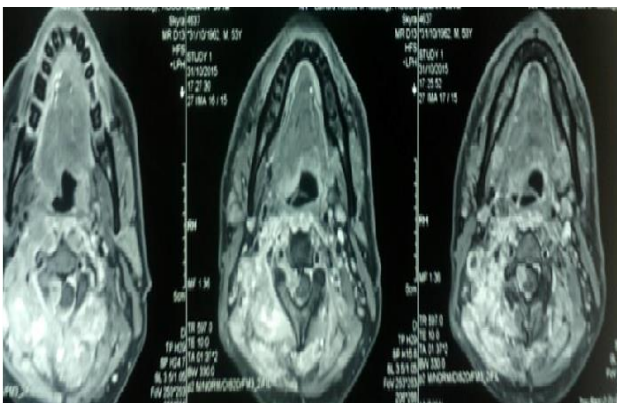


Figure 2: Axial cuts at the craniovertebral junction showing an extradural hyperintense mass extending like a dumbbell and causing compression.

He was initiated on mechanical ventilation. His MRI cervical spine showed a destructive lesion involving the C1, C2 vertebrae with compression of the cervical cord and medulla from the right side. T2 sagittal section (Figure 1) of the craniovertebral junction showed a hyperintense lesion involving the atlas and the axis with extradural compression of the cervical cord and medulla.

T2 axial sections (Figure 2) showed hyper intense lesion causing cord compression with right medullary compression and mass effect. Bedside chest x ray and ultrasonogram of abdomen and genitals was normal. He underwent decompressive surgery with craniovertebral stabilization.

Histopathology sent from the operated lesion was suggestive of metastasis from an adenocarcinoma. Further investigations to identify the primary could not be done due to sick condition of the patient. He succumbed to the illness on the fourth postoperative day due to sepsis.

DISCUSSION

Vertebral metastases result from hematogenous dissemination of metastatic cells from the primary tumour. The most common primary malignancies include lung, breast, prostate, thyroid, genitourinary and gastrointestinal malignancies.² Secondaries may be osteoblastic, osteolytic or mixture of both.³ The sites commonly involved in descending frequency are thoracic followed by lumbar and cervical spine. Craniovertebral junction metastases represent less than 1% of spinal metastases.⁴

They present with neck pain (on flexion, extension and rotation). Joint instability at this region leads to sudden worsening of symptoms and causes significant morbidity and mortality. MRI is the imaging modality of choice for both establishment of diagnosis and surgical planning. CT of the occipito cervical junction helps to look for the extent of bony destruction. Active search should be made to look for the primary malignancy.

Table 1 shows the available literature on craniovertebral junction metastases. Most common primaries in these studies were lung, breast, thyroid and prostate. Patients with normal spinal alignment can be treated with radiotherapy or stereotactic radiosurgery. Those with fracture subluxation more than 5mm or 3.5mm with 11-degree angulation require surgical management.^{4,5} Laminectomy for decompression is done for palliative surgery. Our patient had an acute presentation followed by rapid deterioration in the clinical course eventually leading to death. Early diagnosis and management is necessary to improve outcomes in such patients.

Table 1: Literature on craniovertebral junction metastases.

Authors	No. of patients with metastases	Study design
George et al ⁶	10 out of 41 patients had metastatic involvement of craniocervical junction (melanoma=2, breast=1, thyroid=2, lung=2, prostate=1, unknown=2)	Surgical management and results in bone tumours at cranio cervical junction
Xu et al ⁷	1 (case report)	Case report on atlanto occipital facet joint metastasis in non small cell lung carcinoma
Serban et al ⁸	17 (lung=6, breast=3, renal=2, others 3, unknown=3)	Therapeutic surgical approaches to upper cervical spine pathology
Ni et al ⁹	1 (case report)	Craniovertebral (C1) metastasis in lung adenocarcinoma
Baker et al ¹⁰	5 (breast=3, melanoma=1, unknown=1)	Stabilization of metastasis affecting second cervical vertebra
Azad et al ¹¹	25 (5 non small cell lung carcinoma, 1 lung adenocarcinoma, 5 breast carcinomas, 3 prostate carcinomas, 2 colorectal carcinoma, others 9)	Stereotactic radiosurgery for craniovertebral junction metastases to preserve spine stability and symptomatic relief

CONCLUSION

Metastatic lesions at craniovertebral junction are rare. High degree of clinical suspicion is necessary in patients presenting with neck pain and restricted neck movements for timely detection of metastasis and planning early intervention. If left unattended, they can cause potential life threatening situations as seen in our patient.

Funding: No funding sources

Conflict of interest: None declared

Ethical approval: Not required

REFERENCES

- Phillips E, Levine AM. Metastatic lesions of the upper cervical spine. *Spine (Phila Pa 1976)*. 1989;14:1071-7.
- Sundaresan N, Boriani S, Rothman A, Holtzman R. Tumors of the osseous spine. *J Neurooncol*. 2004;69:273-90.
- Guillevin R, Vallee JN, Lafitte F et-al. Spine metastasis imaging: review of the literature. *J Neuroradiol*. 2007;34:311-21.
- Moulding HD, Bilsky MH. Metastases to the craniovertebral junction. *Neurosurgery*. 2010;66:113-8.
- Nakamura M, Toyama Y, Suzuki N, Fujimura Y. Metastases to the upper cervical spine. *J Spinal Disord*. 1996;9:195-201.
- George B, Archilli M, Cornelius JF. Bone tumors at the cranio-cervical junction. Surgical management and results from a series of 41 cases. *Acta Neurochir (Wien)*. 2006;148:741-9.
- Xu R, Sciubba DM, Gokaslan ZL, Bydon A. Metastasis to the occipitocervical junction: A case report and review of the literature. *Surg Neurol Int*. 2010;31:1-16.
- Serban, N.A. Calina, Fl. Exergian, M. Podea, C. Zamfir, E. Morosanu, et al. The upper cervical spine tumor pathology C1-C2-therapeutic attitude. *Romanian Neurosurg*. 2012;XIX 4:251-63.
- Ni X, Wu P, Wu C, Wu J, Ji M, Gu X, Tian B. Treatment of cervical vertebral (C1) metastasis of lung cancer with radiotherapy: A case report. *Oncol Lett*. 2013;5:1129-32.
- Baker JF, Shafqat A, Devitt A, McCabe JP. Stabilization of metastatic lesions affecting the second cervical vertebra. *J Craniovertebr Junction Spine*. 2015;6:56-9.
- Azad TD, Esparza R, Chaudhary N, Chang SD. Stereotactic radiosurgery for metastasis to the craniovertebral junction preserves spine stability and offers symptomatic relief. *J Neurosurg Spine*. 2015;30:1-7.

Cite this article as: Venkatraman C, Lakshminarasimhan S, Kumar SK, Periasamy KT. Metastases to the craniovertebral junction: illustrative case report and review of literature. *Int J Res Med Sci* 2018;6:1825-7.