

## Original Research Article

# For investigate the role of ultrasound and platelets count as an important marker for the diagnosis and prognosis of dengue patients

Sunaina<sup>1</sup>, Vishal K. Desai<sup>2\*</sup>, Rahul Saini<sup>3</sup>, Rashmi Arora<sup>4</sup>

<sup>1</sup>Department of Radiology, University of Health Sciences, Rohtak, Haryana, India

<sup>2</sup>Department of Medicine, GAIMS, Bhuj, Gujarat, India

<sup>3</sup>Department of Pharmacology, BPS, GMC Khanpur Kalan, Sonapat, Haryana, India

<sup>4</sup>Department of Dermatology, GAIMS, Bhuj, Gujarat, India

**Received:** 03 March 2018

**Accepted:** 03 April 2018

### \*Correspondence:

Dr. Vishal K. Desai,

E-mail: [getdrvishal@yahoo.co.in](mailto:getdrvishal@yahoo.co.in)

**Copyright:** © the author(s), publisher and licensee Medip Academy. This is an open-access article distributed under the terms of the Creative Commons Attribution Non-Commercial License, which permits unrestricted non-commercial use, distribution, and reproduction in any medium, provided the original work is properly cited.

### ABSTRACT

**Background:** Dengue is although self limiting viral disease but if severe complications take place than it becomes lethal. Plasma leakage is main pathology which results in fluid deposits in various organs. This plasma leakage is related to platelet count. Most important thing in treating dengue patient is to know the complications at the earliest. And ultrasound is the most sensitive and easily approachable, cost effective investigation for detecting the complications.

**Methods:** This cross-sectional observational pilot study was carried out in the department of radiodiagnosis, pandit bhagwat dayal Sharma institute of medical sciences, Rohtak. One hundred and two patients with serologically confirmed dengue fever were included in this study. Ultrasound examinations were carried out by ultrasound machine with 5-13 MHZ probe by radiologists. Abdomen and thorax scanning were done thoroughly. Important findings like Gall bladder thickening hepatomegaly, splenomegaly, free fluid which are pathological markers for dengue were specially seen. Then these findings are relate to the age group and platelet count.

**Results:** By applying chi square test we found that there is statistically difference in number of patients in age group 16-30 yrs having gall bladder wall thickening, hepatomegaly, free fluid, splenomegaly and pleural effusion as compared to other age groups ( $p < 0.05$ ) an also in patients having less than 20,000 platelets, only gall bladder thickening, ascites and hepatomegaly were statistically more significant as compared to other groups having more number of platelets ( $p < 0.05$ ).

**Conclusions:** So, ultrasound and platelet count are important markers for diagnosis and prognosis of dengue patients. Ultrasound and Platelets count are important markers for the diagnosis as well as prognosis of dengue patients.

**Keywords:** Dengue, Platelets, Ultrasound

### INTRODUCTION

Dengue is the one of the most common rapidly spreading mosquito-borne viral disease in the world. This infection has been known to be endemic in many countries. Most of the patients having infection present with a self-

limiting febrile illness. But a small proportion of the patients develop severe complications. To identify such complications at the earliest is primary concern for physicians. Direct monitoring of pleural effusion and ascites with the help of chest X ray and ultrasound is beneficial in making diagnosis. Different tests like continuous hematocrit monitoring are used now a days to

know the hemo concentration which is a sign of plasma leakage, but due to subjective variations and time are the limitations of these test. Ultrasonography (USG) is a one of the easily available non-invasive imaging method for making the diagnosis and to know the complications in dengue infection. Due to its high sensitivity it can detect the small amount of pleural effusion and ascitis.<sup>1</sup> Recently many studies have shown that ultrasonography of the chest and abdomen are important investigations in making the diagnosis of dengue fever.<sup>2</sup> Specially in epidemic areas, for patients with suspected dengue fever, ultrasound is the best diagnostic approach to detect early signs.<sup>3</sup> Sonographic findings of dengue fever have been described in several previous studies. These include pleural effusion, ascites, gall bladder wall thickening, hepatomegaly, splenomegaly, pancreatic enlargement, pericholecystic fluid and pericardial effusion.<sup>4</sup> Authors performed this study to see the different ultrasound findings in the dengue patients which help in making the diagnosis and to access the severity of disease and to find their correlation with the platelet count at that time. So that platelet count can be used as prognostic markers in treatment of dengue patients.

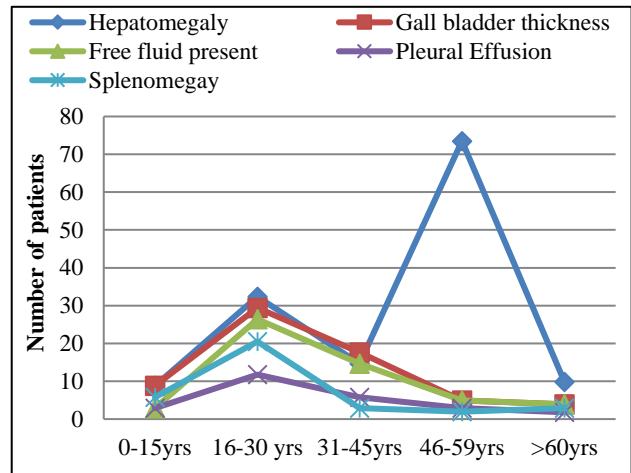
**METHODS**

This cross-sectional observational pilot study was carried out in the Department of Radiodiagnosis, Pandit Bhagwat Dayal Sharma Institute of Medical Sciences, Rohtak. One hundred and two patients with serologically confirmed dengue fever were included in this study. During the dengue season patients coming to the radiology department for various scanning were randomly selected for the study. All these patients were clinically and serologically evaluated. Diagnosis of dengue fever was made serogically by NSI-1 Ag test. Platelet count of the patients were also evaluated at the time of scanning to establish the relation between count and ultrasound findings. Ultrasound examinations were carried out by ultrasound machine with 5-13 MHZ probe by radiologists. Abdomen and thorax scanning were done thoroughly. Important findings like Gall bladder thickening hepatomegaly, splenomegaly, free fluid which are pathological markers for dengue were specially seen. Gall bladder thickening was measured by placing calipers between the two layers of anterior wall of abdomen. Thoracic cavity was approached through intercoastal approach in both sitting and standing position. Liver size more than 15cm was considers as hepatomegaly and for spleen 12cm was taken as splenomegaly.<sup>5</sup> Association of various sonographic findings with different age groups or platelet count were assessed by using Chi-square test of statistical significance. P≤0.05 was considered for statistical significance.

**RESULTS**

There is total no of 102 patients that were involved in the study. Out of these patients we divide these into five different age groups i.e <15 yrs,16-30 yrs, 31-45yrs, 46-

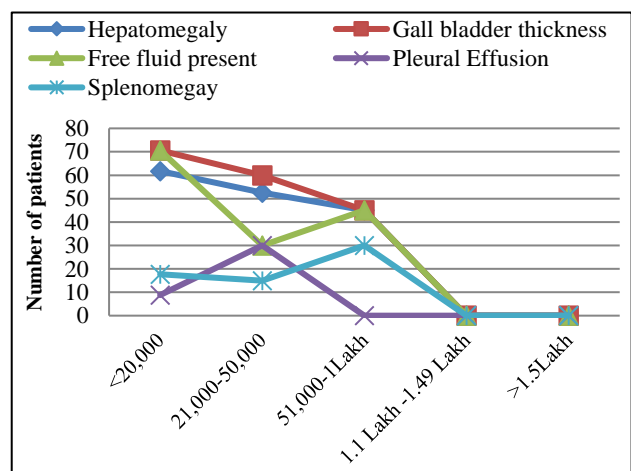
60 yrs, >60 yrs. The incidence of dengue fever was most commonly seen in patients of age group 16-30 yrs i.e. 38.2% and least commonly seen in age group 40-60 yrs of i.e 4.90% among all the groups (Figure 1).



**Figure 1: The ultrasound findings in relation to age and number of dengue patients.**

Hepatomegaly was found in 74.50% of patients and most commonly in age group 16-30 yrs i.e. 84.61% among all the groups. Gall bladder wall thickening was found in 64.70% of patients and most commonly in age group 31-45 yrs i.e. 76% among all the groups.

Free fluid was found in 53.92% of patients and age group 31-45 yrs were most commonly involved. Splenomegaly and pleural effusion were found in 34.31% and 24.50% of patients. In both 16-30 yrs of age group was most commonly involved. Only 7.84% of patients has no abnormal findings on ultrasound. There is statistically difference in number of patients in age group 16-30 yrs having gall bladder wall thickening, hepatomegaly, free fluid, splenomegaly and pleural effusion as compared to other age groups (p<0.05) (Figure 2).



**Figure 2: The ultrasound findings in relation to number of dengue patients and platelet count.**

In relations to the platelets patients having less than 20,000 platelets, gall bladder thickening and ascites is seen in 70.58% of patients, hepatomegaly in 61.76%, splenomegaly in 17.64%, pleural effusion in 8.82% of patients. In patients with platelet count 21000-50000 gall bladder thickening is more common finding in 60% as compared to other findings like hepatomegaly 52.5% ascites 30% pleural effusion 30%, splenomegaly 15%. In eight patients whose platelet count were above 1.1 lakh ultrasound findings were normal. In patients having less than 20,000 platelets, only gall bladder thickening, ascites and hepatomegaly were statistically more significant as compared to other groups having more number of platelets. ( $p < 0.05$ ) (Figure 2). So as the number of platelets decrease the chance of finding abnormal findings increase and vice versa.

## DISCUSSION

The use of ultrasound in the dengue patient is very informative. The diagnosis can be made early in the course of disease with the help of USG. Specially in epidemics physicians are able to know the complications in dengue infection at the earliest and treatment can be started soon. This result in decrease in overall cost and time period of the disease along with the reduction in morbidity and mortality. Thulkar et al, have also done study pertaining to the ultrasound findings in dengue patients, in that the found pleural effusion in the 55% of patients, thickening of gall bladder wall in 43% and free fluid in 15%.<sup>6</sup> In contrast to that in this study hepatomegaly (74.50%) was commonest finding followed by gall bladder thickening (64.70%), presence of free fluid (53.92%) and splenomegaly (34.31%). Setiawan et al, shows that increased gall bladder thickening associated with increased severity of disease.<sup>6</sup> Pleural effusion was most common finding in a study by Joshi et al, (66%) followed by ascites and gall bladder wall thickening was most commonly finding by santhosh et al, (66.7%) followed by ascites.<sup>7,8</sup> Venkata Sai et al, had found in his study that GB wall thickening as the initial finding (100%) followed by pleural effusion.<sup>1</sup> Sudhir Sachar et al, had also done a study on 20 patients with dengue fever and ultrasound features included in his study were thickened GB wall in all (100%) patients, ascites in 15 patients (75%), splenomegaly in 8 patients (40%), and pleural effusion in 14 patients (70%).<sup>9</sup> Another authors Asghar J et al, and Chandak S et al, have found in their studies, hepatomegaly and splenomegaly as most common findings.<sup>10,11</sup> The above variations may be due to the difference in sample size and quality. Mainly we know the main pathology in dengue fever is the plasma leakage which may vary from organ to organ and person to person.

The decrease or increase in number of platelet count can be directly related to the severity of disease. As seen in results as the number of platelets decrease the various finding like gall bladder wall thickening, hepatomegaly, splenomegaly, pleural effusion are increased in patients

and vice versa. And even recovering patients having platelet count above one lakh have normal ultrasound findings. Similarly in a study by Santhosh et al, in platelet count less than 40,000, gall bladder wall thickening was seen in 97.8% along with ascites (86.9%) and pleural effusion (58.6%). In patients with platelet count between 40,000 and 80,000 ascites was more common than edematous GB wall thickening. Significantly no abnormal sonographic finding was detected in patient with platelet count more than 150,000.

## CONCLUSION

Our study has shown that of ultrasound and platelets count are important markers for the diagnosis as well as prognosis of dengue patients. Ultrasound no doubt by saving time, cost and decreasing morbidity and mortality is now a day a mandatory investigation in dengue patients. And as seen in this study and previous studies platelet count can be correlated with the severity of disease, So these can be important diagnostic as well as prognostic marker for the disease.

*Funding: No funding sources*

*Conflict of interest: None declared*

*Ethical approval: The study was approved by the Institutional Ethics Committee*

## REFERENCES

1. Venkata Sai PM, Dev B, Krishnan R. Role of ultrasound in dengue fever. *Br J Radiol.* 2005;78:416-8.
2. Sai PMV, Dev B, Krishnan R. Role of ultrasound in dengue fever. *British Journal of Radiolog.* 2005;78:416-8.
3. Wu KL, Changchien CS, Kuo CH, Chiu KW, Lu SN, Kuo CM, et al. Early abdominal sonographic findings in patients with dengue fever. *Journal of Clinical Ultrasound.* 2004 Oct 1;32(8):386-8.
4. Thulkar S, Sharma S, Srivastava DN, Sharma SK, Berry M, Pandey RM. Sonographic findings in grade III dengue hemorrhagic fever in adults. *Journal of clinical ultrasound.* 2000 Jan 1;28(1):34-7.
5. Konuş OL, Ozdemir A, Akkaya A, Erbaş G, Celik H, Işık S. Normal liver, spleen, and kidney dimensions in neonates, infants, and children: Evaluation with sonography. *AJR Am J Roentgenol.* 1998;171:1693-8.
6. Setiawan MW, Samsi TK, Pool TN, Sugianto D, Wulur H. Gallbladder wall thickening in dengue haemorrhagic fever: an ultrasonographic study. *J Clin Ultrasound.* 1995;23(6):357-62.
7. Joshi V, Mourya DT, Sharma RC. Persistence of Dengue-3 virus through transovarial passage in successive generations of *Aedes aegypti* mosquitoes. *American Journal of Tropical Medicine and Hygiene.* 2002;67(2):158-61.

8. VR Santhosh, Patil PG, Srinath MG, Kumar A, Jain A, Archana M. Sonography in the Diagnosis and Assessment of Dengue Fever. *J Clin Imaging Sci.* 2014;4:14.
9. Sachar S, Goyal S, Sacha S. Role of Ultrasonography (Honeycomb Sign) in Early Detection of Dengue Hemorrhagic Fever. *Arch Clin Exp Surg.* 2013;2(1):38-42.
10. Asghar J, Farooq K. Radiological appearance and their significance in the management of dengue hemorrhagic fever. *Pak J Med Health Sci.* 2011;5:685-92.
11. Chandak S, Kumar A. Can radiology play a role in early diagnosis of dengue fever? *North Am J Med Sci.* 2016;8:100-05.

**Cite this article as:** Sunaina, Desai VK, Saini R, Arora R. For investigate the role of ultrasound and platelets count as an important marker for the diagnosis and prognosis of dengue patients. *Int J Res Med Sci* 2018;6:1734-7.