

Case Report

Successful management of severe acute respiratory distress syndrome caused by H1N1 viral pneumonia using early institution of extra corporeal membrane oxygenation therapy

Rajesh S. Taneja¹, Ruchi Kapoor², Ramesh Kashav², Ramadoss Ramu^{1*}

¹Department of Medicine, ²Department of Anaesthesia, PGIMER and Dr. RML Hospital, New Delhi, India

Received: 09 March 2018

Accepted: 03 April 2018

***Correspondence:**

Dr. Ramadoss Ramu,

E-mail: ramadoss2912@gmail.com

Copyright: © the author(s), publisher and licensee Medip Academy. This is an open-access article distributed under the terms of the Creative Commons Attribution Non-Commercial License, which permits unrestricted non-commercial use, distribution, and reproduction in any medium, provided the original work is properly cited.

ABSTRACT

Swine flu is H1N1 influenza A virus infection that has serious consequences in susceptible individuals leading to acute respiratory distress syndrome (ARDS). Sometimes ARDS can be refractory to conventional management and ventilator strategies. In such patients Extracorporeal Membrane Oxygenation (ECMO) improves respiratory functions wherein the gas exchange is done via a membrane oxygenator and a pump. We report a case of 50 years old female presented in February 2016 with complaints of fever, headache, dry cough, rhinorrhea and difficulty in breathing for four days. Her throat swab showed positive report for H1N1 infection. She developed severe ARDS due to pneumonia caused by H1N1 influenza infection. Her paO_2/FiO_2 was less than 100. The patient did not respond to initial management with anti- influenza therapy and mechanical ventilation. Murray score was calculated to institute ECMO therapy. Murray score of our patient was 2.75. Since there was no co- morbid illness or irreversible lung disease, ECMO therapy was started. After 14 days of ECMO therapy, ARDS resolved and the patient was successfully weaned from the ventilator. Patient was monitored intensively for coagulopathies and other complications related to ECMO therapy. She developed hemothorax and critical illness neuropathy during ECMO therapy. ECMO is a salvage therapy that has the potential to save lives when conventional treatment fails in H1N1 associated ARDS. It not only ensures much needed lung protection to the inflamed lung but also provides better hemodynamic stability. Early institution of ECMO along with ultra-protective ventilation of lung and timed weaning is the key to successful management of severe ARDS due to swine flu. There are very few case reports of successful ECMO therapy in H1N1 associated ARDS available from Delhi.

Keywords: ARDS, ECMO, H1N1 influenza, Murray score, Swine flu

INTRODUCTION

Swine-originated H1N1 influenza virus causes acute respiratory illness in humans from 2009.¹ H1N1 influenza virus was given importance because of its higher case fatality among young population and potential to cause ARDS due to swine flu progresses rapidly and the refractory hypoxemia leads to severe sepsis causing multi organ failure.² Therefore prompt intervention has to be done to improve the oxygenation in such patients.

Extracorporeal membrane oxygenation is a mechanical assist therapy wherein extracorporeal blood circuit that includes an oxygenator and a pump is used to support the respiratory function thereby preventing hypoxemia.³ Thus ECMO is a supportive therapy that replaces the lung function thereby allows the lung to recover from the acute insult or ARDS.

We report a case of severe ARDS secondary to H1N1 viral pneumonia who did not respond to conventional

therapy and was treated successfully with ECMO therapy. Case reports of successful ECMO therapy in H1N1 associated ARDS from Delhi are very few.

CASE REPORT

A 50-year-old lady presented to our hospital in February 2016 with complaints of fever, headache, dry cough, rhinorrhea and difficulty in breathing for four days. Earlier, the patient was seen at a private hospital where throat swab test for H1N1 influenza virus was found to be positive with RT-PCR method. On arrival, the patient was conscious, oriented, restless with respiratory rate of 45/minute; pulse rate of 110/minute; BP of 126/70mmHg, SpO₂ -76% on room air and 85% on non-rebreathing mask. Auscultation revealed coarse crackles over bilateral infra scapular regions. Rest of the examination was normal.

The patient was started on inhaled oxygen in propped up position and capsule Oseltamivir 150 mg twice daily. Investigations showed Hemoglobin of 10.5g/dl, total leukocyte count of 4200/mm³, platelet count of 1.5lakhs/mm³. Chest radiography revealed bilateral lower zone infiltrates (Figure 1). Arterial blood gas (ABG) analysis showed partial oxygen pressure of 55mmHg, oxygen saturation of 88% and PaO₂/FiO₂-108. She was nebulized; still respiratory rate was 30/minute with heart rate of 130/minute.

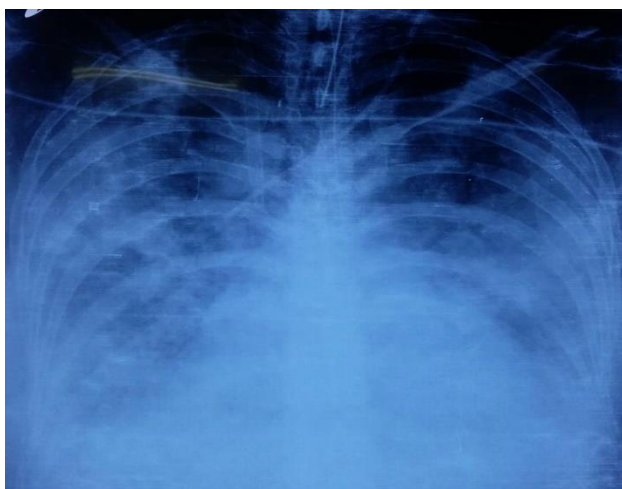


Figure 1: Chest radiograph on day 1 showing non-homogeneous opacities in bilateral lung fields.

Thereafter she was intubated and put on pressure regulated volume control mode of ventilation. She was put on Vecuronium infusion and central venous cannulation was done. On 2nd day of mechanical ventilation her peak airway pressure showed surges. So, lung protective strategies of low tidal volume (6ml per kg), inverse ratio ventilation were initiated. In spite of that, there was marginal improvement in PaO₂. Positive End Expiratory Pressure had to be increased to 10mm of Hg even on 3rd day of ventilation. But there was no

improvement in her partial pressure of oxygen and her paO₂/FiO₂ ratio which continued to be at 100. Her Mean arterial pressure dropped to 50mm Hg despite CVP of 10 cmH₂O so that noradrenaline infusion was started. On day 4, her FiO₂ had to be increased to 80%. But her paO₂/FiO₂ was less than 100. On day 5, her peak airway pressures surged.

Murray score was calculated which is used to decide the use of ECMO in management of ARDS. Parameters used in Murray score calculation were PEEP-8cmH₂O, Compliance-16ml/cmH₂O, chest radiograph-2 quadrants involved and PaO₂/FiO₂ -99. Murray score of our patient was 2.75. Since her clinical condition was continuously deteriorating, it was decided to institute ECMO therapy to manage ARDS. Venous cannulation of right sided internal jugular and right femoral vein was done under echocardiography guidance and the patient was put on veno-venous extracorporeal membrane oxygenator with pump. Left sided IJV was secured for intravenous access and to monitor CVP, hourly arterial blood gas analysis with a close watch on ScvO₂ was done to maintain tissue oxygenation. Beat to beat arterial blood pressure monitoring, coagulation profile, platelet count and remaining aspects of critical care like nutrition, hemodynamic were maintained. Chest radiograph was done daily, coagulation profile 12hrly, Blood and blood products were transfused with a target INR of 1.5 and platelet above 50,000 to prevent bleeding. Table 1 shows the various significant parameters and major events happened during ECMO therapy.

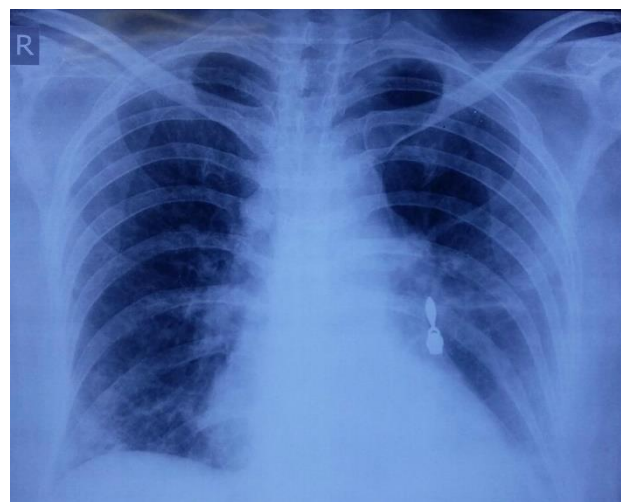


Figure 2: Chest radiograph on discharge showing infiltrates in left lower zone.

On 14th day of ECMO, after the insertion of ICD, her lung fields were clear and her ventilator support was stepped up. Tidal volume was increased to 7ml per kg. On day 15, patient was put on SIMV Mode and tidal volume was increased to 8ml per kg body weight. Progressive weaning from ECMO was done. FiO₂ was also reduced to 30 per cent and patient was observed for six hours. Then de-cannulation was done. Thereafter

patient was progressively weaned from ventilator and she was extubated after 5 days of de-cannulation. Later she

was put on noninvasive BiPAP ventilation. She was given good physiotherapy.

Table 1: Important ventilator parameters and significant events during ECMO therapy.

ECMO Dayx	SpO ₂	PaO ₂ (mmHg)	P plat (cm H ₂ O)	TV (ml/kg)	RR (per min)	PEEP (cmH ₂ O)	Events
1	88-90	42	35	4	8	10	Stable on Noradrenaline
2	<90	55	32	4	8	10	Stable on noradrenaline
3	90	60	32	4	8	10	Stable. noradrenaline discontinued
4-6	90	60	25	4	8	10	Off inotropes
7-8	90	60	21-22	5	8	10	Stable vitals
9	91-92	65	21-23	6	8	8	Stable vitals
10	90-92	65	22-23	7	8	8	Stable vitals
11	91-92	65	30-32	6	10	8	Collapse suspected
12	90	60	28-30	6	10	8	Fiber optic bronchoscopy done. Mucus plugs removed.
13	91-92	75	26-28	6	8	8	Pleural effusion on chest X-ray. ICD placed. 1.5 L hemorrhagic fluid drained
14	92-94	90	22-23	7	12	8	Weaning from ECMO initiated

After weaning, it was noticed that the patient had weakness in bilateral lower limbs. Nerve conduction study showed critical illness axonal neuropathy for which physiotherapy was advised. Power in lower limbs improved gradually and the patient was discharged after 6 weeks of hospital stay. Chest radiograph at the time of discharge showed resolution of the infiltrates (Figure 2). The patient continues to do well on follow up.

DISCUSSION

Infection with H1N1 virus causes a broad spectrum of clinical syndromes ranging from afebrile upper respiratory tract infection to ARDS.¹ Cornerstones of management of ARDS are treating the underlying condition and providing support for affected systems. Most patients with ARDS require early intubation and mechanical ventilation. A lung-protective ventilator support strategy of low tidal volume and high PEEP settings is used to achieve oxygenation goals.⁴ Our patient also presented with short history of fever with respiratory symptoms, but her condition deteriorated progressively and she developed ARDS.

ECMO is a technique wherein a specific heart lung machine is used to provide gas exchange in severe respiratory failure or cardiac failure or both. ECMO helps in salvaging patients with ARDS who do not show improvement with conventional therapy. In ECMO system, there is an extracorporeal blood circuit including an oxygenator and a pump. There are two types of ECMO namely veno-venous and veno-arterial depending on the input and output conduits connected to the circuit

respectively. The former provides only gas exchange and hence used in respiratory failure whereas the latter provides additional cardiac support.³

The swine flu pandemic in the year 2009 evoked renewed interest in the use of ECMO as trials in various parts of the world showed a definitive role of ECMO in the management of ARDS complicating H1N1 virus infection. CESAR trial is one such trial wherein it was found that ECMO has a definitive role in salvaging a patient of ARDS complicating swine flu.⁵ The role of ECMO in H1N1 infection related ARDS was studied in Australia and New Zealand by Davies et al.⁶ They reported a survival rate of 71% for patients with a mean age of 34.4 years and Murray score of 3.8 who were on ventilation for 2 days before ECMO.

The decision to institute ECMO is a crucial one considering the fact that the patient is subjected to the therapy that is invasive, prolonged, requires intensive monitoring and may cause morbidity to the patient. Murray devised an acute lung injury score based on hypoxemia, lung compliance, peak airway pressures and chest radiography, this score was used when we decided to institute ECMO in this patient.⁷ ECMO can be considered if Murray score is 2-3 and it is indicated if the score is 3-4.⁸ For our patient, the score was 2.75. So, we considered ECMO therapy.

There are certain contraindications to the use of ECMO such as irreversible lung injury, intra cerebral infarction, intracranial bleed and mechanical ventilation at high settings for more than 7 days. Therefore, early and

judicious decision weighing the risk benefit ratio is to be made before instituting ECMO therapy.⁸

While the patient is on ECMO continuous anticoagulants such as heparin are used which requires continuous monitoring of both APTT and platelet count and therefore transfusion of blood and blood products has to be done to avoid any intracranial bleeding during the procedure. The target ACT, INR and Platelet count are 150-180 seconds, 1.5 and 1 Lakh, respectively. Sedation, nutrition and remaining protocols of intensive care and management of cause of ARDS should be done simultaneously.⁸ All of these protocols were followed during the management of our patient.

While the patient is on ECMO ultra protective lung ventilation to be done with a careful watch on mixed venous oxygen saturation, peak airway pressure, plateau pressures and lung compliance. The patient is ventilated at tidal volumes as low as 3 to 4ml/kg titrated with the peak pressure.⁹ In our patient, tidal volume was kept at 4ml/kg till the compliance and airway pressures settled.

ECMO is associated with complications such as mechanical complications like circuit problems or medical complications like bleeding, infection, embolism causing ischemia and neurologic complications.⁸ Careful monitoring and correcting coagulopathy prevented any complication in our patient. Bleeding (hemothorax) was due to thrombocytopenia or deranged coagulation which could be worsened due to heparin. Therefore, serial monitoring of coagulation parameters and correction is advocated.

Weaning from ECMO is very challenging because the patients are variably on prolonged sedation for many days.¹⁰ Weaning should be tried after the patient has improved sufficiently with ventilator settings such as $FiO_2 < 0.4$, peak inspiratory pressure < 25 , stable breathing pattern and respiratory rate ≤ 30 /min.⁴ Therefore weaning needs to be individualized based on broad guidelines along with the patient's clinical condition. Generally, patients are progressively weaned from ventilator while on ECMO.

Whereas in our patient sedation and neuromuscular blocking agents had to be administered for prolonged period. Therefore, while she was kept on SIMV mode of ventilation, weaning from ECMO was planned. Later, weaning from ventilation was done. Thus, clinical judgment need to be exercised during weaning from ECMO.

If the patient has irreversible lung damage or severe brain damage with no chance of recovery, cessation of ECMO should be considered.³ Period for which ECMO can be continued is unknown and some reports show successful outcome by using ECMO even for more than one month.¹¹

CONCLUSION

ECMO is a salvage therapy that has the potential to save lives when conventional treatment fails in H1N1 associated ARDS. It not only ensures much needed lung protection to the inflamed lung but also provides better hemodynamic stability. Early institution of ECMO along with ultra-protective ventilation of lung and timed weaning is the key to successful management of severe ARDS due to swine flu.

ACKNOWLEDGEMENTS

Authors would like to thank Dr. Vivek Arya, Professor of Medicine, PGIMER and Dr. RML Hospital for his help in editing the manuscript.

Funding: No funding sources

Conflict of interest: None declared

Ethical approval: Not required

REFERENCES

1. Writing Committee of the WHO Consultation on Clinical Aspects of Pandemic (H1N1) 2009 Influenza. Clinical Aspects of Pandemic 2009 Influenza A (H1N1) Virus Infection. N Engl J Med. 2010;362:1708-19.
2. Jaber S, Conseil M, Coisel Y, Jung B, Chanques G. ARDS and influenza A (H1N1): patients' characteristics and management in intensive care unit. A literature review. In Annales francaises d'anesthesie et de reanimation 2010;29(2):117-125.
3. Aokage T, Palmér K, Ichiba S, Takeda S. Extracorporeal membrane oxygenation for acute respiratory distress syndrome. Journal of intensive care. 2015 Dec;3(1):17.
4. Rotta AT, Kunrath CL, Wiryawan B. Management of the acute respiratory distress syndrome. J Pediatr (Rio J) 2003;79(Suppl 2):S149-S60.
5. Peek GJ, Mugford M, Tiruvoipati R, Wilson A, Allen E, Thalanany MM, et al. Efficacy and economic assessment of conventional ventilatory support versus extracorporeal membrane oxygenation for severe adult respiratory failure (CESAR): a multicentre randomised controlled trial. Lancet (London, England). 2009 Oct 17;374(9698):1351-63.
6. APRIL I. Extracorporeal membrane oxygenation for 2009 influenza A (H1N1) acute respiratory distress syndrome. Jama. 2009;302(17):1888-95.
7. Murray JF, Matthay MA, Luce JM, Flick MR. An expanded definition of the adult respiratory distress syndrome. Am Rev Respir Dis. 1988 Sep 1;138(3):720-3.
8. Extracorporeal Life Support Organization (ELSO). Guidelines for Adult Respiratory Failure. Available at: https://www.else.org/Portals/0/ELSO%20Guidelines%20For%20Adult%20Respiratory%20Failure%201_4.pdf. Accessed on 21 January 2018.

9. Marhong JD, Telesnicki T, Munshi L, Del Sorbo L, Detsky M, Fan E. Mechanical ventilation during extracorporeal membrane oxygenation. An international survey. *Annals of the American Thoracic Society.* 2014 Jul;11(6):956-61.
10. Grasselli G, Mangili P, Sosio S, Patroniti N. Weaning from VV ECMO. In *ECMO-Extracorporeal Life Support in Adults 2014* (pp. 317-323). Springer, Milano.
11. Wang CH, Chou CC, Ko WJ, Lee YC. Rescue a drowning patient by prolonged extracorporeal

membrane oxygenation support for 117 days. *The American journal of emergency medicine.* 2010 Jul 1;28(6):750-e5.

Cite this article as: Taneja RS, Kapoor R, Kashav R, Ramu R. Successful management of severe acute respiratory distress syndrome caused by H1N1 viral pneumonia using early institution of extra corporeal membrane oxygenation therapy. *Int J Res Med Sci* 2018;6:1836-40.