

Case Report

Rare defect at superior helix as morphological variation of right auricle

Mauritius Lambertus Edy Parwanto*

Department of Biology, Faculty of Medicine, University of Trisakti, Indonesia

Received: 25 March 2018

Revised: 16 April 2018

Accepted: 20 April 2018

*Correspondence:

Dr. Mauritius Lambertus Edy Parwanto,
E-mail: edyparwanto@trisakti.ac.id

Copyright: © the author(s), publisher and licensee Medip Academy. This is an open-access article distributed under the terms of the Creative Commons Attribution Non-Commercial License, which permits unrestricted non-commercial use, distribution, and reproduction in any medium, provided the original work is properly cited.

ABSTRACT

Auricle is the part of external ear. Morphological appearance and biometric of auricle are influenced by genetic and environmental factors. Base on the fact that morphological appearance and biometric of auricle vary in different human ethnic races. Normal of auricle have complete component with normal of dimension and appearance. Population studies show the different of morphological and biometric of auricle. Generally, the right and left auricles in the individual is symmetrical in both size and appearance. We reported about defect at superior helix of right auricle. In this case it shows that right and left auricles have complete components. The biometric comparison of right and left auricles showed equal or not significant different. Defect of right auricle at superior helix were indentation as morphological variation.

Keywords: Auricle, Morphological defect, Superior helix

INTRODUCTION

The human ear is divided into 3 parts, namely outer, middle and inner parts. The human auricle is part of the outer ear. Morphologically, the outer ear consists of three main components that are the helical complexes, the shell complex, and the lobe.¹ Generally, the human auricle consists of helix, anti-helix, tragus, anti-tragus, concha, lobe, scapha and triangular fossa.

The morphological appearance and biometric of auricle vary in different human ethnic races.² Moreover, the characteristic of morphological appearance and biometric of auricle in individual are influenced by genetic and environment factors.^{3,4} Because that, of course that the shape, size and orientation of each auricle in individual is specific and associate with genetic and or environment factors. With regard to auricle size, length and width of the auricle increase with age. The increase in length and width of the auricle occurs from birth to the age of 99

years in female, but for males it stopped around age of 50-70 years.⁵

Base on the fact that there was a variety of morphological and biometric appearance of human auricle. There are individuals who have a right and left auricles with morphological and biometric in the normal size, but there are also individuals who have one or both auricles with morphological and biometric in the abnormal size. Auricle is one of five main characteristics of the human face and is very influential in determining its appearance.⁶ Type of external ear malformations that affect to the facial appearance can be found, among others in oculo-auriculo-vertebral spectrum patients ranged from slightly dysmorphic to absent ears (or anotia: the most severe form of microtia).⁷

The incidence of outer ear malformation has been reported at 1: 6830.⁸ Previous studies have shown that auricle morphological defects are caused by congenital

malformations and or external factors such as trauma, burns, tumors, punctured defects, scars, and inflammation/allergies.⁴ More over that congenital defect of auricle show varying degrees, and is more commonly unilateral than bilateral, more effecting on the right ear than left ear and occurs in males more than females.⁹ Certainly, the consequences of congenital defect will affect the morphological variation in the individual. In this case, we reported about defect at superior helix of right auricle on Indonesian men.

CASE REPORT

Table 1: Anatomical landmarks of ear biometrics.

Anatomical landmarks of ear biometrics	Left auricle	Right auricle
1. Total Ear Length (TEL): the distance between superior most pinna point to inferior most point of lobule (mm).	73.23	73.01
2. Ear length above tragus (ELAT): distance between superior point of ear to tragion (mm).	33.14	32.69
3. Ear length below tragus (ELBT): distance between intertragic incisure to lower most lobule point (mm).	22.76	23.12
4. Tragus length (TL): distance between tragion to intertragic incisures (mm).	24.14	24.16
5. Ear breadth (EB): distance between maximum convexity of the helix and the root of ear (mm).	27.21	27.26
6. Concha length (CL): distance between intertragic incisures and cymba concha (mm).	38.17	38.24
7. Concha breadth (CB): distance between maximum concavity of the anti-helix and posterior margin of tragus (mm).	22.11	21.85
8. Lobule height (LH): distance between inferior most point of external ear attachment head up to the free margins of ear lobe (mm).	08.26	08.28
9. Lobule width (LW): distance between outermost maximum transverse width of ear lobule and caudal most attachment of ear lobule (mm)	23.42	23.37
10. Ear index (EI): (ear breadth: total ear lenght) x 100	37.15	37.33
11. Lobule index (LI): (lobule width: lobule height) x 100	283.53	282.24

Abbreviations: mm= millimetres

A 61 years old Indonesian men has body height of 180 centimeter (cm) and body weight 83 kilogram (kg), has a complete component on the right and left auricles. The left auricle has a normal morphological appearance

(Figure 1A), whereas the right auricle has an abnormal morphological appearance (Figure 1B). Defect of right auricle shows the presence indentation at the superior helix along 2.1cm (see red mark at Figure 1B). Based on morphological examination in this case, we believe that superior helix indentation is due to abnormalities of cartilage tissue synthesis.

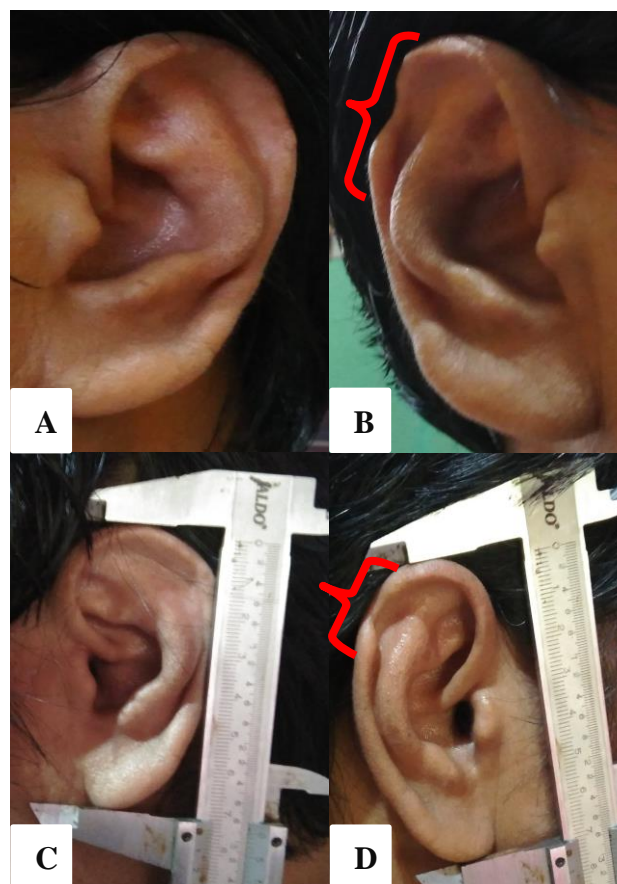


Figure 1: Morphological appearance and biometric measurement of auricles. A) Left auricle showed complete of all components and normal appearance. B) Right auricle showed complete of all components with defect at superior helix. C) Biometric measurement of left auricle showed normal appearance. D) Biometric measurement of right auricle with defect (shows indentation along 2.1 centimeter) at superior helix (see Red mark).

Biometric of the right and left auricles are measured (Figure 1C, Figure 1D). The parameters were total ear length (TEL), ear length above tragus (ELAT), ear length below tragus (ELBT), tragus length (TL), ear breadth (EB), concha length (CL), concha breadth (CB), lobule height (LH), lobule width (LW), ear index (EI) and lobule index (LI) for right and left auricles of the subject. All the measurements were done on bilateral of auricles using standard digital Vernier’s caliper with measuring capability to the nearest 0.1 millimeter (mm). Biometrics of right and left auricles showed in Table 1.

Based on the results of biometric measurement in this case, it shows that ELBT, TL, EB, CL, LH, and EI of right auricle are longer than left auricle, and the other hand TEL, ELAT, CB, LW and LI of left auricle are longer than right auricle.

DISCUSSION

Morphologically, the auricle appearance is normal and some are abnormal, both of which give meaning to morphological variations. It has been reported that abnormal auricle displays are caused by genetic factors. Genetic defect can caused embryonic development defect (congenital abnormalities). In the other hand, auricle deformities may be caused by tumor resection, trauma, burns, and infections.¹⁰ We know that external ear development is a lengthy and complex process that extends from early embryonic life until well into the postnatal period. The development of auricle and external auditory canal during the fourth and fifth weeks of gestation. Additionally that auricle development associated with many congenital disorders and syndromes.¹¹ Morphological defect of right auricle at superior helix in this case accordance to the statement that external ear malformation generally on right ear and unilateral.¹²

Base on Weerda classification, morphological defect of right auricle at superior helix in this case belong in grade I malformations, sub group small deformities.⁴ Characteristic of grade I malformations and small deformities in this case indicated that most structures of normal auricle are present, and small deformities of right auricle at superior helix were indentation (Figure 1B, Figure 1D). Refer to the appearance of auricle abnormality turns out to involve a variety of auricular component malformations³ and the term of means “small ear” although in the literature it applies to small or malformed ears, then small deformities of right auricle at superior helix in this case were indentation be able to classified in microtia.¹³

In this case tends to multi factorial, one of all factor is gene defect that caused development defect of right auricle at superior helix. Additionally that gene mutation caused abnormality in protein and cell metabolism. Abnormality in protein and cell metabolism than caused many organs disorders form.¹⁴ Superior helix indentation in this case involve defect of cartilage synthesis at right auricle. Other studies have shown that cartilage synthesis defects are caused by the Hoxa-2 gene. The Hoxa-2 gene regulates to the expression of transcription factor Eya-1 organises patterns of cell proliferation, which will contribute to the control of auricle appearance both size and shape.¹⁵ Research previously shows that a missense mutation of Hoxa-2 gene has been reported and resulting in substitution of a highly conserved glutamine for a lysine at position 186 of Hoxa-2 gene. The partial loss of human Hoxa-2 gene function results in bilateral microtia with abnormally shaped auricle. Moreover also been

reported that the missense mutation of Hoxa-2 gene in a consanguineous Iranian family segregating for an autosomal recessive form of bilateral microtia.¹⁶ Certainly, Hoxa-2 gene organises patterns of cell proliferation and which will contribute to the control of auricle appearance. Severerity of Hoxa-2 gene mutation corresponds to severerity of auricle morphological defect.

The size of normal auricle depends on various factors such as age,⁴ gender, and body height has been reported.^{2,4} The TEL in adults is about 58-66mm (in women 58–63 mm and men 62-66mm) and EB approximately 32-34mm.⁴ Based on guideline used by Storck et al, TEL of the left and right auricles in this case is longer and EB is normal.⁴ Beside that the TEL and LW in this case are longer than means of population study results.^{2,5} The ELAT, ELBT, TL, CL, CB in this case are also longer than the results of population studies in Northwest India and Northeast India, but EB and LH are the opposite. The EI in this case is smaller than the results of population studies in Northwest India and Northeast India. LI of the right auricle in this case is longer than the average of population study result in Northwest India and is smaller than the results of population studies in Northeast India. In addition, in this case that LI in the left auricle is longer than the average of population study in Northwest India and Northeast India.²

CONCLUSION

In conclusion, in this case that biometric comparison of right and left auricles showed equal or not significant different. Defect at superior helix of right auricle were indentation as abnormal morphological appearance is very rare, while left auricle appearance as normal. Abnormal morphological appearance of right auricle with defect at superior helix were indentation as morphological variation.

Funding: No funding sources

Conflict of interest: None declared

Ethical approval: Not required

REFERENCES

1. Ito I, Ikeda M, Sueno K, Sugiura M, Suzuki S, Kida A. Anthropometric study on normal human auricle in Japan. *Nippon Jibiinkoka Gakkai Kalho.* 2001;104(2):165-74.
2. Verma P, Sandhu HK, Verma KG, Goyal S, Sudan M, Ladgotra A. Morphological Variations and Biometrics of Ear: An Aid to Personal Identification. *J Clin and Diag Res.* 2016;10(5):ZC138-42.
3. Cox TC, Camci ED, Vora S, Luquetti DV, Turner EE. The genetics of auricular development and malformation: New findings in model systems driving future directions for microtia research. *Europ J Med Genet.* 2014;57:394-401.

4. Storck K, Staudenmaier R, Buchberger M, Strenger T, Kreutzer K, von Bomhard A, et al. Total Reconstruction of the Auricle: Our Experiences on Indications and Recent Techniques. *BioMed Research International*; 2014. Article ID 373286:1-15.
5. Shireen S, Karadkhelkar VP. Anthropometric measurements of human external ear. *J Evol Med and Dental Sci.* 2015;4(59):10333-8.
6. Purkait R, Singh P. Anthropometry of the normal human auricle: a study of adult Indian men. *Aesthetic Plast Surg.* 2007;31(4):371-9.
7. Engyz O, Balel S, Unsal M, Ozer S, Oguz KK, Aktas D. 31 cases with oculoauriculovertebral dysplasia (Goldenhar syndrome): clinical, neuroradiologic, audiologic and cytogenetic findings. *Genet Couns.* 2007;18(3):277-88.
8. Conway H, Wagner K. Congenital anomalies of the head and neck. *Plast Reconstr Surg.* 1965;36:71-9.
9. Alasti F, Van Camp G. Genetics of microtia and associated syndromes. *J Med Genet.* 2009;46:361-9.
10. Guo G, Schwedtner O, Klein M. A retrospective study of implant-retained auricular prostheses. *Int J Oral and Maxillofacial Implants.* 2008;23(3):539-43.
11. Pimple DH, Geetha KN, Katti KN, Kesari GV. Morphological Study of External Ear in Mentally Retarded and Healthy Subjects. *J Med and Health Sci.* 2013;2(4):92-7.
12. Weerda H. *Chirurgie der Ohrmuschel. Verletzungen, Defekte und Anomalien*, Sturgart; Thieme. 2004;S:105-226.
13. Carey JC. Ear. In: Stevenson RE, Hall JG, editors. *Human malformations and related anomalies*, 2nd Edi. Oxford: University Press; 2006:935-1022.
14. Parwanto MLE. The genetic aspect and morphological appearance of achondrogenesis. *Int J Reprod Contracept Obstet Gynecol.* 2017;6:3203-12.
15. Minoux M, Kratochwil CF, Ducret S, Amin S, Kitazawa T, Kurihara H, et al. Mouse *Hoxa2* mutations provide a model for microtia and auricle duplication. *Development.* 2013;140:4386-97.
16. Alasti F, Sadeghi A, Sanati MH, Farhadi M, Stollar E, Somers T, et al. A mutation in *HOXA2* is responsible for autosomal-recessive microtia in an Iranian family. *Am J Hum Genet.* 2008;82:982-91.

Cite this article as: Parwanto MLE. Rare defect at superior helix as morphological variation of right auricle. *Int J Res Med Sci* 2018;6:1800-3.