

## Case Report

# Heart failure as the initial manifestation of takayasu's arteritis

Mohd Amir Khan\*, Santwana Dinesh Chandrakar, Varun Shetty

Department of Medicine, DY Patil School of Medicine, Nerul, Navi Mumbai, Maharashtra, India

**Received:** 17 November 2015

**Revised:** 23 December 2015

**Accepted:** 26 December 2015

### \*Correspondence:

Dr. Mohd Amir Khan,

E-mail: [drkhanamir@gmail.com](mailto:drkhanamir@gmail.com)

**Copyright:** © the author(s), publisher and licensee Medip Academy. This is an open-access article distributed under the terms of the Creative Commons Attribution Non-Commercial License, which permits unrestricted non-commercial use, distribution, and reproduction in any medium, provided the original work is properly cited.

## ABSTRACT

Takayasu's arteritis is a rare systemic, inflammatory large vessel vasculitis of unknown etiology that most commonly affects women of childbearing age. It is defined as granulomatous inflammation of the aorta and its major branches. We describe a 27 years old female who presented with dyspnea in the emergency medicine department of DY patil hospital, Maharashtra, India. The initial examination showed signs of heart failure along with unequal pulses bilaterally with difference in systolic BP in bilateral upper limb of more than 10 mm Hg. Patient underwent routine investigations like ECG / 2D-echo / cardiac markers. 2decho was suggestive of severe pulmonary hypertension with dilated cardiomyopathy. Further investigation in view of physical findings and 2decho report led to the diagnosis of takayasu's arteritis.

**Keywords:** Takayasu's arteritis, Heart failure, Aortogram, Pulseless disease, Steroids

## INTRODUCTION

Takayasu's arteritis is a chronic inflammatory disease of unknown etiology characterized by granulomatous inflammation of medium and large arteries, principally the aorta and its branches. Takayasu's arteritis classically exhibits a triphasic pattern of expression consisting of systemic non-vascular phase; a vascular inflammatory phase, and a quiescent "burnt out" phase.<sup>1</sup> However, this classic presentation holds true only in a minority of patients. Here, we present a case of takayasu's arteritis in which the patient presented with symptoms and signs of heart failure. This case report highlights the importance of detailed physical examination and the importance of modern day imaging in diagnosis.

## CASE REPORT

### History

A 27 years old female presented to our hospital with chief complaints of progressive dyspnea and left sided chest pain. A slight dyspnea on exertion appeared 6 months ago

and deteriorated within the last 2 months, leading to shortness of breath at low physical activity levels. Breathlessness has progressed from NYHA grade 1 to NYHA grade 3. Dyspnea was associated with left sided chest pain which started 1 month back. Chest pain was typical anginal in nature.

On inquiry there was history of orthopnea and paroxysmal nocturnal dyspnea.

There was no history of cough, hemoptysis, fever, joint pain, headache, malaise, weight loss, loss of appetite or any other systemic manifestation.

No history of tuberculosis or tuberculosis contact.

Patient consulted a chest physician initially and was suspected of having bronchial asthma and started on formoterol and budesonide rotahaler for the same.

### On examination

The patient was conscious cooperative and well oriented in time, place and person. She was moderately built and well nourished.

Her left and right radial pulses were unequal, left radial pulse was weak and feeble.

Blood pressure in right upper limb was 154/104 mm Hg and left upper limb was 114/82 mm Hg. There was bilateral pitting pedal edema upto the ankle joint. JVP was raised. Arterial as well as venous neck pulsations were visible.

Bruit was heard over the bilateral carotids.

On CVS examination S3 gallop was audible.

Fundus examination revealed slight arteriolar attenuation.

### Initial investigations

An ECG and 2D-echo were done in the emergency medicine department.

ECG findings were as follows; (1) Poor progression of R waves and (2) Right axis deviation.

2D-echo revealed are as follows; (1) Severe global hypokinesia; (2) LVEF 15-20%; (3) Dilated right atrium/ right ventricle/ IVC; (4) Minimal pericardial effusion; (5) Severe pulmonary hypertension with tricuspid regurgitation and (6) PASP: 90 mmHg.

In view of the physical findings and 2decho report patient underwent aortography and CT pulmonary angiography.

Aortography showed in Figure 1. Diffuse long segment thickening and narrowing of the left common carotid artery (Figure3) and subclavian artery (Figure4) from its origin. Diffuse intimo-medial thickening involving retro cardiac descending aorta (Figure2) with mild luminal narrowing.

Severe focal luminal narrowing of the infra cardiac descending aorta (Figure 5) with diffuse intimo-medial thickening causing more than 70% luminal narrowing.

Abdominal aorta and the renal arteries are normal in course and caliber, CT pulmonary angiography was normal and Angiography of neck vessels was normal.

### Laboratory findings

- ESR was 95mm/hr
- CRP was 18.58 microgram/ml
- BNP was 326
- Hb- 10.9 gm/dl

- TLC-13.6
- Platelet-287
- Creat-0.7
- VDRL negative
- ANA, lupus anticoagulant and anticardiolipin antibodies were absent.

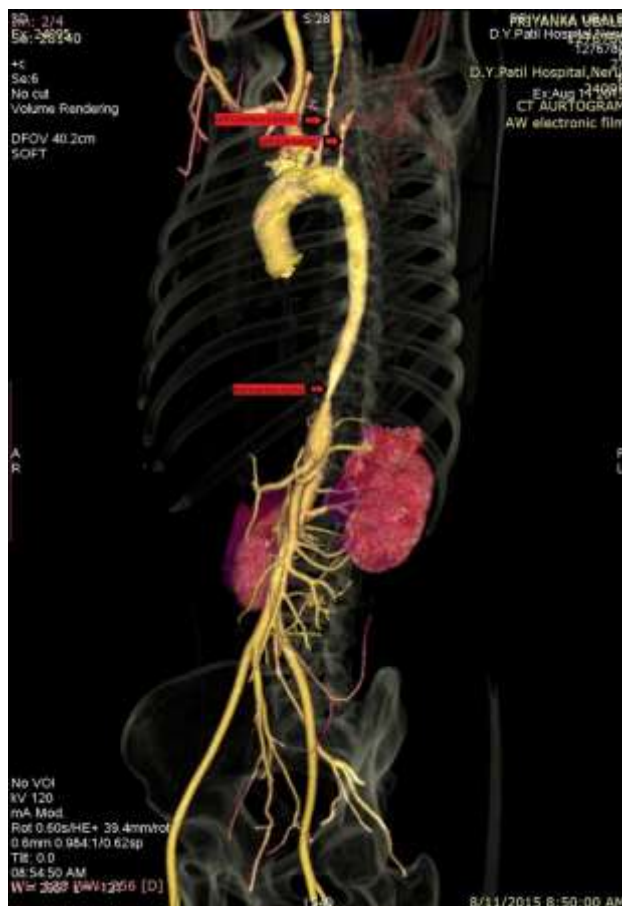


Figure 1: 3D Aortogram.

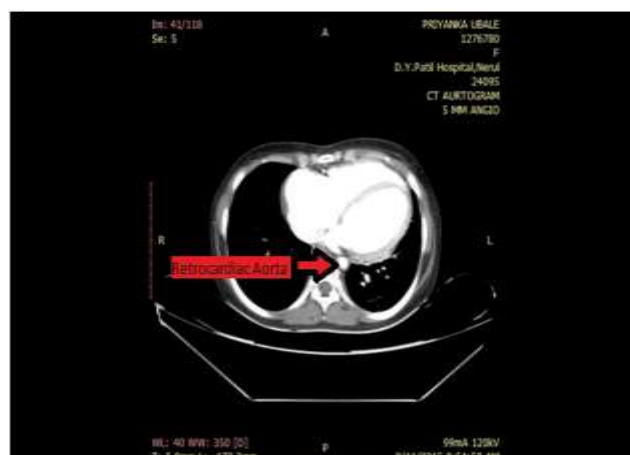
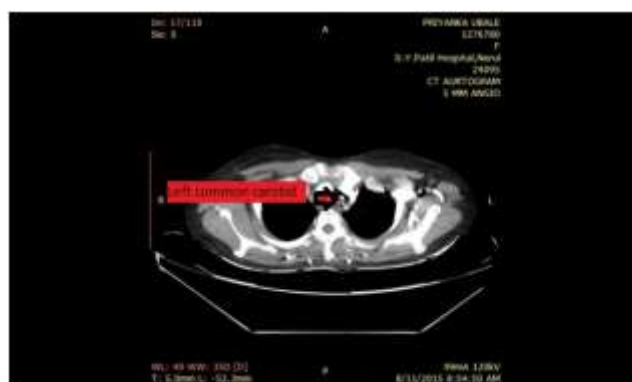
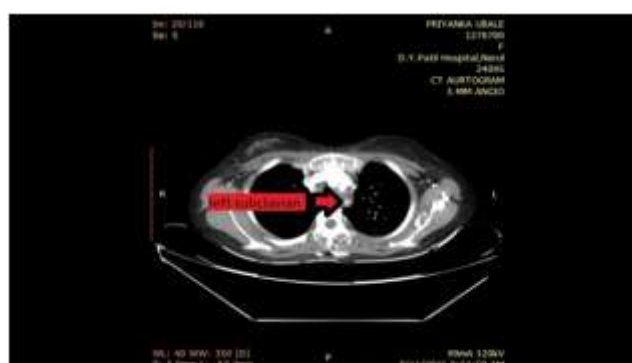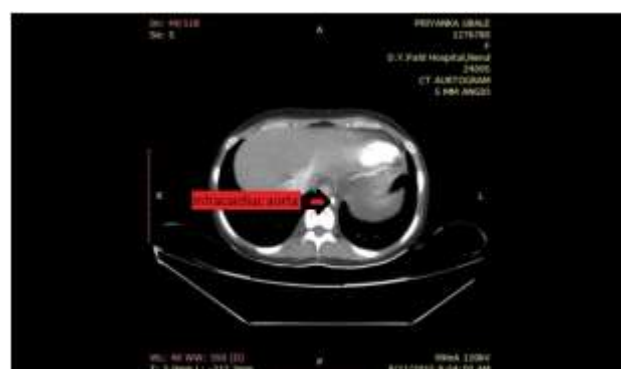Figure 2: Retro cardiac aorta.



**Figure 3: Left common carotid.**



**Figure 4: Left subclavian.**



**Figure 5: Infracardiac aorta**

Finally the diagnosis of takayasu's arteritis was established based on the following findings which fulfilled the American College of Rheumatology 1990 criteria; (1) Age of onset less than 40 years; (2) Decreased radial artery pulse on left side; (3) Blood pressure difference of more than 10 mm Hg between the two upper extremities; (4) Audible bruit over the carotids; (5) Aortogram abnormalities

Other differential diagnosis that were considered and excluded were syphilis, lupus, rheumatoid arthritis, Wegener's granulomatosis, giant cell arteritis, Behcet's disease, sarcoidosis, neoplastic disorders, tuberculosis,

anti-phospholipid syndrome and pulmonary thromboembolism.

The patient is being treated with steroids, diuretics, B-blockers and digoxin. The patient is responding well to the treatment. Dyspnea has reduced significantly (NYHA grade 3 to NYHA grade 1).

## DISCUSSION

Takayasu's arteritis also known as "pulseless disease", thromboangiopathy and "Martorell syndrome" It is characterized by chronic inflammation of large and medium sized vessels leading to wall thickening, fibrosis, stenosis, and thrombosis. It affects predominantly aorta and its branches. Symptoms depend on end organ ischemia. Published descriptions of this arteritis date back as far as 1830. Takayasu's arteritis is rare, but commonly seen in Japan, South East Asia, India, and Mexico. It has been included in the list of intractable diseases by the Japanese Government and to date 5,000 patients have been registered.

Takayasu's arteritis is characterized by three stage disease.

1. The first stage is an early systemic stage during which the patient may complain of constitutional symptoms (e.g. fatigue, malaise, giddiness, fever). This stage is considered to be pre vasculitic.
2. The second stage is the vascular inflammatory stage, when stenosis, aneurysms and vascular pain (carotidynia) tend to occur. Symptoms characterizing the vascular inflammatory stage include fatigue, fever, malaise, joint pains, dyspnea, palpitations, headache, rash, and hemoptysis. Symptoms of vascular insufficiency include arm numbness, claudication, blurry vision, double vision, amaurosis fugax, stroke, TIA and seizures.
3. The third stage is the burned out stage, when fibrosis sets in, and generally is associated with remissions. This stage does not occur in all patients, and even in patients who are in remissions, relapses can occur.

1990 American College of Rheumatology criteria for diagnosis of Takayasu's Arteritis are as follows.<sup>2</sup>

1. Age of onset < 40 years
2. Claudication of extremities.
3. Decreased brachial artery pressure.
4. Blood pressure difference >10 mm Hg
5. Bruit over subclavian arteries and aorta.
6. Aortogram abnormalities.

At least 3 of the above 6 criteria are to be met for the diagnosis.

Tuberculosis has been implicated in the aetiology and also as an important differential, in view of the high prevalence of infection; past or present, in affected patients.<sup>3</sup> A viral trigger to the vascular inflammation has also been postulated. The association with certain HLA alleles in various populations has strengthened the argument for an autoimmune process, though no specific auto antigens have been identified. One study demonstrated an association between several cases of Takayasu's arteritis and CD36 deficiency.<sup>4</sup>

Steroids are the mainstay of treatment for Takayasu's arteritis. Approximately half of the patients respond to steroids.

Steroid unresponsive patients can be treated with cytotoxic drugs including cyclophosphamide, azathioprine, and methotrexate.

IL-6 receptor inhibitor tocilizumab has shown recent promise in inducing remissions.<sup>5</sup>

Rituximab, a chimeric IgG1 antibody that binds to CD20 expressed on the surface of B cells has shown to improve clinical signs and symptoms of takayasu's areteritis.<sup>6</sup>

Anti tumour necrosis factor agents like etanercept have shown encouraging results in a small number of patients with relapsing takayasu's arteritis.<sup>7</sup>

Treatment should aim to control disease activity, preserve vascular competence with minimal long term side effects.

Surgical treatment is offered to those with severe stenosis of renal artery, extremity claudication, stenosis of 3 or more cerebral vessels, or evidence of coronary artery involvement.

Cumulative survival at 5 years after disease onset was 91%, and after 10 years the figure was 84%.

Our patient demonstrated atypical manifestation of takayasu's arteritis, which are typically associated with pulmonary artery involvement and pulmonary artery hypertension. The increasing breathlessness noted during the 4 months prior to admission is probably related to progressive pulmonary hypertension. It is difficult to distinguish these cases from primary lung disease and chronic pulmonary embolism. In the absence of systemic involvement, the differential diagnosis of takayasu's

arteritis and chronic thromboembolic disease may be facilitated by a raised ESR as in our case.

## CONCLUSION

Takayasu's arteritis is a rare but a potentially fatal disorder. Detailed knowledge and high level of clinical suspicion is of utmost importance to diagnose such cases. The importance of detailed clinical examination including palpation of all peripheral pulsations is highlighted in this case. Hence, the diagnosis of Takayasu's arteritis should be suspected in all women of child bearing age group presenting with dyspnea and heart failure.

*Funding: No funding sources*

*Conflict of interest: None declared*

*Ethical approval: Not required*

## REFERENCES

1. Jennette JC, Falk RJ, Andrassy K, Bacon PA, Churg J, Gross WL. Nomenclature of systemic vasculitides. Proposal of an international consensus conference. *Arthritis Rheum.* 1994;37(2):187-92.
2. Arend WP, Michel BA, Bloch DA, Hunder GG, Calabrese LH, Edworthy SM et al. The American College of Rheumatology 1990 criteria for the classification of Takayasu arteritis. *Arthritis Rheum.* 1990;33(8):1129-34.
3. Aggarwal A, Chag M, Sinha N, Naik S. Takayasu's arteritis: role of mycobacterium tuberculosis and its 65 kDa heat shock protein. *Int J Cardiol.* 1996;55(1):49-55.
4. Yagi K, Kobayashi J, Yasue S, Yamaguchi M, Shiobara S, Mabuchi H. Four unrelated cases with Takayasu arteritis and CD36 deficiency; possible link between these disorders. *J Intern Med.* 2004;255(6):688-9.
5. Salvarani C, Magnai L, Catanoso M, Pipitone N, Versari A, Dardani L et al. Tocilizumab; a novel therapy for patients with large-vessel vasculitis. *Rheumatology (Oxford).* 2012;51(1):151-6.
6. Unizony S, Stone JH, Stone JR. New treatment strategies in large vessel vasculitis. *Curr Opin Rheumatol.* 2013;25(1):3-9.
7. Maksimowicz-McKinnon K, Hoffman GS. Takayasu arteritis: what is the long-term prognosis? *Rheum Dis Clin North Am.* 2007;33(4):777-86.

**Cite this article as:** Khan MA, Chandrakar SD, Shetty V. Heart failure as the initial manifestation of takayasu's arteritis. *Int J Res Med Sci* 2016;4:330-3.