

## Original Research Article

# Posterior cranial FOSSA space occupying lesions: an institutional experience

Natarajan Meenakshisundaram, Balasubramanian Dhandapani\*

Department of Neurosurgery, Institute of Neurosurgery, Madras Medical College, Tamilnadu, India

**Received:** 23 May 2018

**Revised:** 25 May 2018

**Accepted:** 29 May 2018

### \*Correspondence:

Dr. Balasubramanian Dhandapani,  
E-mail: drbala61@gmail.com

**Copyright:** © the author(s), publisher and licensee Medip Academy. This is an open-access article distributed under the terms of the Creative Commons Attribution Non-Commercial License, which permits unrestricted non-commercial use, distribution, and reproduction in any medium, provided the original work is properly cited.

## ABSTRACT

**Background:** Tumors in the Posterior fossa are well known for their critical location and complications as they result in brain stem compression and hydrocephalus. This study was conducted to analyze the histological types, frequency and prognosis of the posterior cranial fossa tumors in children and adults at Institute of Neurosurgery, Madras Medical College, Chennai, Tamilnadu.

**Methods:** It was a descriptive study in which 108 consecutive cases of posterior cranial fossa tumors in children and adults were studied from December 2016 to November 2017. During this period, patients with posterior cranial fossa tumors were thoroughly studied and analysed regarding further management options.

**Results:** Out of 108 cases in our study, 60 (56%) cases were male and 48 (44%) were female patients. The morphological distribution of the posterior cranial fossa tumors was as follows: schwannoma 36 (33%) cases, meningioma 24 (22%) cases, medulloblastoma 14 (13%) cases, pilocytic astrocytoma 17(16%) cases, high grade astrocytoma 7 (7%) cases, metastasis 8 (8%) cases, round blue cell tumor 2 (2%) cases.

**Conclusions:** Brainstem compression, herniation, and death are all risks in tumors which occur in this critical location. Tumors in the posterior fossa are considered critical brain lesions, primarily because of the limited space within the posterior fossa and the potential involvement of vital brain stem nuclei.

**Keywords:** Early diagnosis, Histopathology, Prognosis, Posterior cranial fossa tumors

## INTRODUCTION

Brain tumor is one of the most fatal tumors, especially when occurring in the posterior cranial fossa. Tumors in the posterior fossa are considered critical as they cause brainstem compression, herniation and death.<sup>1-3</sup>

The clinical presentation depends on the site of the tumor, biological behavior and aggressiveness of the tumor and the rate of growth. The patient usually present with severe headache or frequent vomiting due to associated hydrocephalus. All these symptoms are usually due to focal compression of the cerebellum or brain stem and increased intracranial pressure.

Cushing was the first person to report a large series of posterior fossa tumors. He published information about 61 patients with Cerebellar Medulloblastoma with mostly fatal outcome.<sup>1</sup>

Brain tumors continue to be among the top ten causes of cancer related deaths in the world. Brain tumors are the second most common solid tumors in children next to leukemia.

Posterior fossa tumors are more common in children than in adults. Between 54% and 70% of all childhood brain tumors originate in the posterior fossa. About 15-20% of brain tumors in adults occur in the posterior fossa.<sup>2</sup>

Certain types of posterior fossa tumors, such as medulloblastoma, pineoblastoma, ependymoma, astrocytoma and primitive neuroectodermal tumors (PNETs) of the cerebellum and brain stem, occur more frequently in children. Some glial tumors, such as mixed gliomas, are unique to children; they are located more frequently in the cerebellum (67%) and are usually benign.

Posterior cranial fossa tumors in children differ from adults in their clinical presentation, behavior, management and prognosis. Glial tumors and PNET have relatively better prognosis in children than in adults. Due to improved imaging modalities and treatment facilities certain tumors have better prognosis like Medulloblastoma.<sup>3</sup>

Late presentation, local infiltration and metastasis outside the cranial cavity constitutes for increased mortality and morbidity. Recurrence of benign lesions like meningiomas increases the morbidity and mortality.<sup>3</sup> The purpose of this study was to analyze the frequency and histological types of posterior cranial fossa tumors in children and adults.

## METHODS

A descriptive study of patients with posterior fossa space occupying lesions in the Institute of Neurosurgery, Madras Medical College and Hospital was done from December 2016 to November 2017. Patients with complaints of headache especially in the sub occipital region, vomiting, altered sensorium, features suggestive of lower cranial nerve involvement and features suggestive of intracranial hypertension underwent serial imaging techniques with non-contrast computed tomography of brain, contrast enhanced computed tomography of brain and magnetic resonance imaging of brain. Magnetic resonance imaging sequences include T1, T2, fluid attenuated inversion recovery sequences FLAIR, diffusion weighted imaging DWI, susceptibility weighted imaging SWI, T1 gadolinium contrast enhancement and magnetic resonance spectroscopy MRS. Patients were admitted and evaluated further with cardiac, pulmonary and anesthetist fitness. Routine blood investigations including complete hologram, renal and liver function test, coagulation profile and blood grouping. Diabetologist opinion was obtained for patients with deranged glycemic status. The data including various parameters like age, sex, tumour location, type of surgery and histological diagnosis were collected and analyzed. This study comprises of 108 cases of posterior fossa tumors in all age groups. Children above 12 years of age are included under adults. Cerebrospinal Fluid diversion procedures like ventricular peritoneal shunt was carried out in patients with hydrocephalus.

Neurosurgical intervention-sub occipital craniotomy, midline, paramedian and retrosigmoid approach was done

based on the location of the infratentorial tumour in the posterior fossa in all these cases. Following surgery, specimens were sent for histopathological evaluation and microscopic diagnosis was made. The data of these patients along with histopathological reports were analysed. Based on the age of the patient, histopathology of the tumor and residual tumor tissue patient was subjected to radiotherapy post operatively. Suture removal was done on seventh post-operative day. Patient was discharged by around thirteenth post-operative day (average 12 to 15).

## RESULTS

Out of 108 cases in our study, the gender distribution was 60 (56%) male and 48 (44%) female patients with male preponderance (Figure 1). Among these patients 64 (59%) were adults and 44 (41%) were children (Table 2) (Figure 4).

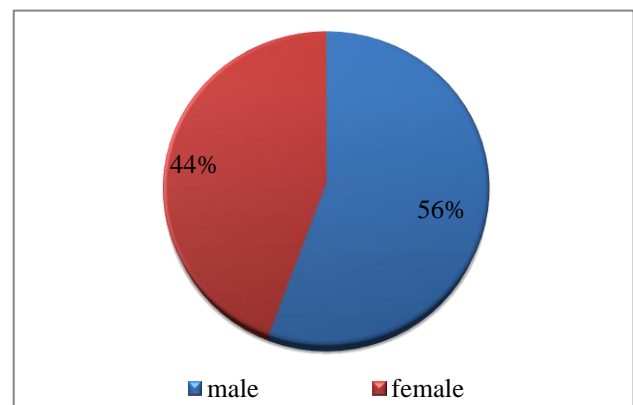


Figure 1: Gender wise incidence of tumors.

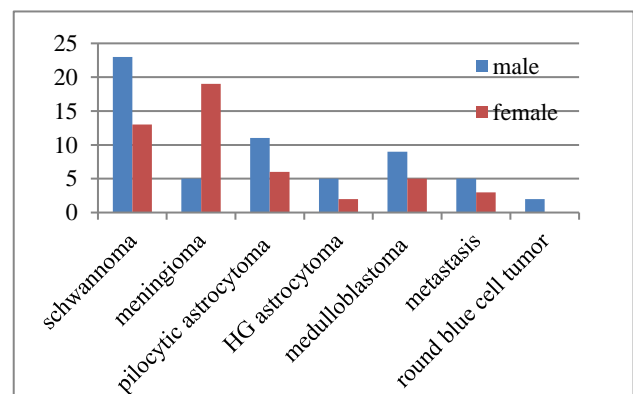
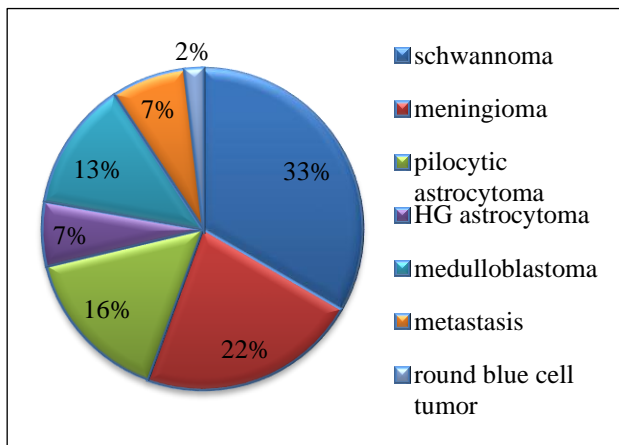


Figure 2: Distribution of tumors according to the gender.

Final diagnosis was made by histopathological examination (Table 1) which is as follows, schwannoma 36 (33%) cases, meningioma 24 (22%) cases, medulloblastoma 14 (13%) cases, pilocytic astrocytoma 17 (16%) cases, high grade astrocytoma 7 (7%) cases, Metastasis 8 (8%) cases, round blue cell tumor 2 (2%) cases (Figure 3).

**Table 1: Incidence of posterior cranial fossa tumors in this study.**

Types	No. of cases	Percentage
Schwannoma	36	33%
Meningioma	24	23%
Pilocytic astrocytoma	17	16%
High grade Astrocytoma	7	7%
Medulloblastoma	14	13%
Metastasis	8	7%
Malignant Round blue cell tumor	2	2%
Total	108	100%

**Figure 3: Morphological distribution of posterior cranial fossa tumors.**

Complete excision was possible in 17 cases of meningioma, 29 cases of schwannoma, 13 cases of pilocytic astrocytoma. The patients with medulloblastoma, high grade astrocytoma and received course of radiotherapy. 2 cases were diagnosed as malignant round blue cell neoplasms.

## DISCUSSION

The present study was designed to determine the frequency of Posterior fossa SOL from December 2016 to November 2017 among 108 cases. In our study the frequency of posterior fossa SOL is 60% with male preponderance which is similar to many other studies.<sup>4,5</sup>

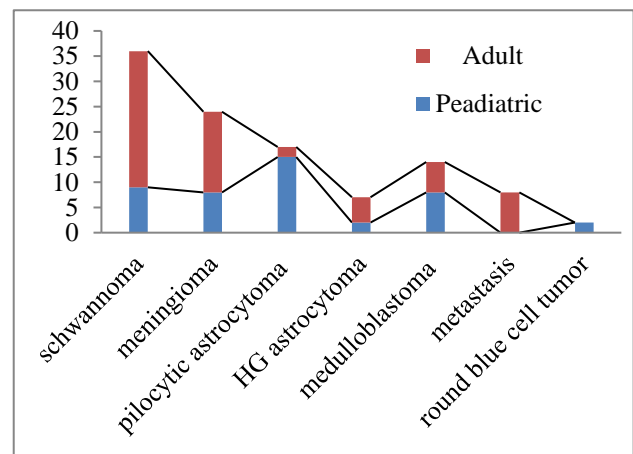
WHO guidelines were followed for histological classification of the posterior cranial fossa tumors.<sup>6</sup> Schwannoma was the most commonest tumor and is most commonly seen in adults (33%).<sup>7</sup> Medulloblastoma was the most common tumor seen in children (13%) in our study which is similar to many other studies.<sup>8</sup>

Certain tumors are common in adults and certain tumors are common in children which were observed in our study. Meningiomas are commonly seen in adults than in childhood which is consistent with our study.<sup>3,8,9</sup> In our study, 66% of cases were seen in adults. In our study,

complete resection was done in 17 cases, complete resection was very difficult in these cases because of their location (Figure 4).

**Table 2: Distribution of tumors by age group.**

Types	Paediatric (%)	Adult (%)
Schwannoma	9 (25%)	27 (75%)
Meningioma	8 (33%)	16 (66%)
Pilocytic astrocytoma	15 (88%)	2 (12%)
High grade astrocytoma	2 (12%)	5 (88%)
Medulloblastoma	8 (57%)	6 (43%)
Metastasis	0	8 (100%)
Malignant round blue cell tumor	2 (100%)	0

**Figure 4: Morphological distribution of posterior cranial fossa tumors by age group.**

In astrocytoma, the frequency varies in many studies, in our study 15 cases of pilocytic astrocytoma was seen in children. High grade astrocytomas were seen in 7 cases (7%), 5 cases in adults and 2 cases in children.<sup>3,10</sup>

Brain metastasis is more common in the older age group, as in our study authors got 8 cases all are seen in elderly adults.<sup>11</sup> Malignant round blue cell tumor were seen in 2 cases in our study.

With the help of modern imaging modalities early diagnosis is possible in many cases which will improve the morbidity and mortality rate among the patients. The most common procedures performed for these patients in our study are Midline sub occipital craniectomy and retro sigmoid approach (Lateral sub occipital craniectomy). Radiotherapy was advised for cases like High grade gliomas, medulloblastomas and in certain residual lesions. Assigning radiotherapy varies in children.

Hydrocephalus is most commonly seen in children with posterior fossa tumors, occurring in 71-90% of pediatric patients; approximately 10-40% demonstrates persistent hydrocephalus after posterior fossa tumor resection.<sup>12,13</sup>

Patients older than 3 years are considered at standard risk or high risk and have long-term survival rates of approximately 85% and 70%, respectively. In patients 3 years or younger, survival rates are generally lower.<sup>14</sup> A total number of 10 deaths were recorded in our study (Table 3).

## CONCLUSION

Posterior fossa tumors are well known for their complications with high morbidity and mortality because of their location, risk in excision of the lesion and involvement of the brain stem structures and fourth ventricle. Due to the advent of recent diagnostic and treatment modalities early diagnosis is possible which helps in reducing the mortality rate and also improves the prognosis post operatively.

*Funding: No funding sources*

*Conflict of interest: None declared*

*Ethical approval: The study was approved by the Institutional Ethics Committee*

## REFERENCES

1. Cushing H. Experience with the cerebellar medulloblastoma: critical review. Acta Pathol Microbiol Immunol Scand. 1930;7:1-86.
2. Al-Shatoury HAH, Galhom AA, Engelhard H. Posterior fossa tumors. Emedicine Neurosurgery 2008. Available from: <https://emedicine.medscape.com/article/249495-overview>.
3. Rehman AU, Lodhi S, Murad S. Morphological pattern of posterior cranial fossa tumors. Annals. 2009;15(2):51-57.
4. Mishra BK. Acute post-traumatic brain edema in children. NIMHANS J. 1984;2:56.
5. Mahapatra AK. Head injury in children. A text book of headinjury. Modern Publishers, New Delhi, 3<sup>rd</sup> edn, 2005:151-71.
6. Louis DN, Perry A, Reifenberger G. The 2016 World Health Organization classification of tumors of the central nervous system: a summary. Acta Neuropathol. 2016;131:803-20. [PubMed].
7. Shenoy SN, Raja A. Cystic olfactory groove schwannoma. Neurology India. 2004;52(2):261-2.
8. Kadri H, Mawla A, Murad L. Incidence of childhood brain tumors in Syria (1993-2002). Pediatr Neurosurg. 2005;41:173-17.
9. Mirimanoff RO, Dosoretz DE, Linggood RM, Ojemann RG, Martuza RL. Meningioma: analysis of recurrence and progression following neurosurgical resection. J neurosurgery. 1985 Jan;62(1):18-24.
10. Hanif G, Shafqat S. Morphological Pattern and frequency of Intracranial tumour in children. J Coll Physicians. Surg Pak. 2004;14:150-2.
11. Tasdemiroglu E, Patchell RA. Cerebral metastases in childhood malignancies. Acta Neurochir (Wien). 1997;139:182-7.
12. Lin CT, Riva-Cambrin JK. Management of posterior fossa tumors and hydrocephalus in children: a review. Childs Nerv Syst. 2015;(10):1781-9.
13. Lam S, Reddy GD, Lin Y, Jea A. Management of hydrocephalus in children with posterior fossa tumors. Surg Neurol Int. 2015;6 (Suppl 11):S346-8.
14. Millard NE, De Braganca KC. Medulloblastoma. J Child Neurol. 2015 Sep 2.

**Cite this article as:** Meenakshisundaram N, Dhandapani B. Posterior cranial FOSSA space occupying lesions: an institutional experience. Int J Res Med Sci 2018;6:2281-4.