

Original Research Article

Matrix metalloproteinase-9 (MMP-9) as prospective histopathological and molecular biomarker for oral squamous cell carcinoma

Bhgyalakshmi Atla¹, Sreevalli Prabhakula², Seeram Satish Kumar¹,
Lakshmi Saraswathi Boni^{1*}

¹Department of Pathology, Andhra Medical College, Visakhapatnam, Andhra Pradesh, India

²Department of Pathology, SVIMS, Tirupathi, Andhra Pradesh, India

Received: 15 June 2018

Accepted: 09 July 2018

*Correspondence:

Dr. Lakshmi Saraswathi Boni,

E-mail: dr.lakshmisaraswathi@yahoo.com

Copyright: © the author(s), publisher and licensee Medip Academy. This is an open-access article distributed under the terms of the Creative Commons Attribution Non-Commercial License, which permits unrestricted non-commercial use, distribution, and reproduction in any medium, provided the original work is properly cited.

ABSTRACT

Background: Despite the advance of therapeutic approaches, the morbidity and mortality of oral squamous cell carcinoma have not improved significantly. The invasion potential of oral squamous cell carcinoma is conferred by their ability to utilize Matrix metalloproteinase that are produced by the host's stromal cells. In the present study an effort was made to analyse the role of clinical features and risk factors in the causation of oral squamous cell carcinoma and expression of Matrix metalloproteinase-9 (MMP-9) was studied in various grades of squamous cell carcinoma with its role in metastasis.

Methods: The present study is an hospital based prospective study for a period of two years at the department of pathology from August 2014 to July 2016 consisting of 88 cases of oral squamous cell carcinoma. Tissue for H and E sections were fixed in 10% formalin and subjected to routine paraffin embedded processing and stained with hematoxylin and eosin.

Results: Total number of cases of oral squamous cell carcinoma analyzed were 88, out of which 65 cases were subjected to MMP 9 expression by random selection on Immunohistochemistry. Majority of cases occurred in the age group of 41-50 years with male: female ratio of 1.4:1. In stage I and II the expression of MMP-9 is low in 37 cases (82.22%) and in stage III the expression is high in 14 cases (70%) with P value <0.05 (significant).

Conclusions: Matrix metalloproteinases could act as a therapeutic target and could play an important role in effective treatment strategies of oral cancer.

Keywords: Matrix metalloproteinase-9, Oral cancer, Squamous cell carcinoma

INTRODUCTION

Despite the advance of therapeutic approaches, the morbidity and mortality of oral squamous cell carcinoma have not improved significantly. At least 90% of all oral malignancies are of this kind. In the world-incidence ranking of cancers, it holds the 8th position.¹

One of the real danger of this neoplasm is that in the early stage it can go unnoticed. The most important risk factors

are use of tobacco, betel nut and intake of alcohol. There is marked variation with regard to the incidence and mortality from oral squamous cell carcinoma between different countries, between ethnic/racial groups. This may be attributed to exposure to different environmental factors and to ethnic specific high risk habits.²

The metastatic potential of OSCC depends upon its ability to digest the extracellular matrix (ECM), to penetrate the basement membrane (BM), to initiate

tumour angiogenesis and to invade the adjacent tissues and vessels.³

Degradation of the ECM and the BM requires the participation of matrix metalloproteinases (MMPs). Most of these enzymes are involved in common physiological processes, such as the proliferation, differentiation and apoptosis of cells, angiogenesis, and the morphogenesis and repair of bodily tissues.⁴

Matrix metalloproteinases expression and clinical features may improve the diagnosis and prognosis. Application of MMPs as prognostic indicators for the malignancy potential of oral squamous cell carcinoma might be considered in every case of tumour examination.¹

In the present study, an effort was made to analyse the role of clinical features and risk factors in the causation of oral squamous cell carcinoma. Expression of Matrix metalloproteinase-9 (MMP-9) was studied in various grades of squamous cell carcinoma with its role in metastasis.

METHODS

The present study is an hospital based prospective study for a period of two years at the department of pathology from August 2014 to July 2016, conducted in the Department of Pathology, Andhra Medical College, Visakhapatnam.

A total number of 88 cases of oral squamous cell carcinoma received to the department are included in the study. All non-neoplastic, benign lesions and on therapy were excluded from the study. Informed written consent was taken. Detailed clinical data were obtained and noted on a structured proforma.

Tissue for H and E sections were fixed in 10% formalin and subjected to routine paraffin embedded processing and stained with hematoxylin and eosin. The histopathological sections were categorised basing on WHO classification and Broders grading. The number of cases analysed during this period was 88. All the cases presented with cervical lymphadenopathy of variable sizes. The lymph nodes were subjected to fine needle aspiration cytology to rule out metastatic deposits.

For immunohistochemistry, 3-4micron sections were taken from paraffin embedded tissue blocks. Out of 88 cases of oral squamous cell carcinoma, 65 cases are subjected to immunohistochemistry with MMP-9 expression.

Positive and negative controls were run with each batch. Positive staining was controlled by positively stained splenic tissue MMP-9 is predominantly expressed in neutrophils, macrophages, mast cells and stromal cells; the negative control was performed on the same tissue

without primary antibody. MMP-9 is a cytoplasmic marker. MMP-9 is mainly observed in the cytoplasm of stromal cells and proliferating tumor epithelial cells as brownish granules under 400X.

For analysis MMP-9 expression five microscopic fields in tumour tissues (High magnification 400X) were randomly selected and the percentage of positive cells was calculated.

The percentage of positive cells was divided into four groups as follows:

- 0-25%, negative expression;
- 25-50%, weak expression;
- 50-75%, moderate expression;
- 75-100%, strong expression.

Statistical analysis

Low expression of MMP-9 included those with negative or weak expression. 'High expression' of MMP-9 included those with moderate or strong expression. Data was analysed using chi-square test and P value <0.05 to establish the significance.

RESULTS

Total number of cases of oral squamous cell carcinoma analyzed were 88. Total number of cases subjected to MMP 9 expression by random selection on Immunohistochemistry were 65.

In the present study, majority of oral squamous cell carcinoma occurred in the age group of 41-50 years that is 5th decade which constitute 25 cases (28.4%), followed by 61-70 years of age group which constitute 20 cases (22.74%) out of 88 cases (Table 1).

Table 1: Age wise distribution of oral squamous cell carcinoma (n=88).

Age group (yrs)	No. of cases (total no. of cases = 88)	Percentage (%)
Less than 20	0	0
21-30	7	7.95%
31-40	15	17.05%
41-50	25	28.40%
51-60	19	21.59%
61-70	20	22.74%
71-80	2	2.27%
Total	88	100%

In the present study, commonest clinical presentation is ulceroproliferative growth seen in 40 cases (45.45%) followed by fungating growth in 38 cases (43.18%) (Table 2). In this study, tongue is the commonest site involved by oral squamous cell carcinoma that is 47 cases (53.4%) followed by hard palate (37.5%). In the present

study, 44 cases (50%) are of 2-4cm in size followed by more than 4cm in 31 cases (35.22%). In this study, reverse smoking is seen in 24 cases (27.28%) of oral squamous cell carcinoma, tobacco chewing in 22 cases (25%). In 2 cases (2.28%) there are no risk factors. In the present study, oral squamous cell carcinoma is common in males constitute 52 cases (59.1%) out of 88 cases with male: female ratio of 1.4:1.

Table 2: Clinical presentation in cases of oral squamous cell carcinoma (n=88).

Clinical presentation	No. of cases	%
Ulceroproliferative growth	40	45.45%
Fungating growth	38	43.18%
Ulcer	10	11.37%
Total	88	100%

In this study, moderately differentiated squamous cell carcinoma (Figure 1) accounts for 45 cases (51.1%) out of 88 cases and well differentiated squamous cell carcinoma accounts for 43 cases (48.9%) out of 88 cases. (Figure 2) Poorly differentiated squamous cell carcinoma are not encountered in the present study.

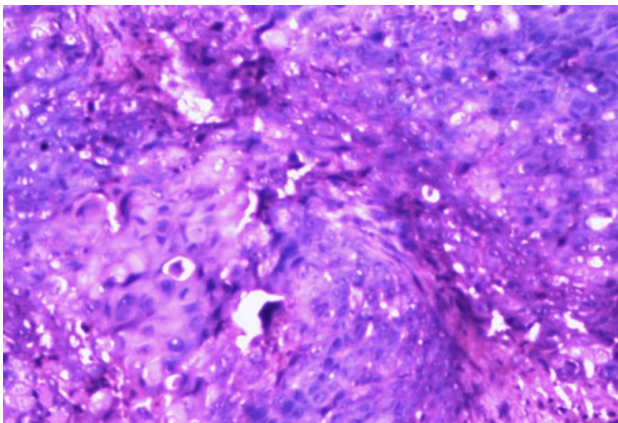


Figure 1: Moderately differentiated squamous cell carcinoma (H and E, 100X).

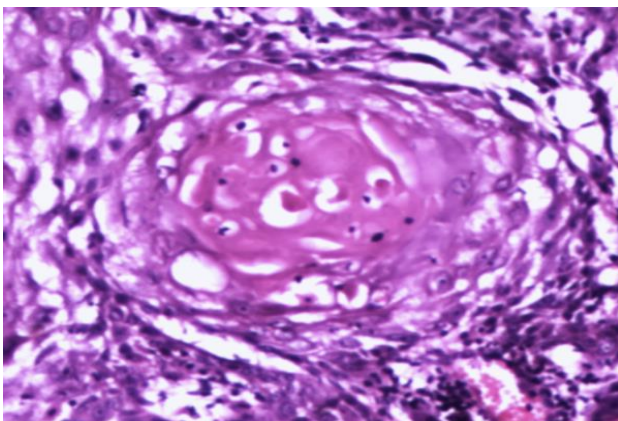


Figure 2: Well differentiated oral squamous cell carcinoma (H and E, 400X)

In the present study, all the 88 cases of oral squamous cell carcinoma had cervical lymphadenopathy. The size of the lymph nodes were less than 3cm. 20 cases (22.7%) showed metastatic deposits and 68 cases (77.3%) showed reactive changes in lymph node. In this study, out of 20 cases of lymph node metastasis 17 cases (85%) are moderately differentiated squamous cell carcinoma and 3 cases (15%) are well differentiated squamous cell carcinoma.

Out of 88 cases with oral squamous cell carcinoma only 65 cases are subjected to immunohistochemistry with MMP-9 by random selection. MMP-9 expression is low in 43 cases out of 65 cases (66.1%) and high in 22 cases (33.9%) out of 65 cases (Figure 3, 4).

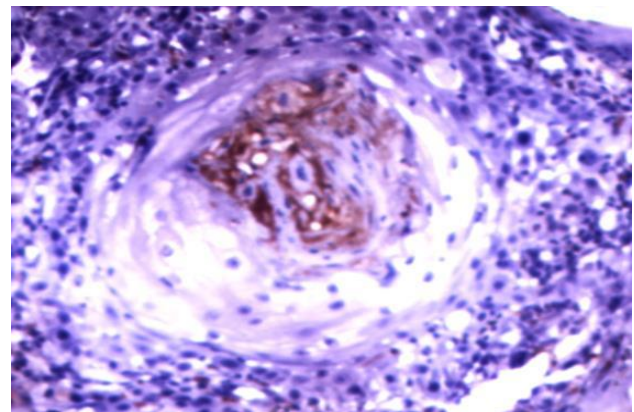


Figure 3: Low expression (cytoplasmic positivity) for MMP-9 in Well differentiated oral squamous cell carcinoma (IHC, 400X).

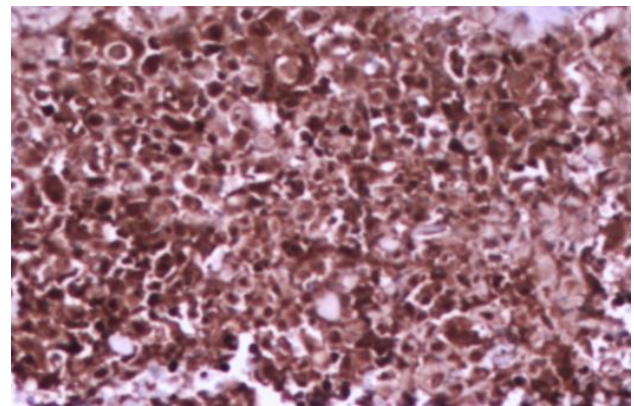


Figure 4: High expression of MMP-9 in Moderately differentiated squamous cell carcinoma (IHC, 100X)

In the present study, reverse smoking only is seen in 18 cases. Out of 18 cases, MMP-9 expression is low in 11 cases (61.11%) and high in 7 cases (38.89%) and only 2 cases are found without any risk factors, these 2 cases showed low expression of MMP-9 (100%) (Table 3).

In this study, ulceroproliferative growth is seen in 27 cases. Out of 27 cases, MMP-9 expression is low in 17

cases (62.97%) and high in 10 cases (37.03%). In the present study, commonest site is tongue in 35 cases. Out of 35 cases, MMP-9 expression is low in 24 cases (68.57%) and high in 11 cases (31.43%).

Table 3: Comparison of risk factors with MMP-9 expression (n=65).

Risk factors	No. of cases	MMP-9 expression	
		Low	High
Smoking only	2	1	1
Tobacco chewing only	15	11	4
Reverse smoking only	18	11	7
Smoking with alcohol	14	10	4
Tobacco chewing with alcohol	14	8	6
No risk factors	2	2	-
Total	65	43	22

Tumor size of less than 4cm the expression of MMP-9 is low in 38 cases (90.47%) and tumor size of more than 4cm in 18 cases (78.26%) the expression is high. In this study, majority of oral squamous cell carcinoma occur in age group of 41-50years that is 20 cases. Out of 20 cases, MMP-9 expression is low in 12 cases (60%) and MMP-9 expression is high in 8 cases (40%).

Oral squamous cell carcinoma is common in males constitute 38 cases. Out of 38 cases, MMP-9 expression is low in 24 cases (63.2%) and MMP-9 expression is high in 14 cases (36.8%).

In stage I and II the expression of MMP-9 is low in 37 cases (82.22%) and in stage III the expression is high in 14 cases (70%) with P value <0.05 (significant).

Moderately differentiated squamous cell carcinoma constitutes 35 cases. Out of 35 cases, MMP-9 expression is low in 15 cases (42.86%) and high expression in 20 cases (57.14%). In well differentiated carcinoma in 28 cases the expression was low. High expression of MMP-9 is seen in association with high grade and stage of tumor, with presence of risk factors.

DISCUSSION

In the present study, majority of the squamous cell carcinomas of oral cavity were found in the fifth decade of life, 41- 50 years of age group comprising 28.4% of all age groups followed by 61-70 years of age. In the 7th decade there were 20 cases comprising 22.74% of all cases.

This study correlated with that of Vaidhehi Narayan Nayak et al which includes 145 histologically diagnosed cases of oral squamous cell carcinoma where highest incidence was found in fifth decade, 40-49 years age group followed by 60-69 years of age group and 7th decade.⁵

In the study done by Bushra Ayaz et al, which included 268 oral mucosal biopsies, out of these 256 cases are oral squamous cell carcinoma, majority of cases occurred in 7th decade which correlated with second highest peak in the present study.⁶ Males are commonly affected by squamous cell carcinoma of oral cavity accounting for 52 cases that is 59.1% of all cases and females constitute 36 cases that is 40.9% of all cases with a male:female ratio of 1.4:1. Risk factors are absent in 2 cases, these 2 cases showed low expression of MMP-9 (100%). This showed statistically significant correlation (Table 4).

Table 4: Significance of prognostic factors in relation to MMP-9 expression.

Prognostic factors	No. of cases (n=65)	MMP-9 expression		“P” value
		Low	High	
Age	<50 years	37	22	Insignificant
	>50 years	28	21	
Sex	Male	38	24	Significant
	Female	27	19	
Risk factors	Present	63	41	Significant
	Absent	2	2	
Stage of tumor	Stage III	20	6	Significant
	Stage I and II	45	37	
Histological grade	Well differentiated	30	28	Significant
	Moderately differentiated	35	15	
Size	<4cm	42	38	Insignificant
	>4cm	23	5	

The present study correlated with study done by Bushra Ayaz et al where frequency of oral cancers in males constitute 162 cases and females constitute 106 cases

with a male:female ratio of 1.52:1 which were similar to study done by Ayesha Zulfiqar et al male patients are 21

and females patients are 18 with a male: female ratio of 1.2:1 (Table 5).^{6,7}

Table 5: Comparison of present study with other studies with respect to gender distribution in Squamous cell carcinoma of oral cavity.

Name of the author	No. of males	No. of females	Male: Female ratio
Ayaz B et al ⁶	162	106	1.52:1
Zulfiqar A et al ⁷	21	18	1.2:1
Tadbir AA et al ¹⁴	28	14	2:1
Hai-Xia F et al ¹³	36	12	3:1
Amado FM et al ¹¹	36	5	7.2:1
Nayak VN et al ⁵	65	80	0.72:1
Present study	52	36	1.4:1

The commonest site of oral squamous cell carcinoma is tongue which correlated with Bushra Ayaz et al which included 268 cases of oral mucosal biopsies the commonest site of oral squamous cell carcinoma is tongue (44%) (Table 6).⁶

Table 6: Comparison of present study with other studies with respect to commonest site in squamous cell carcinoma of oral cavity.

Name of the author	No. of cases	Commonest site
Ayaz B et al ⁶	268	Tongue (44%)
Zulfiqar A et al ⁷	39	Tongue (23.1%)
Pires FR et al ⁸	346	Tongue (36.2%)
Nayak VN et al ⁵	145	Buccal mucosa (30.4%)
Ravi DK et al ¹²	100	Buccal mucosa (44%)
Present study	88	Tongue (53.4%)

Several other recent studies have shown an increase in the number of affected females, with a mean male: female ratio lower than 2:1, probably due to changes in social and daily activities associated to modern women social profile and way of living, leading to higher exposure to carcinogenic agents, such as tobacco and alcohol consumption and exposure to biological agents, such as high-risk HPV subtypes.⁸

In the present study, ulceroproliferative growth accounts for 45.45% of all the cases of squamous cell carcinoma of oral cavity which is followed by fungating growth (43.18%). The present study is in correlation with that of Nayak VN et al, Kuriakose et al and Manuel et al were the commonest clinical presentation is ulceroproliferative growth.^{5,9,10}

Moderately differentiated squamous cell carcinoma of oral cavity is commonly encountered and it constitute 45 cases out of 88 cases that is 51.1% of all cases and well differentiated squamous cell carcinoma constitute 43 cases out of 88 cases that is 48.9% of all cases. In the study done by Bushra Ayaz et al, most cases of oral

squamous cell carcinoma were moderately differentiated that is 128 cases (47.76%), 116 cases (43.28%) cases were well differentiated which correlated with the present study (Table 7).⁶

Table 7: Comparison of present study with other studies with respect to histological differentiation in squamous cell carcinoma of oral cavity.

Name of the author	Well differentiated	Moderately differentiated	Poorly differentiated
Zulfiqar A et al ⁷	25.6%	51.3%	23.1%
Ayaz B et al ⁶	43.28%	47.76%	5.97%
Pires FR et al ⁸	30.7%	45.5%	23.8%
Nayak VN et al ⁵	57.9%	34.4%	7.5%
Amado FM et al ¹¹	51.2%	36.6%	12.2%
Hai-Xia F et al ¹³	50.0%	41.7%	8.3%
Present study	48.9%	51.1%	-

In this study, MMP-9 expression is studied in 65 cases out of 88 cases. MMP-9 expression is low in most of the cases accounting upto 66.1% of total cases and high in 33.9% of total cases (Table 8).

Table 8: Comparison of present study with other studies with respect to MMP-9 expression in Squamous cell carcinoma of oral cavity.

Name of the author	Total no. of cases	Low expression of MMP-9	High expression of MMP-9
Tadbir AA et al ¹⁴	42	14 (50%)	14 (50%)
Ravi DK et al ¹²	100	25 (25%)	75 (75%)
Hai-Xia F et al ¹³	48	15 (31.25%)	33 (68.75%)
Amado FM et al ¹¹	41	27 (65.85%)	14 (34.15%)
Present study	65	43 (66.15%)	22 (33.85%)

In the study done by Monteiro-Amado F et al, included 41 cases of squamous cell carcinoma of oral cavity. Of these MMP-9 expression is low in 27 cases out of 41 cases (65.85%) and MMP-9 expression is high in 14 cases out of 41 cases (34.15%) which correlated with the present study.¹¹

In the study done by Ravi DK et al, 100 cases of squamous cell carcinoma of oral cavity are studied. Out of this MMP-9 expression is low in 25% of all cases and high in 75% of all cases similarly in the study done by Hai-Xia F et al, included 48 cases of squamous cell carcinoma of oral cavity, MMP-9 expression is low in 31.25% of all cases and high in 68.75% of all cases and did not correlate with the present study.^{12,13}

In the study done by Andisheh-Tadbir A et al, included 42 cases of squamous cell carcinoma of oral cavity. MMP-9 expression is low in 50% of tumours and high in 50% of tumours that is not correlated with the present study.¹⁴

In the present study, reverse smoking only is seen in 18 cases. Out of 18 cases, MMP-9 expression is low in 11 cases (61.11%) and high in 7 cases (38.89%). Smoking with alcohol is seen in 14 cases. Out of 14 cases, MMP-9 expression is low in 10 cases (71.42%) and MMP-9 expression is high in 4 cases (28.58%). Tobacco chewing with alcohol is seen in 14 cases. Out of 14 cases, MMP-9 expression is low in 8 cases (57.14%) and MMP-9 expression is high in 6 cases (42.86%). Smoking only is seen in 2 cases. Out of these 2 cases, MMP-9 expression is low in 1 case (50%) and high in 1 case (50%).

In the study done by Mishev G et al, 61 patients who had been suffering from oral squamous cell carcinoma are

studied. Of these smoking habits are present in 52 cases (85%) and smoking is absent in 9 cases (15%).²

In the present study, lymph node metastasis is present in 20 cases of squamous cell carcinoma of oral cavity. Out of 20 cases, MMP-9 expression is low in 6 cases (30%) and high in 14 cases (70%) (Table 9). Lymph node metastasis is absent in 45 cases. Out of 45 cases, MMP-9 expression is low in 37 cases (82.23%) and high in 8 cases (17.77%). This showed a statistically significant correlation. In the present study, in stage I and II the expression of MMP-9 is low in 37 cases (82.22%) and in stage III the expression is high in 14 cases (70%) with P value <0.05 (significant).

Table 9: Correlation of lymphnode metastasis and MMP-9 expression in oral squamous cell carcinoma.

Name of the author	Total no. of cases	Nodal status	Low expression of MMP-9	High expression of MMP-9	Significance
Tadbir AA et al ¹⁴	42	N ₀ = 21	14 (66.7%)	7 (33.3%)	Significant
		N ₊ = 21	0	21 (100%)	
Ravi DK et al ¹²	100	N ₀ = 15	15 (100%)	0	Significant
		N ₊ = 85	10 (11.77%)	75 (88.23%)	
Hai Xia F et al ¹³	48	N ₀ = 11	8 (72.73%)	3 (27.27%)	Significant
		N ₊ = 37	7 (18.92%)	30 (81.08%)	
Amado FM et al ¹¹	41	N ₀ = 18	14 (77.8%)	4 (22.2%)	Insignificant
		N ₊ = 23	13 (53.5%)	10 (43.5%)	
Present study	65	N ₀ = 45	37 (82.2%)	8 (17.8%)	Significant
		N ₊ = 20	6 (30%)	14 (70%)	

Table 10: Comparison of histopathological differentiation of squamous cell carcinoma of oral cavity and MMP-9 expression in oral squamous cell carcinoma.

Name of the author	Histological differentiation	No. of cases	Low expression of MMP-9	High expression of MMP-9	“P” value
Tadbir AA et al ¹⁴	Well differentiated	27	11 (40.7%)	16 (59.3%)	Insignificant
	Moderately differentiated	12	2 (16.7%)	10 (83.3%)	
	Poorly differentiated	3	1 (33.3%)	2 (66.7%)	
Amado FM et al ¹¹	Well differentiated	21	15 (71.4%)	6 (28.6%)	Insignificant
	Moderately, poorly differentiated	20	12 (60%)	8 (40%)	
Present study	Well differentiated	30	28 (93.33%)	2 (6.67%)	Significant
	Moderately differentiated	35	15 (42.85%)	20 (57.15%)	

In the study done by Tadbir AA et al, 42 patients with oral squamous cell carcinoma are studied.¹⁴ Of these 21 cases have lymph node metastasis and 21 cases are without lymph node involvement.

In cases without lymph node involvement MMP-9 expression is low in 14 cases (66.7%) and high in 7 cases (33.3%). In cases with lymph node involvement MMP-9 expression is high in all 21 cases (100%). They found a significant correlation between MMP-9 overexpression and lymph node metastasis that is similar to the findings of the present study (Table 10).

In this study, moderately differentiated squamous cell carcinoma of oral cavity accounts for 35 cases. Out of 35 cases, 15 cases (22.85%) showed low expression of MMP-9 and 20 cases (57.15%) showed high expression of MMP-9. Well differentiated squamous cell carcinoma of oral cavity constitute 30 cases. Out of 30 cases, 28 cases (93.33%) showed low expression of MMP-9 and 2 cases (6.67%) showed high expression of MMP-9.

In the study done by Tadbir AA et al, 42 patients with oral squamous cell carcinoma are studied. Of these well differentiated squamous cell carcinoma of oral cavity are

27 cases (64.3%), moderately differentiated squamous cell carcinoma of oral cavity are 12 cases (28.5%) and poorly differentiated squamous cell carcinoma of oral cavity are 3 cases (7.2%).¹⁴

Among all well differentiated cases low MMP-9 expression is seen in 11 cases (40.7%) and high MMP-9 expression is seen in 16 cases (59.3%), In moderately differentiated cases low MMP-9 expression is seen in 2 patients (16.7%) and high MMP-9 expression is seen in 10 patients (83.3%). In poorly differentiated cases low MMP-9 expression is seen in 1 patient (33.3%) and high MMP-9 expression is seen in 2 patients (66.7%). They did not find any statistical significant correlation between grade of the tumour and MMP-9 expression. Similarly, in the study done by Ravi DK et al, 100 patients with oral squamous cell carcinoma are studied. They observed frequent expression of MMP-9 in Oral Squamous Cell Carcinoma, with 85% of tumor samples expressing the protein.¹²

CONCLUSION

Matrix metalloproteinases 9 (MMP-9) expression was high in stage III tumor and moderately differentiated squamous cell carcinoma which is statistically significant. The expression was also significant when associated with risk factors. Age at presentation has no effect on the expression of MMP-9. Matrix metalloproteinases could act as a therapeutic target, could play an important role in effective treatment strategies of oral cancer.

Funding: No funding sources

Conflict of interest: None declared

Ethical approval: The study was approved by the Institutional Ethics Committee

REFERENCES

1. Massano J, Regateiro FS, Januario G, Ferreira A. Oral squamous cell carcinoma: review of prognostic and predictive factors. *Oral Surg Oral Med Oral Pathol Oral Radiol Endod.* 2006;102:67-76.
2. Mishev G, Deliverska E, Hlushchuk R, Velinov N, Aebersold D, Weinstein F, et al. Prognostic value of matrix metalloproteinases in oral squamous cell carcinoma. *Biotechnol biotechnological equipment.* 2014 Nov 2;28(6):1138-49.
3. Aebersold DM, Beer KT, Laissue J, Djonov V, Greiner RH. Intratumoral microvessel density predicts local treatment failure of radically irradiated squamous cell cancer of the oropharynx. *Int J Radiat Oncol Biol Phys.* 2000;48:17-25.
4. Jayade BV, Bhat K, Patil BR, Nayak R, Sant A. Histological significance of p53 gene expression in squamous cell carcinoma of the buccal mucosa. *J maxillofacial oral surgery.* 2009 Sep 1;8(3):205.
5. Vaidhehi Narayan Nayak et al. Oral squamous cell carcinoma: A 5-years institutional study. *J Med Radiol Pathol Surg.* 2015;1:3-6.
6. Ayaz B, Saleem KH, Azim WA, Shaikh AL. A clinico-pathological study of oral cancers. *Biomedica.* 2011 Jan;27(1):29-32.
7. Zulfiqar A, Nagi AH, Nasim NA. A clinicopathological study of orofacial squamous cell carcinoma in local population. *Biomedica.* 2013 Jul;29(3):147-50.
8. Pires FR, Ramos AB, Oliveira JB, Tavares AS, Luz PS, Santos TC. Oral squamous cell carcinoma: clinicopathological features from 346 cases from a single oral pathology service during an 8-year period. *J App O Sci.* 2013 Oct;21(5):460-7.
9. Kuriakose M, Sankaranarayanan M, Nair MK, Cherian T, Sugar AW, Scully C, et al. Comparison of oral squamous cell carcinoma in younger and older patients in India. *Eur J Cancer B Oral Oncol.* 1992;28B:113-20.
10. Manuel S, Raghavan SK, Pandey M, Sebastian P. Survival in patients under 45 years with squamous cell carcinoma of the oral tongue. *Int J Oral Maxillofac Surg.* 2003;32:167-73.
11. Monteiro-Amado F, Castro-Silva II, Lima CJ, Soares FA, Kowalski LP, Granjeiro JM. Immunohistochemical evaluation of MMP-2, MMP-9 and CD31/microvascular density in squamous cell carcinomas of the floor of the mouth. *Brazilian dental J.* 2013;24(1):3-9.
12. Ravi DK, Kumar M, Singh G, Rai SB, Chincholkar T, Saxena AK, et al. Matrix Metallopeptidase 9 (MMP-9) Expression in Oral Cancer Andand Adjacent Normal Tissue. *World J Surg Med Radia Oncol.* 2014 Dec 15;3(17).
13. Fan HX, Li HX, Chen D, Gao ZX, Zheng JH. Changes in the expression of MMP2, MMP9, and ColIV in stromal cells in oral squamous tongue cell carcinoma: relationships and prognostic implications. *J Exp Clin Can Res.* 2012;31(1):90.
14. Andisheh-Tadbir A, Mardani M, Pourshahidi S, Nezarati K, Bahadori P. Prognostic value of matrix metalloproteinase-9 expression in oral squamous cell carcinoma and its association with angiogenesis. *J Clin Exp Den.* 2016 Apr;8(2):e130.

Cite this article as: Atla B, Prabhakula S, Kumar SS, Boni LS. Matrix metalloproteinase-9 (MMP-9) as prospective histopathological and molecular biomarker for oral squamous cell carcinoma. *Int J Res Med Sci* 2018;6:2801-7.