

## Original Research Article

# Anatomical variations of sphenoid sinus on multi-detector computed tomography and its usefulness in trans-sphenoidal endoscopic skull base surgery

Manisha S. Lokwani<sup>1\*</sup>, Jayant Patidar<sup>2</sup>, Vijay Parihar<sup>2</sup>

<sup>1</sup>Department of Radio-diagnosis, <sup>2</sup>Department of Neurosurgery, N.S.C.B. Medical College, Jabalpur, Madhya Pradesh, India

**Received:** 02 July 2018

**Accepted:** 27 July 2018

**\*Correspondence:**

Dr. Manisha S. Lokwani,

E-mail: [manisha.khimnani@gmail.com](mailto:manisha.khimnani@gmail.com)

**Copyright:** © the author(s), publisher and licensee Medip Academy. This is an open-access article distributed under the terms of the Creative Commons Attribution Non-Commercial License, which permits unrestricted non-commercial use, distribution, and reproduction in any medium, provided the original work is properly cited.

### ABSTRACT

**Background:** Knowledge of sphenoid bone and sinus anatomy and its variations is of central importance in transsphenoidal endoscopic skull base surgery. It allows endoscopic surgeon to safely approach the sella turcica, anterior skull base and orbit. The aim of the study was to evaluate the different anatomical variations of the sphenoid sinus that are relevant to trans-sphenoid endoscopic skull base surgery on multi-detector computed tomography.

**Methods:** A prospective observational study of the CT analysis of the anatomical variations and various dimensions of sphenoid sinus relevant to trans-sphenoidal endoscopic neurosurgery was performed in 260 patients (173 male; 87 female).

**Results:** The average presellar width of sphenoid sinus on axial CT scan images was 11.75mm (7.2 to 18.6mm). Average value of maximum width of sphenoid sinus was 30.52 mm (13.1 to 42.2 mm). The most common pattern of inter-sphenoid septum was single septum which was present in 207 patients (79.61%); double inter sphenoid septum in 47 patients (18.1%) and diverging septa in 13 patients (5%). 138 out of 260 subjects (53%) showed at least one septum attached to either carotid protuberance. Most common pattern of pneumatization in sphenoid sinus was sellar type (63.46%). Average suprasellar depth was 10.78 (5.4 to 18.7mm). Average presellar depth of sphenoid sinus was 13.47mm (8.1 to 22.5mm). Average infrasellar depth of sphenoid sinus was 25.46mm (11.9 to 37.9mm). Average presellar height of sphenoid sinus was 21.27mm (13 to 27.6mm).

**Conclusions:** A preoperative review of the sphenoid sinus anatomy by CT allows safer endoscopic management of skull base pathology preventing injury to vital structures surrounding the sphenoid sinus.

**Keywords:** Anatomical variation, Pneumatization, Septation pattern, Sphenoid sinus, Trans-sphenoidal endoscopic surgery

### INTRODUCTION

Transsphenoidal endoscopic neurosurgery is the current gold standard for surgical resection of sellar and suprasellar tumours. Its extended approach allows resection of middle cranial fossa parasellar masses and even clival and petrous lesions.<sup>1-4</sup>

A detailed preoperative knowledge of relevant surgical anatomy of sphenoid sinus and its anatomical variations by means of neuroimaging is of vital importance and a necessary requisite to transsphenoidal endoscopic skull base surgery. It allows the endoscopic surgeon to safely approach the sella turcica, anterior skull base and orbit.

Although there are several reports about the sphenoid sinus morphometry and septal pattern analysis, no CT study has been carried out in our country.

Aim of the research work was to study presellar width and maximum width of sphenoid sinus in axial CT scan images and to study presellar height, suprasellar depth, infrasellar depth, presellar depth on sagittal CT images. Also, to study pattern of septation (absent, single, double, divergent) and to study extent of pneumatization of sphenoid sinus (Presellar, sellar, postsellar).

## METHODS

Following approval by the institutional ethical committee, a prospective observational study was conducted on 260 patients of age more than 15 years who underwent for CT scan head for traumatic or non-traumatic aetiology over a period of one year.

### Sampling technique and sample size

About 260 patients who underwent CT scan head were chosen as per the following criteria.

### Inclusion criteria

All patients of age of 15 years or more, who underwent thin section CT scan head on 128 slice Optima scanner (GE Healthcare, USA) for traumatic or non-traumatic pathology.

### Exclusion criteria

- Disease or tumor involving sella or skull base.
- Patients with skull base fracture.
- Any congenital anomaly involving sella or skull base.
- Patient who underwent surgery for sella or skull base.

### Procedure

Axial and sagittal images of sphenoid sinus were obtained and analyzed for various parameters described below. Average distances were calculated using Microsoft Excel software (Microsoft Corp., Redmond, Washington, United States). Parameters studied were as follows:

#### In axial CT scan images

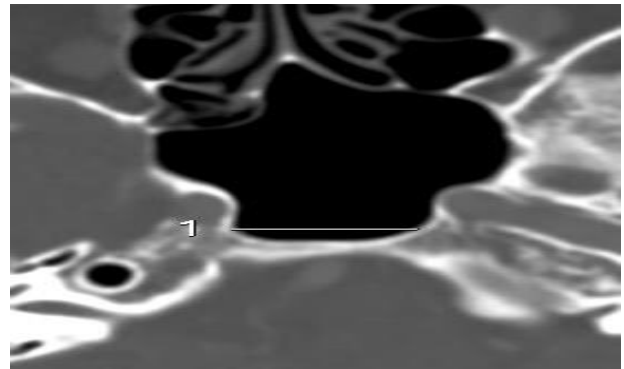
- Immediate presellar width of sphenoid sinus
- Maximum width of sphenoid sinus
- Pattern of septation (absent, single, double and /or divergent)
- Attachment of main or accessory septum to carotid protuberance.

#### On sagittal CT scan image

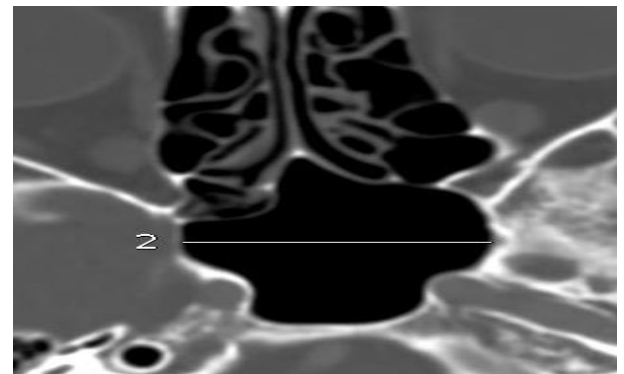
- Suprasellar depth
- Presellar depth
- Infrasellar depth
- Presellar height
- Extent of pneumatization (conchal, presellar, sellar or postsellar).

#### Methods of measurement of different parameters

The presellar width of sphenoid sinus is width measured just in front of sella turcica (anterior sellar wall) on axial images (Figure 1).



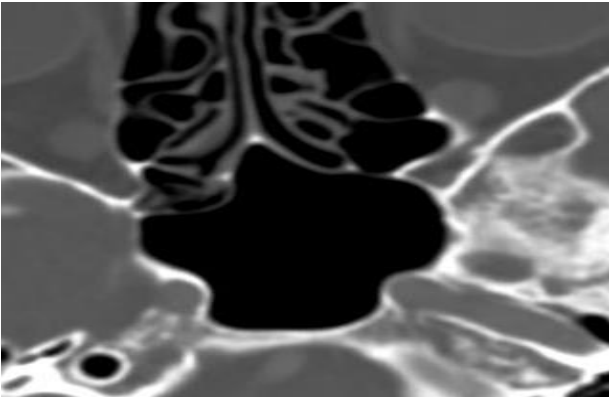
**Figure 1: Axial CT scan of sella (bone window) showing measurement of presellar width of sphenoid sinus just in front of sella turcica (anterior sellar wall).**



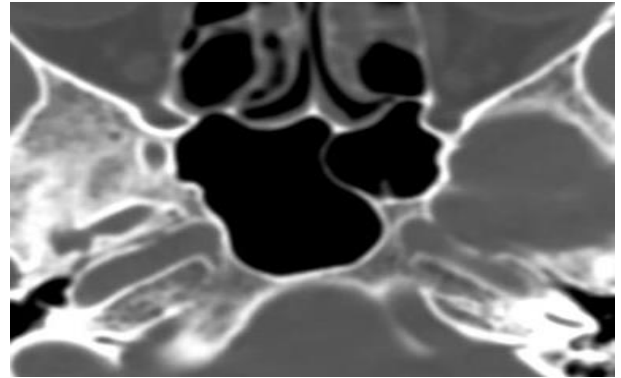
**Figure 2: Axial CT scan of sella (bone window) showing maximum width of sphenoid sinus.**

Maximum width of sphenoid sinus on axial image is distance measured between two most distal parts of sinus (Figure 2).

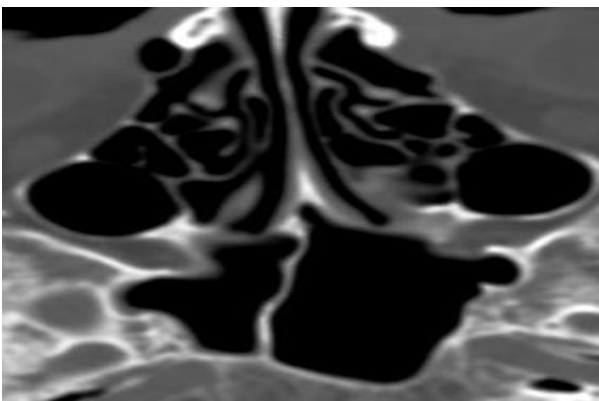
Pattern of septation: the main inter-sphenoid septum may be single, double or absent. Divergence of septa was noted. (Figure 3, 4 and 5). Note was also made of the attachment of the main or accessory septum to the carotid protuberance (Figure 6 and 7).



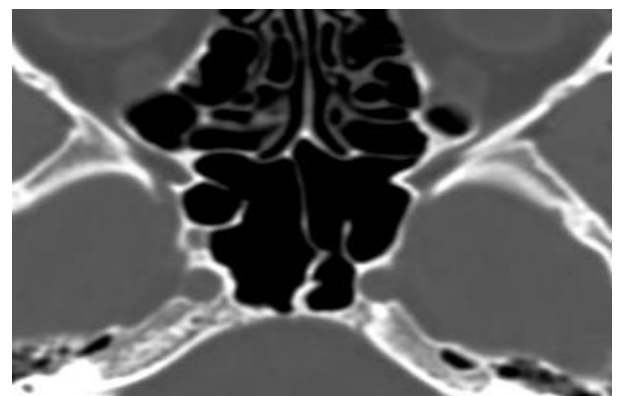
**Figure 3: Axial CT scan of sella (bone window) showing absent inter-sphenoid septum.**



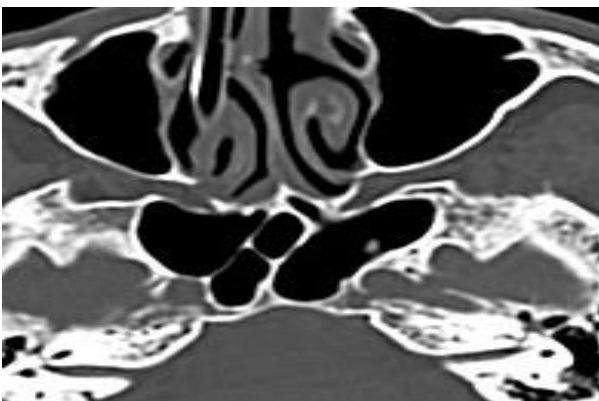
**Figure 6: Axial CT image of sella (bone window) showing attachment of the main septum to the left carotid protuberance.**



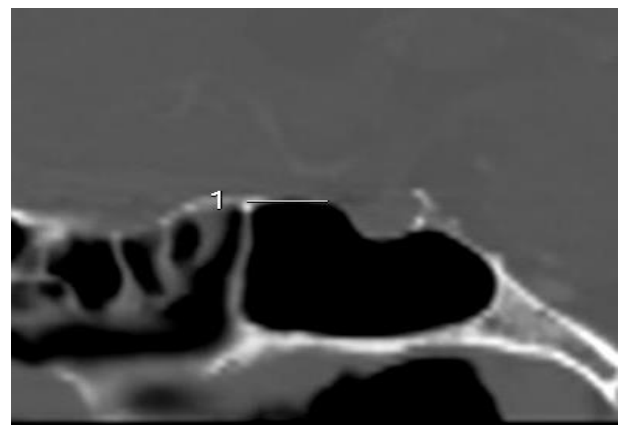
**Figure 4: Axial CT scan of sella (bone window) showing single inter-sphenoid septum.**



**Figure 7: Axial CT image of sella (bone window) showing attachment of the main septum to the posterior sellar wall and accessory septum attached to the left carotid protuberance.**



**Figure 5: Axial CT scan of sella (bone window) showing double and diverging inter-sphenoid septa.**

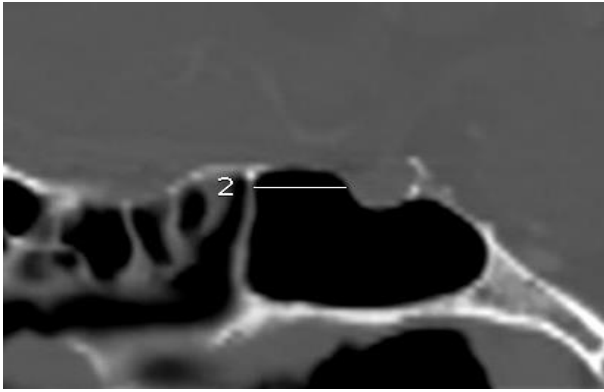


**Figure 8: Sagittal reformatted image of sella (bone window) showing measurement of suprasellar depth of sphenoid sinus.**

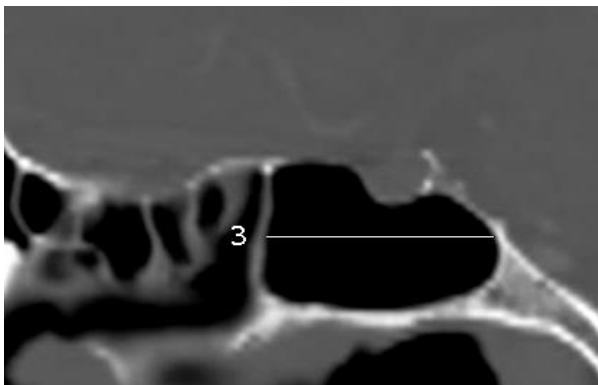
The suprasellar depth is A-P distance measured at most superior extent of sinus on midline sagittal images (Figure 8).

The presellar depth is A-P distance measured at vertical midpoint of the anterior face of sella turcica on sagittal images (Figure 9).

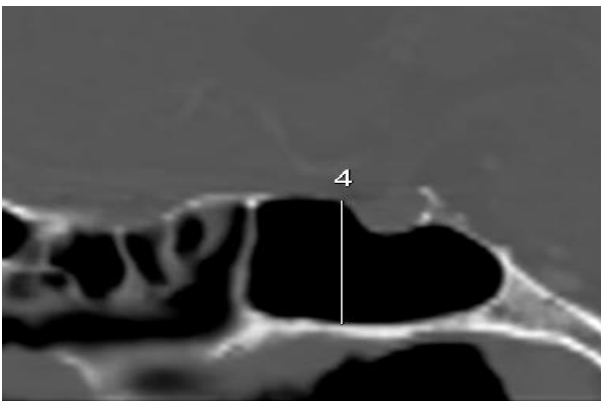
The infrasellar depth is the maximum A-P distance below the sella at most posterior extent of sinus on sagittal images (Figure 10).



**Figure 9: Sagittal reformatted image of sella (bone window) showing measurement of presellar depth.**



**Figure 10: Sagittal reformatted image of sella (bone window) showing measurement of infrasellar depth.**



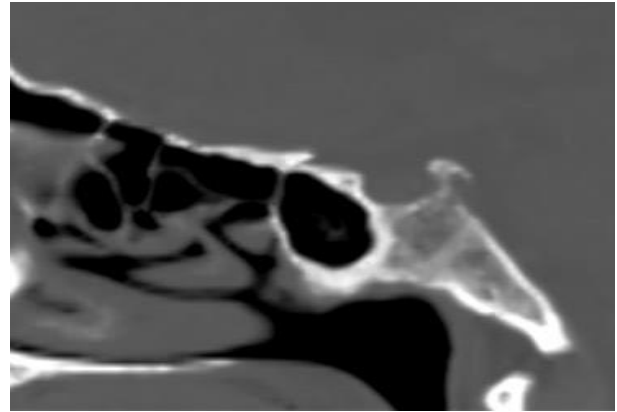
**Figure 11: Sagittal reformatted image of sella (bone window) showing measurement of presellar height of sphenoid sinus.**

The presellar height is distance measured from floor of sinus up to superior extent of sinus in front of anterior sellar wall on sagittal images (Figure 11).

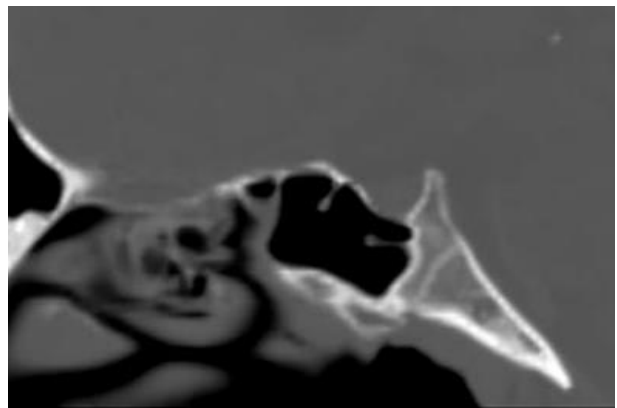
#### ***Extent of pneumatization***

The classification for sphenoid sinus pneumatization given by Hamberger et al and Hammer et al is still widely used and is as follows:<sup>5,6</sup>

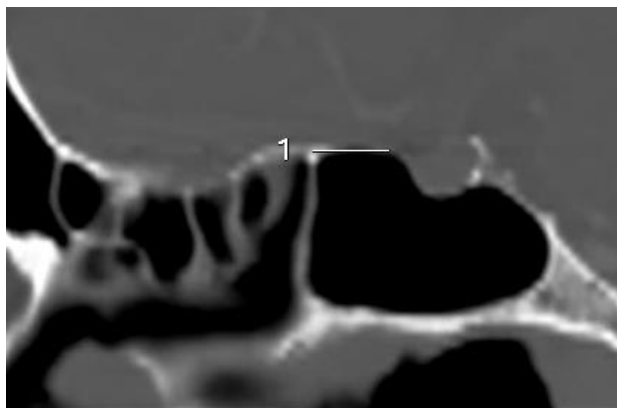
Conchal or fetal type: The thickness of bone between the sphenoid sinus and the sella exceeds 10 mm and this type is highly uncommon in adults. The area below the sella is a solid block of bone with a small air cavity. It is most common in children before the age of 12 years.



**Figure 12: Sagittal reformatted image of sella (bone window) showing pre-sellar pneumatization.**



**Figure 13: Sagittal reformatted image of sella (bone window) showing sellar type of pneumatization.**



**Figure 14: Sagittal reformatted image of sella (bone window) showing post-sellar type of pneumatization.**

Presellar: The sinus cavity does not penetrate beyond a vertical tangent from the anterior sellar wall (Figure 12).

Sellar: The sinus cavity extends into the body of sphenoid below the sella (Figure 13).

Postsellar: The air cavity extends beyond a vertical tangent drawn from the posterior sellar wall (Figure 14).

**RESULTS**

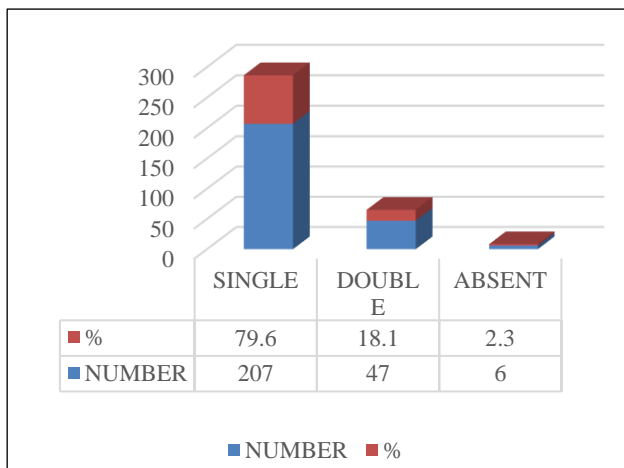
The study was conducted in 260 patients who came to our institution and underwent CT scan head for traumatic or non-traumatic brain pathology fulfilling the inclusion and exclusion criteria (Age range 15-86 years). Out of 260 patients, 173 (66.5%) were male and 87 (33.45%) were female.

Most common pattern of pneumatization in sphenoid sinus was sellar type (63.46%) followed by post-sellar type (28.46%). Conchal type of pneumatization was not seen in any of the cases. Extent of pneumatization is summarised in Table 1.

**Table 1: Extent of pneumatization of sphenoid sinus.**

Type of pneumatization	Number out of 260	Percentage
Presellar	21	8.07%
Sellar	165	63.46%
Postsellar	74	28.46%

Out of the 260 patients observed, the most common pattern of inter-sphenoid septum was single septum which was present in 207 patients (79.61%). Double inter-sphenoid septa were present in 47 patients (18.1%) and no inter-sphenoid septum in 6 (2.3%) patients (Figure 15) and diverging septa were present in 13 patients (5%).



**Figure 15: Pattern of septation of sphenoid sinus.**

A total of 138 out of 260 subjects (53%) showed at least one intersphenoid septum attached to either carotid protuberance (ICAp). Out of 138, 78 subjects (57%) showed attachment of at least one septum on the left carotid protuberance (Lt ICAp) and 60 subjects (43%)

showed attachment of at least one septum on the right carotid protuberance (Rt ICAp). Forty-four out of seventy-eight subjects (56%) showed attachment of the main sphenoid septum to the left. Thirty-four showed attachment of accessory septum to the left. Thirty-nine out of sixty subjects showed attachment of the main sphenoid septum to the right and twenty-one showed attachment of accessory septum to the right (Table 2).

**Table 2: Attachment of intersphenoid septa to carotid protuberance.**

Site of attachment	LT ICAp		RT ICAp	
	Main	Accessory	Main	Accessory
Septa				
Number	44	34	39	21
Total	78		60	
Total	138 out of 260 (53%)			

On axial CT images, the average presellar width of sphenoid sinus was 11.75mm, ranging from 7.2 to 18.6mm on axial CT scan images. Average value of maximum width of sphenoid sinus on axial CT scan images was 30.52mm, ranging from 13.1 to 42.2mm.

On sagittal section of CT head the average suprasellar depth was 10.78, ranging from 5.4 to 18.7mm. Average value of presellar depth of sphenoid sinus was 13.47mm ranging from 8.1 to 22.5mm in sagittal section. Average value of infrasellar depth of sphenoid sinus was 25.46mm, ranging from 11.9 to 37.9mm. Average value of presellar height of sphenoid sinus was 21.27mm ranging from 13 to 27.6mm.

**DISCUSSION**

The sphenoid bone consists of body, greater and lesser wings and pterygoid plate. Sphenoid sinus is formed in the body of sphenoid bone and it is located at the skull base at the junction of anterior and middle cranial fossa. It separates the cavernous sinuses, the cavernous segments of the carotid arteries, and the oculomotor, trochlear, and trigeminal nerves. In addition, it separates the pituitary gland from the nasal cavity.<sup>7</sup>

Nowadays endoscopic neurosurgery via the endonasal transsphenoidal approach is widely used as a minimally invasive surgery for resection of not only sellar and suprasellar tumours but also for clival and parasellar masses.<sup>1-4</sup> Through this approach, the nasal cavity and sphenoid sinus are used to access the centre of the base of the skull, the sella turcica, and the parasellar region. The anterior wall of the sphenoid sinus along with rostrum is resected. Sinus septum, which is often located lateral to the sagittal plane, and the sphenoid sinus mucosa are removed. After thorough inspection of sphenoid sinus and sellar floor, the latter is perforated by means of a drill/chisel if the floor is thick and by a blunt nerve hook

if the floor is thin. Then dura is penetrated in order to access to the sellar and parasellar region.<sup>8</sup>

Pre-operative CT has become mandatory in such patients to know about the detailed anatomy of sella and sphenoid sinus. The present study aims to provide useful information about the sphenoid sinus anatomy, its anatomical variations and shows how this information is useful to an endoscopic neurosurgeon.

The development of sphenoid sinus starts between 3<sup>rd</sup> and 4<sup>th</sup> month of fetal development. Between birth and 3 years of age, the sphenoid sinus is primarily a pit in the sphenothmoid recess.<sup>9,10</sup> Pneumatization of sphenoid starts at age 3 year, extends towards sella turcica by age 7year, and reaches its final form by the age of 14 years.<sup>10</sup> The different types of sphenoid sinus in the adult are conchal, presellar, sellar and postsellar types, depending on the extent to which the sphenoid bone is pneumatized.<sup>5,6</sup>

**Conchal type or fetal type:** The thickness of bone between the sphenoid sinus and the sella exceeds 10 mm is highly uncommon in adults. The area below the sella is a solid block of bone with a small air cavity. The conchal type is most common in children before the age of 12 years, at which time pneumatization begins within the sphenoid sinus.<sup>5,6,10,11</sup>

**Presellar type or juvenile type:** It is the second most common type (10- 25%) and the air cavity does not penetrate beyond a vertical plane parallel to the anterior sellar wall (Figure 12).<sup>5,6,10,11</sup>

**Sellar type or adult type:** This is the most frequent type (75-86%) of sinus in which the air cavity extends into the body of sphenoid below the sella upto the posterior sellar wall (Figure 13).<sup>5,6,10,11</sup>

**Postsellar type:** The air cavity extends beyond the posterior sellar wall (Figure 14).<sup>5,6,10,11</sup>

### ***Surgical implications of pneumatization, depth and septal pattern of sphenoid sinus***

If the pneumatization is conchal type or the sinus is non-pneumatized, transsphenoidal approach can be difficult due to the amount of bone present between the sphenoid face and the sellar/parasellar region. However, with the surgeon informed preoperatively, approach is made feasible by different tools like use of punches to remove the cancellous bone after drilling of sellar floor. An alternative route like transcranial route is preferred if the tumour is large and beyond the intrasellar region in above cases.<sup>12</sup>

In pre-sellar type there is no bulge of the sellar floor into the sphenoid sinus, pneumatization extends only as far as the tuberculum sellae.<sup>5</sup> The presellar variant also (like the conchal type) requires drilling of bone in order to reach

the sellar floor.

In sellar type of sphenoid sinus, pneumatization extends beyond the tuberculum sella into the body of the sphenoid. Therefore, it is a favourable type for transsphenoidal approach.<sup>12</sup>

Sphenoid sinus is surrounded by vital structures laterally such as internal carotid artery, optic nerve and cavernous sinus. In post-sellar type of sphenoid sinus, the bone covering the carotid artery, optic nerve, maxillary nerve and vidian nerve, can be thin or even absent, making these structures susceptible to iatrogenic injury. Also, if pneumatization extends into dorsum sella (hyperpneumatization), there are chances of penetration of posterior sphenoid wall which may result in CSF leak because of entry into the middle cranial fossa.<sup>12</sup> However, there is an advantage to this anatomical variation as well. Extended pneumatization into the lesser or greater wing of sphenoid or pterygoid process or clivus allows facilitation of extended surgical approaches by providing natural corridors to access skull base lesions in the corresponding areas (e.g. planum sphenoidale, olfactory groove, clivus, craniovertebral junction, or anterior portion of the foramen magnum).<sup>13</sup>

The depth of the sphenoid sinus is defined as the distance from the ostium of the sphenoid sinus to the closest part of the sella. In adults, the average anterior-posterior diameter of the cavity has been found to be 17mm (range, 12-23mm). This measurement defines the length of the path within the sinus through which instruments must pass to reach the sellar wall and is important when selecting instruments for transsphenoidal surgery. The speculum most commonly used for transsphenoidal surgery is 9cm in length and its tip should be placed anterior to the sphenoid sinus. In reaching the floor of the sella turcica, the depth of the sphenoid sinus (2cm or more) is added to the 9cm length of the speculum. Thus, after traversing a distance of 11 to 12cm, the dissecting instruments must then enter the sella turcica and be able to reach above the sella if a suprasellar tumour is present. The distance may be greater in the presence of acromegaly; therefore, it is important that transsphenoidal instruments have shafts at least 12cm in length.<sup>12</sup>

The septa within the sphenoid sinus vary greatly in size, shape, thickness; location, completeness, relation to the sellar floor and attachment to the carotid protuberance. The cavities within the sinus are usually asymmetrical from side to side and are often subdivided by irregular minor septa. The septa are often located off the midline as they cross the floor of the sella.<sup>11</sup>

Septation of the sphenoid sinus also influences surgical planning. Number of septa is important as removal of additional septa increases surgical exposure. The bony attachment of the septum is also surgically important whether it is attached to the carotid protuberance or the lateral wall of sphenoid sinus. If preoperatively the

surgeon knows that the septum is attached to carotid protuberance, those septa are not detached from their lateral attachment so that carotid artery is not injured.

Extent of pneumatization: In our study we observed three types of pneumatization, presellar, sellar, and post sellar. Presellar pneumatization was seen in 8.07% patients, sellar in 63.46% patients, and postsellar pneumatization in 28.46% patients. Conchal type of sphenoid sinus was not seen in our study.

Ossama Hamid et al, used CT and MRI and found that pneumatization was presellar in 21% cases, sellar in 54.7% cases and was post sellar in 22.3% cases.<sup>13</sup> In a CT study done by Wiebracht ND et al, they found that pneumatization was presellar in 9% cases, sellar in 37% cases, and 54% had postsellar pneumatization, with post sellar pneumatization being the most common pattern.<sup>14</sup> Sareen D et al, conducted study on cadaveric skulls and divided pneumatization in presellar and postsellar type, and observed that, the pneumatization was presellar in 25% cases and was post sellar in 75% cases.<sup>15</sup> In a CT study on Nigerian adults by Idowu OE et al, they found, the pneumatization was presellar in 5% cases, sellar in 83% cases and was post sellar in 6.7% cases.<sup>16</sup>

Sevinc O et al, conducted MRI study on Turkish population, observed the pattern of pneumatization in 616 patients and divided the pneumatization in conchal, presellar and sellar type.<sup>17</sup> Sellar type of pneumatization pattern was present in 511 patients (83%), presellar pattern was found in 102 patients (16.6%), and 3 patients had conchal type of sphenoid sinus (0.5%). A CT study done on cadaveric skulls done in Karnataka (India) by Vidya CS et al, showed sellar type of pneumatization in

85% cases, presellar type in 10% and post sellar type in 5%.<sup>18</sup> Table 3 summarises the comparison of data on extent of pneumatization of various studies.

**Table 3: Comparison of extent of pneumatization of sphenoid sinus in various studies.**

Study	Presellar	Sellar	Postsellar
This study	8.07%	63.4%	28.4%
Hamid O et al <sup>13</sup>	21%	54.7%	22.3%
Wiebracht ND et al <sup>14</sup>	9%	37%	54%
Sareen D et al <sup>15</sup>	25%	-	75%
Idowu OE et al <sup>16</sup>	5%	83%	6.7%
Sevinc O et al <sup>17</sup>	-	83%	16%
Vidya CS et al <sup>18</sup>	8%	85%	5%

**Pattern of septation**

In this study, we observed that there was no inter sphenoid septum in 2.3% cases, single inter sphenoid septum in 79.6% cases, double septa in 18.1% and diverging septa in 5% cases.

Ossama Hamid et al, observed that 10.8% cases had no intersphenoid septum, single septum was present in 71.6% cases, two septa in 10.8% cases and multiple septa in 6.8% cases.<sup>13</sup> Wiebracht ND et al, found that out of the 90 patients studied, in 4% cases there was no inter sphenoid septum, single septum was present 83% cases, two septa in 3% cases, and in 9%, the septum diverged posteriorly.<sup>14</sup> Idowu OE et al, observed that only one patient in their series had no inter-sphenoid septum, and 95% cases had a single septum.<sup>16</sup>

**Table 4: Comparison of septation pattern of sphenoid sinus observed in various studies.**

Study	Absent	Single	Double	Diverging	Multiple
This study	2.3%	79.6%	18.1%	5%	-
Wiebracht ND et al <sup>14</sup>	4%	75%	3%	8%	-
Hamid D et al <sup>13</sup>	10.8%	71.6%	10.8%	-	6.8%
Sareen D et al <sup>15</sup>	-	20%	-	-	80%

From these studies we can conclude that most of the sphenoid sinuses have single inter-sphenoid septum. Septation pattern gives relevant information for surgical planning in trans- sphenoidal skull base surgery.<sup>1</sup> Table 4 summarises the comparison of data on septation pattern of various studies.

In this series, 53% showed atleast one septum attached to either carotid protuberance. This figure is quite similar to the study of CT scan of 421 patients done by Ramalho CO et al, who found prevalence of 52%.<sup>19</sup> Fernandez-Miranda et al, showed radiologic prevalence of 85% among patients with at least one septation attached to

carotid protuberance.<sup>20</sup> Other studies have quoted lower figures in this respect. Renn and Rhoton found intersphenoid septa next to the ICA channel in 32% of cadavers.<sup>21</sup> Sethi in 1995 described intersphenoid septa attached to carotid protuberance in 40% of 30 cadavers in an endoscopic study.<sup>22</sup> Abdullah et al, in 2001 and Unal et al in 2006 reported 31% and 30% of septa of the sphenoid sinus attached to the wall of the ICA, respectively, using CT scans.<sup>23,24</sup> Hamid et al, showed frequencies of 4.7% and 6.75% for intersphenoid and accessory septa attached to internal carotid protuberance, respectively.<sup>13</sup>

## Dimensions

In this study we found that the average value of pre-sellar width in axial CT scan images was 11.75mm (range from 7.2-18.6mm), average value of maximum width of sphenoid sinus was 30.52mm, (range from 13.1-42.4mm). Presellar height on sagittal section of CT scan head, we observed that the average value was 21.27mm (range from 13-27.6mm), suprasellar depth was 10.78mm (range from 5.4-18.7mm), pre-sellar depth was 13.47mm (range from 8.1-22.5mm), infra sellar depth was 25.46mm, (range from 11.9-37.47mm).

Whereas in the study conducted by Wiebracht et al ND, in American population, they observed that presellar

width of the sphenoid sinus was 13mm (4mm-25mm), with a maximum width of 35mm (19mm-70mm).<sup>14</sup> The presellar height was 23mm (12mm-36mm). The suprasellar depth was 13mm (4mm-28mm), the presellar depth was 14mm (4-26mm), and the infrasellar depth was 26mm (6-40mm).

An Indian study done on cadaveric skulls by Sareen D et al, showed that the mean A-P diameter of the sinuses was 25mm (13 to 34mm).<sup>15</sup>

Mean transverse diameter of the sinuses was 28mm (12 to 50mm). Mean Vertical diameter of the sinuses was 22mm (14 to 36mm). Table 5 summarises the data of various studies.

**Table 5: Comparison of dimensions of sphenoid sinus observed in various studies.**

Study	PSW	MW	SSD	PSD	ISD	PSH
Our study	11.75mm	30.52mm	10.78mm	13.47mm	25.46mm	21.27mm
ND Wiebracht et al <sup>14</sup>	13mm	35mm	13mm	14mm	26mm	23mm

In various studies we found that dimensions of sphenoid sinus vary greatly from population to population.

## CONCLUSION

In this study, we observed that sphenoid sinus is a highly variable structure, in relation to septation pattern, extent of pneumatization and various A-P, transverse and vertical dimensions of sinus. Anatomy varies from person to person and variation exists in the population of different geographic area. With advances in endoscopic neurosurgical skills, a thorough preoperative assessment of relevant surgical anatomy of sphenoid sinus by CT has become necessary. It allows detection of anatomical variations, dimensions and the problems to be anticipated during the endonasal trans-sphenoidal approach.

The study was easy to perform, has high reliability, has no added cost, and can be easily duplicated at other centres and for paediatric age groups. A better understanding of anatomy of sphenoid sinus will result in better outcome and lesser complication rate related to trans-sphenoid skull base surgery.

## ACKNOWLEDGEMENTS

Authors would like to thank Dr. YR Yadav, Head of Department of Neurosurgery, Netaji Subhash Chandra Medical College, Jabalpur, Madhya Pradesh, Dr. Sonjjay Pande, Head of Department of Radio-diagnosis, Netaji Subhash Chandra Bose Medical College, Jabalpur, Madhya Pradesh and Dr. Pushpraj Bhatele, Chief Consultant Radiologist, M.P. MRI and CT scan centre, Jabalpur, Madhya Pradesh for giving highly valued

guidance and being a great support in completion of study.

*Funding: No funding sources*

*Conflict of interest: None declared*

*Ethical approval: Not required*

## REFERENCES

1. Abuzayed, B, Tanriover N, Gazioglu N, Ozlen F, Cetin G, Akar Z. Endoscopic anatomy and approaches of the cavernous sinus: cadaver study. *Surg Radiol Anat.* 2010;32(5):499-508.
2. Kim EH, Ahn JY, Kim SH. Technique and outcome of endoscopy-assisted microscopic extended transsphenoidal surgery for suprasellar craniopharyngiomas. *J Neurosurg.* 2011;114(5):1338-49.
3. Zanation AM, Snyderman CH, Carrau RL, Gardner PA, Prevedello DM, Kassam AB. Endoscopic endonasal surgery for petrous apex lesions. *Laryngoscope.* 2009;119(1):19-25.
4. Ceylan S, Koc K, Anik I. Extended endoscopic approaches for midline skull-base lesions. *Neurosurg Rev.* 2009;32(2):309-19.
5. Hamberger CA, Hammer G, Norlen G, Sjogren B. Transantrosphenoidal hypophysectomy. *Arch Otolaryngol.* 1961;74:2-8.
6. Hammer G, Radberg C. The sphenoidal sinus: an anatomical and roentgenologic study with reference to transsphenoid hypophysectomy. *Acta Radiol.* 1961;56(6):401-22.
7. Gray H. *Gray's anatomy.* 40th ed. Edinburgh: Churchill Livingstone; September 2008.



8. Zada G, Agarwalla PK, Mukundan S, Jr, Dunn I, Golby AJ, Laws ER. The neurosurgical anatomy of the sphenoid sinus and sellar floor in endoscopic transsphenoidal surgery. *J Neurosurg.* 2011;114:1319-30.
9. Aoki S, Dillon WP, Barkovich AJ and Norman D. Marrow conversion before pneumatization of the sphenoid sinus: Assessment with MR imaging. *Radiology.* 1989;172(2):373-5.
10. Budu V, Mogoantă CA, Fănuță B, Bulescuthe I. Anatomical relations of the sphenoid sinus and their implications in sphenoid endoscopic surgery. *Rom J Morphol Embryol.* 2013;54(1):13-6.
11. Bone anatomy of the nasal cavities and the sphenoid sinus. In Paolo Cappabianca, Luigi Maria Cavallo, editors. *Endoscopic pituitary and skull base surgery Anatomy and surgery of the endonasal approach* 3rd ed. Germany Endo Press; 2016:12.
12. Surgical anatomy of the sellar region. In: Edward R. Laws Jr, Giuseppe Lanzino editors. *Transsphenoidal Surgery E-Book* Saunders Elsevier Health Sciences, Philadelphia, PA, USA; 2010:98.
13. Hamid O, Fiky LE, Hassan O, Kotb A, SE Fiky. Anatomic variations of the sphenoid sinus and their impact on trans-sphenoid pituitary surgery. *Skull Base.* 2008 Jan;18(1):9-15.
14. Wiebracht ND, Zimmer LA. Complex anatomy of the sphenoid sinus: a radiographic study and literature review. *J Neurol Surg B Skull Base.* 2014 Dec;75(6):378-82.
15. Sareen D, Agarwal AK, Kaul JM, Sethi A. Study of sphenoid sinus anatomy in relation to endoscopic surgery. *Int J Morphol.* 2005; 23(3):261-66.
16. Idowu OE, Balogun BO, Okoli CA. Dimensions, septation, and pattern of pneumatization of the sphenoidal sinus. *Folia Morphologica.* 2009;68(4):228-32.
17. Sevinc O, Is M, Barut C, Erdogan A. Anatomic variations of sphenoid sinus pneumatization in a sample of Turkish population: MRI study. *Int J Morphol.* 2014;32(4):1140-3.
18. Vidya CS, Raichurkar K. Anatomic variation of sphenoid sinus in Mysore based population: CT scan study. *Int J Anat Res.* 2015;3(4):1611-14.
19. Ramalho CO, Marengo HA, Guimarães Filho FA, da Costa MD, de Oliveira Santos BF, de Paula Santos R, et al. Intrasphenoid septations inserted into the internal carotid arteries: a frequent and risky relationship in transsphenoidal surgeries. *Braz J Otorhinolaryngol.* 2017;83:162-7.
20. Fernandez-Miranda JC, Prevedello DM, Madhok R, Morera V, Barges-Coll J, Reineman K, et al. Sphenoid septations and their relationship with internal carotid arteries: anatomical and radiological study. *Laryngoscope.* 2009;119:1893-6.
21. Renn W, Rhoton AL. Microsurgical anatomy of the sellar region. *J Neurosurg.* 1975;43:288-98.
22. Sethi DS, Stanley RE, Pillay PK. Endoscopic anatomy of the sphenoid sinus and sella turcica. *J Laryngol Otol.* 1995;109:951-5.
23. Abdullah BJ, Arasaratnam S, Kumar G, Gopala K. The sphenoid sinuses: computed tomographic assessment of septation, relationship to the internal carotid arteries, and sidewall thickness in the Malaysian population. *Hong Kong J Radiol.* 2001;4:185-8.
24. Unal B, Bademci G, Bilgili YK, Batay F, Avci E. Risky anatomic variations of sphenoid sinus for surgery. *Surg Radiol Anat.* 2006;28:195-201.

**Cite this article as:** Lokwani MS, Patidar J, Parihar V. Anatomical variations of sphenoid sinus on multi-detector computed tomography and its usefulness in trans-sphenoidal endoscopic skull base surgery. *Int J Res Med Sci* 2018;6:3063-71.