

Original Research Article

A study on surgical management of undescended testis

Mallikarjuna M.¹, Mahesh Dhotre^{2*}, Shanmukhappa S.³

¹Department of General Surgery, Mcgann Teaching Hospital, SIMS, Shivamogga, Karnataka, India

²Department of General Surgery, SIMSAR, KGF, Karnataka, India

³Department of General Surgery, District Hospital, Haveri, Karnataka, India

Received: 05 July 2018

Accepted: 31 July 2018

*Correspondence:

Dr. Mahesh Dhotre,

E-mail: dhotre4u@gmail.com

Copyright: © the author(s), publisher and licensee Medip Academy. This is an open-access article distributed under the terms of the Creative Commons Attribution Non-Commercial License, which permits unrestricted non-commercial use, distribution, and reproduction in any medium, provided the original work is properly cited.

ABSTRACT

Background: Cryptorchidism which is synonymous with Undescended testes. It is one of the most common congenital anomalies found in children. The aim is to study the surgical management of undescended testis in relation to age, position, side, symptoms, complications and management of undescended testis. This study will present an overview of the current understanding of this challenging problem, mainly concentrating on surgical management.

Methods: About 30 cases of undescended testis were included in the study, which were diagnosed with regards to age of presentation, clinical features, inclusion and exclusion criteria and relevant investigations like ultrasonography, diagnostic laparoscopy, CT wherever required. Cases were managed accordingly in the course of study and sampling of cases was taken from Bapuji Hospital and C.G. Hospital, Davangere during the study period.

Results: Undescended testis was found more common on right side and most of them presented with the age group of 1-15 years with absence of testis in the scrotum being the most common complaint and hernia was found to be most commonly associated with undescended testis. Most common position of undescended testis was found to be intracanalicular with most of them being palpable. The only one case had torsion and few of the cases had post operative complications like, wound infection haematoma. Open and laparoscopic orchidopexy can be used as most common procedure in early age group.

Conclusions: Undescended testes is eminently treatable in today's practice with the surgical procedures, an early diagnosis, informed counselling of parents and optimal surgical management offer optimised opportunities for successful placement and function of the testes which lessen the burden of complications.

Keywords: Cryptorchidism, Intracanalicular testes, Orchidopexy, Orchiectomy, Undescended testes

INTRODUCTION

Cryptorchidism is a term that has been used interchangeably with the term undescended testis. Both terms refer to an abnormally positioned testis, but cryptorchidism literally means "hidden testis."

It is one of the most common congenital anomalies found at birth and affects 1% to 4% of full term and 1% to 45% of preterm male neonates.¹

Approximately 70% to 77% of cryptorchid testis will spontaneously descend, usually by 3 months of age.² By 1 year of age, the incidence of cryptorchidism declines to about 0.8 to 1.2% and remains constant throughout the adulthood.³ During the course of testicular development and its descent from abdomen to scrotum; it may arrest to descend in any portion of normal pathway.

Histological changes are noted as early as the second year of life, furthermore, proximally situated testis are more

severely affected. This disorder is associated with certain other complications such as infertility, higher risk of testicular trauma, testicular malignancy, torsion testis and strangulation of associated inguinal hernia. Therefore, its early diagnosis and treatment is of paramount importance. A thorough clinical examination to locate a palpable testis and investigations like ultrasound, CT scan, MRI and diagnostic laparoscopy to locate non-palpable testis are done. Surgery is now the preferred modality. Orchidopexy is done for palpable and laproscopic surgeries are done for non-palpable testis (Figure 1 to 8).^{1,4}

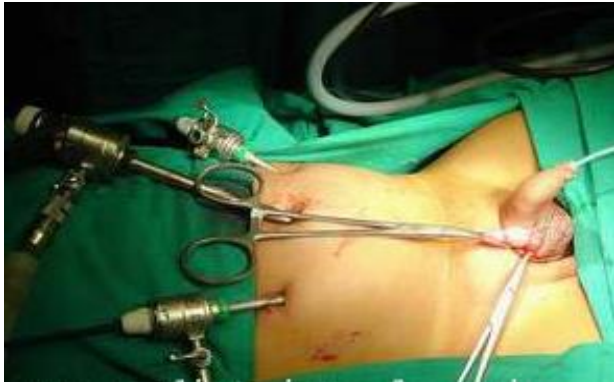

Figure 1: Access to the intra-abdominal testis by laparoscopy.

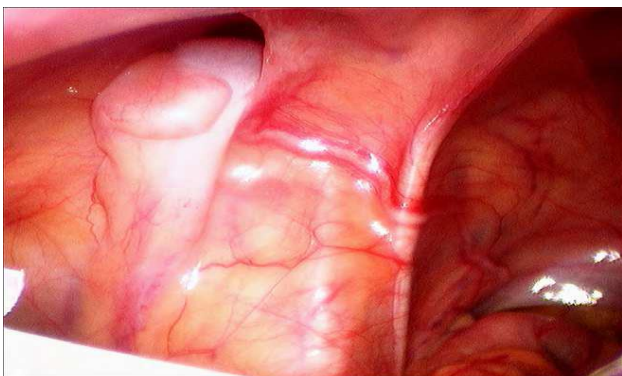


Figure 2: Laparoscopic view of intra-abdominal testis.

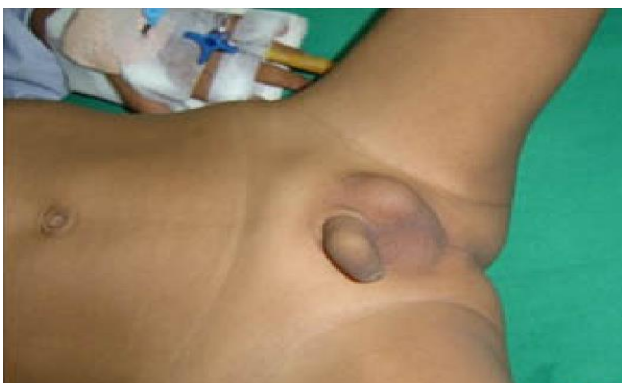

Figure 3: Pre-operative picture of Rt UDT.

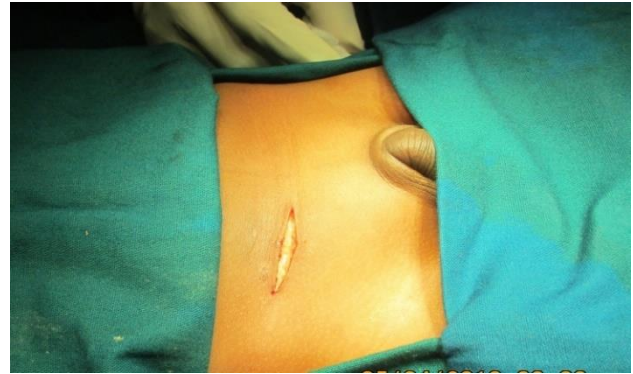

Figure 4: Skin incision for Std orchidopexy.

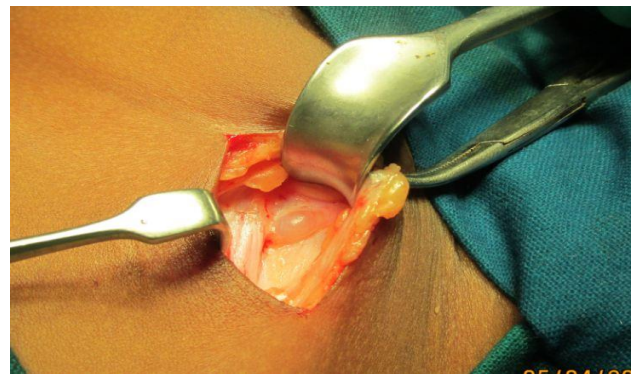


Figure 5: Right intra-canalicular testis.

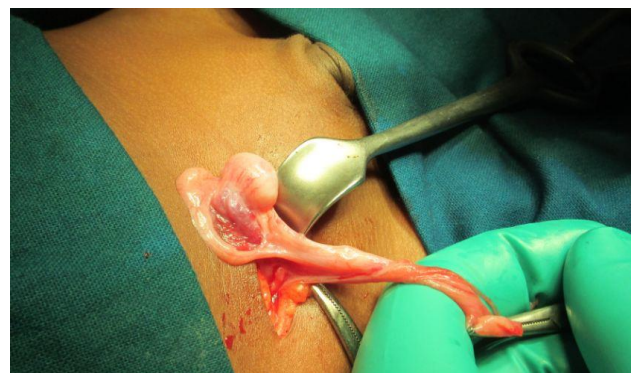


Figure 6: Released Rt gubernaculum.

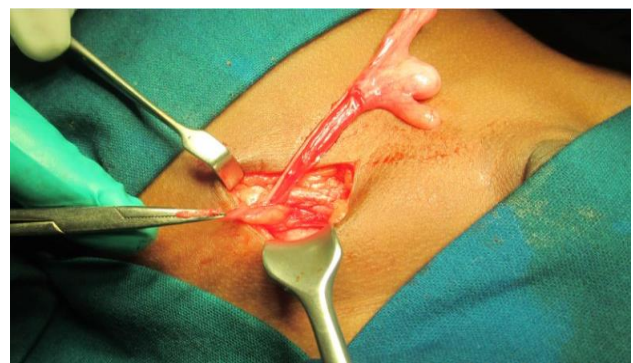


Figure 7: Mobilisation of Rt intra-canalicular testis.

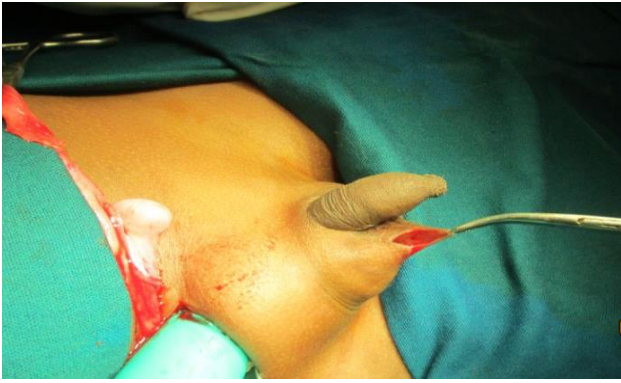

Figure 8: Creation of dartos pouch.

Hence this study was planned to study the incidence of undescended testis in our population and to study the various modes of clinical presentation. Also, to study the complications of undescended testis and to study the surgical methods of treatment of undescended testis. Lastly to study the complications of surgical management.

METHODS

Source of data

A prospective study was carried out on patients admitted to Chigateri General Hospital and Bapuji Hospital of J.J.M. Medical Collage, Davangere during the course of study.

Method of collection of data

From the above mentioned source, 30 consecutive cases were taken who fulfilled inclusion and exclusion criteria.

Inclusion criteria

- Patients with undescended testis above one year of age.
- No upper age limit.
- Patients willing to undergo surgery for the condition.

Exclusion criteria

- Children with undescended testis less than one year of age.
- Patients with retractile testis and ectopic testis.
- Patient not fit for surgery.

The patients were selected as per inclusion and exclusion criteria. An informed consent was taken. Careful history was taken from selected patients who then underwent general and systemic examination. Patients were evaluated in the self-designed examination proforma. The relevant investigations were done to achieve the correct diagnosis. The patients were studied regarding the type

and site of undescended testis. The patients were operated by appropriate surgical technique depending on their position and condition of the testis. The follow up was done with regard to the complications.

RESULTS

The present study included 30 cases admitted in both the teaching hospitals namely Chigateri General Hospital and Bapuji Hospital attached to J.J.M Medical College, Davangere. The study was done for a period of two years from September 2011 to May 2013.

Table 1: Age wise distribution.

Age group (yrs)	No. of cases	%
1-3	17	56.6
4-6	7	23.4
7-9	2	6.6
10-13	3	10
>14	1	3.4
Total	30	100

Mean age 4.36 years. Range 1-15 yrs

In the present study, maximum number of cases were in 1-3years age group (56.6%) followed by 4-6 age group (23.4%). Average mean age was 4.36 years. Range was from 1 to 15 years (Table 1).

Table 2: Clinical presentation.

Symptoms	No. of cases	%
Absence of testis in scrotum	25	83.4
Swelling in the groin	7	23.4
Pain	7	23.4
Symptoms of complications	5	16.6

In the present study, most common symptom was absence of testis 25(83.4%). Next common symptom was swelling in the groin and pain 7 (23.4%) cases each, followed by symptoms of complications 5 (16.6%) (Table 2).

Table 3: Side of undescended testis.

Side	No. of cases	%
Right	18	60
Left	10	3.4
Bilateral	2	6.6

In the present study, most common side of undescend was right side 18 (60%) cases. Next common side was left side 10 (3.4%) cases, followed by bilateral undescend 2 (6.6%) (Table 3).

In this study, most common position of undescended testis was intra-canalicular, 15 (50%) cases. Next common position was emergent, 10 (33.4%) cases, and

least common position was intra-abdominal, 5 (16.6%) (Table 4).

Table 4: Position of undescended testis.

Position	No. of cases	%
Emergent	10	33.4
Intra-canalicular	15	50
Intra-abdominal	5	16.6
Total	30	100

Table 5: Relation between the position and palpability of testis.

Position	No. of cases	Palpable testis		Impalpable testis	
		No	%	No	%
Emergent	10	10	100	0	0
Intra-canalicular	15	14	93.4	1	6.6
Intra-abdominal	5	0	0	5	100

In the present study, all the emergent testis were palpable (100%). In intra-canalicular testis all were palpable except for 1(6.6%) case which was impalpable. And all the intra-abdominal testis were impalpable (100%) (Table 5).

In this study, hernia was the most common complication 4(13.4%), followed by torsion of the testis 1 (3.3%) cases. None of the cases had complications like trauma and malignancy (Table 6).

Table 6: Complications.

Complications	No. of cases	%
Hernia	4	13.4
Torsion	1	3.3
Trauma	0	0
Malignancy	0	0

Table 7: Investigations.

Investigations	No. of cases
Ultrasound abdomen	14
Laproscopy	5

Table 8: Operative procedures.

Surgery	No. of cases	Percentage (%)
Orchidopexy	28	93.4
Orchidectomy	2	6.6
Total	30	100

In this study, ultrasound was done in 14 cases (9 cases were intra-canalicular and 5 cases were intra-abdominal). USG was found positive in all 9 cases of intra-canalicular testis but positive in only 2 cases of intra-abdominal testis (out of 5 cases). Laparoscopy was done in 5 intra-abdominal cases and was positive in all cases (Table 7).

In our study 28 (93.4%) cases underwent orchidopexy, and 2 cases (6.6%) underwent orchidectomy (Table 8).

Table 9: Type of operative procedures.

Type	Standard Single Stage OP		Fowler –Stephens Single Stage OP	Two Stage OP	OD
	High Inguinal T	Mid & Low Inguinal T			
Open	4	20	0	0	1
Laparoscopic	0	0	4	0	1

Table 10: Post-operative complications.

Complications	No. of cases	%
Hematoma (HMT)	1	3.3
Wound infection (WI)	1	3.3

Table 11: Duration of hospital stay.

Duration of stay (days)	No. of cases	%
<2	0	0
2-4	17	56.6
4-6	12	40
>6	1	3.4
Total	30	100

Mean duration 3.7 days, Range 3-7 days

In our study maximum number of cases underwent single stage standard orchidopexy, among them 20 cases had mid and low inguinal testis and 4 in the high inguinal region. 4 cases underwent laparoscopic Fowler-Stephens single stage orchidopexy. About 2 cases ended up with orchidectomy, among them 1 case was done laparoscopically (Table 9). In our study, wound infection and hematoma were the complications after surgery, which were seen in 1 (3.3) case each (Table 10).

In our study, duration of hospital stay ranged from 3-7 days. Mean duration of stay was 3.7 days. Maximum number of cases 17 (56.6%) stayed for 2-4 days. 12 patients (40%) stayed for 4-6 days and 1 (3.4%) patient for 7 days (Table 11).

DISCUSSION

In the present study, the maximum number of cases were in 1-3years age group (56.6%). The youngest patient we recorded was 1year 1 month old and oldest was 15year. The age at presentation was ranged from 1year 1month to 15year in our study. The mean age was 4.36 years. According to Iacobi RE et al, the mean age of undescended testis was 3-7years.⁷

In this study, maximum numbers of patients presented with complain of absence of testis in the scrotum 25 (83.4%). Next common presenting complain was swelling in the groin and pain accounting for 7 (23.4%) cases each. Least common presentation was symptom associated with complication. According to Steven G et al 2000, the most common clinical presentation was absence of testis in the scrotum.¹ In this study, the most common side of undescend was right side (60%). And 33.4% cases had left side undescend of testis. Bilateral undescend was seen in 6.6% cases. Ashley RA, Mouriquand PD 2008, reported that right side was most common side of undescend (70%).^{8,5} Majority of the cases in our study had intra-canalicular position of testis (15 cases 50%). Among these 14 cases had palpable testis and 1 case had impalpable testis which was subsequently diagnosed by USG. The next common position of testis was emergent 10(33.4%) cases and all were palpable. Intra-abdominal testis was found in 5 (16.6%) cases. Hadziselimovic 1983 also reported the most common position was intra-canalicular (63%) and 8% were intra-abdominal.^{1,9}

In this study, majority of the cases had hernia 4(13.4%) as symptom of complication. Torsion was seen in 1 (3.3%) case. None of the cases had trauma or malignancy as symptom of complication. Lao OB et al, reported that hernia is most commonly associated with undescended testis.¹⁰ In this study, all impalpable testis were investigated using ultrasonography and laparoscopy. 14 cases were investigated with ultrasonography, out of which 8 were palpable intra-canalicular, 1 case impalpable intra-canalicular and 5 intra-abdominal. Among 5 cases of intra-abdominal testis ultrasonography was failed to locate the testis in 4 cases. Laparoscopy was performed in 5 cases of intra-abdominal testis, all of them were located accurately.

Ekenze SO et al, says ultrasound does not reliably localize non-palpable testis and does not rule out an intra-abdominal testis.¹¹ Moore RG et al, stated that diagnostic laparoscopy has been commonly used for the assessment of non-palpable testis, with the accuracy of testicular localization reported to be >95%.⁶ Compared to above mentioned reports laparoscopy was found to be more accurate than the ultrasonography for non palpable testis even in our study. In this study, 28 cases underwent orchidopexy and 2 cases underwent orchidectomy. Among the 25 cases of intra-canalicular (15) and emergent (10) testis, 24 cases underwent standard single

stage orchidopexy and 1 case ended up with orchidectomy because of torsion of the testis. In our study standard single stage orchidopexy was found to be having a success rate of 96%. According to Taran I, Elder JS, the success rate of orchidopexy was reported to be >95% in inguinal testis.¹²

In 5 cases of intra-abdominal testis, 4 cases underwent laproscopic single stage Fowler-Stephens orchidopexy and 1 case ended with orchidectomy. In our study, the success rate of laparoscopic technique was 80%. Esposito et al, has shown high success rate of laproscopic Fowler-Stephens technique for intra-abdominal testis (97%).¹ Lindrgen et al, has also shown high success rate (>95%).¹³ In this study, 1 case developed wound infection and 1 case developed scrotal hematoma. In the present study, 22 cases were underwent surgery on 2nd day of admission. 8 cases were underwent surgery on 3rd day of admission. 17 cases were stayed <4 days in the hospital, 12 cases were stayed for <6 days and 1 case stayed for 7 days as the patient developed wound infection.

Sincere efforts were made to follow up all the cases at 2weeks, 6 weeks, 3months 6 months and 1 year during the period of study. None of cases reported complications during the period of study.

CONCLUSION

During the course of the study, it was evident that different age groups of patients presented with undescended testis. The type of surgery depends on the position of the testis. Standard open orchidopexy is preferable for high, mid and low inguinal testes. Laparoscopic single staged Fowler-Stephens orchidopexy was preferable for the intra abdominal testis from our study.

Funding: No funding sources

Conflict of interest: None declared

Ethical approval: The study was approved by the Institutional Ethics Committee

REFERENCES

1. W. McDougal, Wein A, Kavoussi L, Novick A, Partin A, Peters C, Ramchandani P, et al. Abnormalities of the testis and scrotum and their surgical management, Campbell-Walsh urology, Barthold JS (ed), 10th ed. Saunders Elsevier Publication, Philadelphia;2012:3560-3574.
2. Berkowitz GS, Lapinski RH, Gazella JG, Dolgin SE, Bodian CA, Holzman IR. Prevalence and natural history of cryptorchidism. Pediatrics. 1993 Jul 1;92(1):44-9.
3. Abacı A, Çatlı G, Anık A, Böber E. Epidemiology, classification and management of undescended testes: does medication have value in its treatment?. J Clin Res Pedia Endocrinol. 2013 Jun;5(2):65.

4. Steven GD. Cryptorchidism. The Kelalis-King-Belman Text book of clinical Paediatric Urology, 5thed. Informa UK Ltd;2007:1295-1308.
5. Mouriquand PD. Undescended testes in children the paediatric urologist's point of view. *Eur J Endocrinol.* 2008;159(Suppl 1):83-6.
6. Moore RG, Peters CA, Bauer SB, Mandell J, Retik AB. Laparoscopic evaluation of the nonpalpable testis: a prospective assessment of accuracy. *J Urology.* 1994 Mar 1;151(3):728-31.
7. Iacobi RE, Moldovani Z, Soiu M, Osakwe HI, Trailescu M. Epidemiological study on undescended testis. *J Pedia.* 2009;12:45-6.
8. Ashley RA, Barthold JS, Kolon TF. Cryptorchidism: pathogenesis, diagnosis, treatment and prognosis. *Urol Clin North Am.* 2010;37:183-93.
9. Hadziselimovic F, Höcht B: Prospectives. In: Hadziselimovic F (ed.), *Cryptorchidism: Management and Implications.* Berlin, Springer-Verlag;1983:135.
10. Lao OB, Fitzgibbons RJ, Cusick RA. Pediatric inguinal hernias, hydroceles, and undescended testicles. *Surgical Clinics.* 2012;92(3):487-504.
11. Ekenze SO, Nwankwo EP, Okere PC. The utility of ultrasonography in the management of undescended testis in a developing country. *World J Surg.* 2013;37(5):1121-4.
12. Taran I, Elder JS. Results of orchiopexy for the undescended testis. *World J Urol.* 2006;24:231-9.
13. Lindgren BW, Franco I, Blick S, Levitt SB, Brock WA, Palmer LS, et al. Laparoscopic Fowler-Stephens orchiopexy for the high abdominal testis. *J Urol.* 1999;162:990-3.

Cite this article as: Mallikarjuna M, Dhotre M, Shanmukhappa S. A study on surgical management of undescended testis. *Int J Res Med Sci* 2018;6:3105-10.