

Original Research Article

Study of inter pedicular distance of lumbar spinal canal in perspective of lumbar canal stenosis using plain antero-posterior radiographs in western population of Rajasthan, India

Meghna Bhaumik¹, Uday Bhaumik^{2*}

¹Department of Anatomy, ²Department of Neurosurgery, Geetanjali Medical College Hospital, Udaipur, Rajasthan, India

Received: 17 July 2018

Revised: 29 March 2019

Accepted: 03 April 2019

***Correspondence:**

Dr. Uday Bhaumik,

E-mail: udaybhaumik@gmail.com

Copyright: © the author(s), publisher and licensee Medip Academy. This is an open-access article distributed under the terms of the Creative Commons Attribution Non-Commercial License, which permits unrestricted non-commercial use, distribution, and reproduction in any medium, provided the original work is properly cited.

ABSTRACT

Background: Various causes have been attributed to low backache, but lumbar canal stenosis is turned out to be a major causative factor. It has been suggested that reduced IPD is one among the major cause of narrowing of the spinal canal. The objective of this study was to evaluate the inter pedicular distances in lumbar vertebral column in both sexes of western Rajasthan, India.

Methods: The present descriptive type study was conducted in Department of Anatomy and Neurosurgery Sawai Man Singh Medical College, Jaipur, Rajasthan, India. Antero-posterior plain radiographs of lumbar spine in 1000 subjects aged between 20 to 60 years and those who were born and brought up in Rajasthan state were used for the study. All measurements were made by using electronic digital Vernier caliper. Student t-test was used for analysis.

Results: Mean transverse diameter of lumbar vertebral canal (I.P.D) is minimum at L1 vertebra in both sexes. The maximum values of I.P.D were recorded for vertebra L5 for both sexes.

Conclusions: The values of IPD are higher in male population in comparison to female counterparts.

Keywords: Inter pedicular distance, Lumbar canal stenosis, Lumbar vertebrae

INTRODUCTION

The first introduction to the vertebral morphometry of clinical significance was done by Elesberg.¹ They measured interpedicular distance of adult human vertebrae by antero-posterior view on the radiographs to localize and diagnosis of tumor of spinal cord. Lumbar part of vertebral canal houses the cauda equina and narrowing of the bony ring of the canal which may be developmental or acquired may lead to compression of these nerve roots and causes low back pain.² Huizinga et al, performed these measurements on lumbar vertebrae obtained from Dutch cadavers.³ It was found that in developmental stenosis the interpedicular distance were normal where the mid- sagittal diameters were

reduced a fact confirmed in later years by Larsen.⁴ Lumbar canal stenosis is one among the major causative factors producing low back pain.

Stenosis is due to reduced sagittal diameter as well as reduced interpedicular distance has been coming into notice of clinicians for past many years. The size of the lumbar spinal canal is easily measured by antero-posterior plain radiographs of lumbar spine. Various studies have emphasized, that the ideal X-ray projections for measuring interpedicular distance is the antero-posterior view and this parameter is important in assessing the size of canal.⁵⁻⁷ It has been suggested that

reduced I.P.D is one among the major cause of narrowing of the spinal canal.

Reports of normal value of lumbar interpedicular distance of white Americans, black and white South Africans, Nigerians, Spanish subjects and in adult Saudis, have shown that the transverse diameter of lumbar spinal canal exhibits ethnic variations. These authors have studied this parameter in plain antero-posterior radiographs of lumbar spine.⁸⁻¹¹

The importance of the size and shape of the spinal canal in relation to the occurrence of symptoms of cord or root compression especially, when spondylotic changes supervene has been recognized for some time. Most of the earlier work concerned with the cervical region, but in more recent years a similar condition has been fully recognized in the lumbar region also.¹² Hence the present study was conducted in the western region of Rajasthan, India to get a glimpse over the range of I.P.D of lumbar spinal canal in adult Rajasthan population.

METHODS

The present descriptive type study was conducted in Department of Anatomy and Neurosurgery Sawai Man Singh Medical College, Jaipur, Rajasthan, India. Antero-posterior radiographs of lumbar spine in 1000 subjects between the age group of 20 to 60 years, with the history of low back pain, reporting to outpatient Department of Neurosurgery, Orthopedics and also the patients admitted in various wards for complains of disc protrusion, spondylolisthesis (not associated with gross vertebral body collapse) of Sawai Man Singh Medical College, Jaipur, Rajasthan, India, formed the material for the study.

The present descriptive type study was conducted in Department of Anatomy and Neurosurgery S.M.S. Medical College, Jaipur, (Rajasthan). Antero-posterior radiographs of lumbar spine in 1000 subjects between the age group of 20 to 60 years, with the history of low back pain, reporting to outpatient department of Neurosurgery, Orthopedics and also the patients admitted in various wards for complains of disc protrusion, spondylolisthesis (not associated with gross vertebral body collapse) of S.M.S Medical College and Hospitals, Jaipur formed the material for the study. The patients who were native of Rajasthan state (born and brought up) were included in the study.

Whereas, patients below the age of 20 years and above the age of 60 years were excluded from the study as well as the patients suffering from congenital spinal deformities like achondroplasia, split cord malformations or with spinal trauma or injuries were excluded from the study. The study design was mainly of descriptive type. Patients were X rayed in recumbent position with an anode film distance of 100 cm centered on L3 vertebra and directed at 90° to the film. All measurements were

made by using electronic digital Vernier Calipers and were recorded to the nearest hundredth of millimeters keeping in view the aims of the study (Figure 1).



Figure 1: Measurement of interpedicular distance from digital Vernier caliper.

Transverse diameter of lumbar spinal canal /Interpedicular distance

The minimum distance between the medial surfaces of the pedicles of the given vertebra (Figure 2).⁶

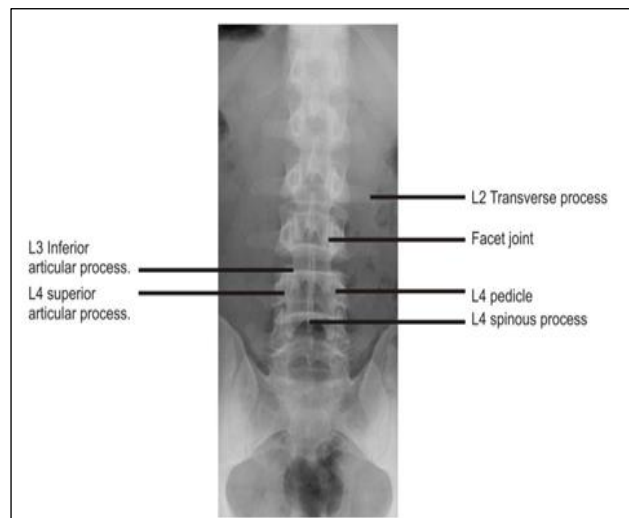


Figure 2: Anterior-posterior radiograph showing interpedicular distance.

RESULTS

Interpedicular distances of lumbar vertebral canal at levels L1 to L5 were measured in plain antero-posterior radiographs of lumbar spine of 1000 subjects (708 males and 292 females) from Sawai Man Singh Medical college hospital, Jaipur, Rajasthan, India of age between 20 to 60 years. Mean transverse diameter (I.P.D) is minimum at L1 vertebra in both sexes (22.50 mm in males and 21.40

mm in females). The maximum values of I.P.D were recorded for vertebra L5 for both sexes (30.76 mm in males and 29.81mm in females), showing a gradual

increase in I.P.D from L1 to L5 vertebrae. The values of I.P.D were greater in males than females at each vertebral level (Table 1).

Table 1: The comparison of interpedicular distances in males and females for lumbar vertebral canal L1 to L5t.

Vertebra	Male		Female		P-values	Significance
	Mean	SD	Mean	SD		
L1	22.50	±6.3	21.40	±2.92	<0.001	Highly significant
L2	23.20	±3.62	22.60	±2.81	<0.01	Significant
L3	24.48	±4.50	23.62	±4.02	<0.01	Significant
L4	26.50	±4.72	25.15	±3.72	<0.01	Significant
L5	30.76	±4.62	29.81	±4.12	<0.01	Significant

DISCUSSION

Eisenstein S et al, studied the interpedicular distances of lumbar spinal column of 485 adult black and white South African populations.¹³ He noted the minimum diameter of 23 mm at L1 and maximum diameter of 26 mm at L5 in males whereas in females the values of I.P.D were less in comparison to males at L1 it was 22 mm and maximum at vertebra L5 25 mm.

Nirwan AB et al, studied the interpedicular distances in plain antero-posterior radiographs of 202 subjects in Gujrati population.⁹ They recorded the same crania caudal increase of intern pedicular distances in lumbar vertebrae from L1 to L5. The values of I.P.D. were significantly higher for males 30.9 mm at L5 and 24 mm at L1, where's in females the maximum diameter was recorded 29.8 mm at L5 and 23.3 mm at vertebra L1. In continuation of this series Chhabra S et al, studied the interpedicular distances of North Indian population in Rohtak (Haryana) and they also noted the same cephalo-caudal increase of interpedicular distances in lumbar vertebral column.¹⁴ The highest values of I.P.D. were noted on L5 (37.4 mm and 34.4 mm) respectively in males and females and the lowest values were recorded (26.0 mm and 24.1 mm) at L1 vertebra for males and females respectively.

Janjua MZ et al, Studied the normal dimensions of lumbar spinal canal of either group between the age group of 25 to 45 years with both antero-posterior and lateral photographs.¹² The canal showed gradual decrease from L1 to L5 level with a wider value for females in comparison to males. Ahmed T et al, also studied the various parameters of lumbar vertebral column in symptomatic and non-symptomatic subjects with M.R.I.¹⁵ In this present study which was done in western part of Rajasthan, India, authors have recorded the maximum values of interpedicular distances in males and at the level of vertebra L5 (30.76 mm) and minimum distances were noted on vertebra L1 (22.50 mm) whereas in females the values of interpedicular distances were

smaller in comparison to their male counterparts. The maximum values of interpedicular distances were recorded on vertebra L5 (29.8 mm) and minimum diameter was noted on vertebra L1 (21.40 mm) and these values of I.P.D. are similarly following the cranio-caudal increase of lumbar vertebral column as well as the diameters of I.P.D. are greater for males in comparison to females.

The study is also in accordance with the fact, that there are ethnic as well as racial variations in the size of lumbar vertebral canal. Thus, emphasizing the need to have normal values and range for the transverse diameter of the canal (I.P.D.) for different population as well as supporting the statement "There are no mean values of the vertebra that are valid for all population".

ACKNOWLEDGEMENTS-

Authors would like to acknowledge to the patients of S.M.S. Medical College, Jaipur, Rajasthan, who became the pillars for this study.

CONCLUSION

There is a cranio-caudal increase of transverse diameter of spinal canal /I.P. D from L1-L5 vertebrae. Dimensions of male populations are significantly higher with respect to the female population. The large sample size of the study provides a fair idea to the clinician about the ranges of I.P.D in western Rajasthan population regarding early stenotic features of lumbar spinal canal.

Funding: No funding sources

Conflict of interest: None declared

Ethical approval: The study was approved by the Institutional Ethics Committee

REFERENCES

1. Elesberg CA, Dyke CG. The diagnosis and localization of tumors of the spinal cord by means

- of measurements made on the x-ray's films of the vertebrae. *Bull Neurol Inst New York.* 2019;3:359-94.
2. Verbiest H. A radicular syndrome from developmental narrowing of the lumbar vertebral canal. *J Bone Joint surg.* 1954;36(2):230-7.
 3. Huizinga J, Heiden JA, Vinken PJ. The human lumbar vertebral canal: a biometric study. *Proc R Acad Sci (Amsterdam)* 1952;C55:22.
 4. Larsen JL, Smith D. Vertebral body size in lumbar spinal canal stenosis. *Acta Radiologica. Diagnosis.* 1980;21(6):785-8.
 5. Landmesser JW, Heublein GW. Measurement of the normal interpedicular space in the child. *Connect State Med J.* 1953;17(4):310-3.
 6. Jones RA, Thomson JL. The narrow lumbar canal: a clinical and radiological review. *J Bone Joint Surg.* 1968 Aug;50(3):595-605.
 7. Hinck VC, Clark JR WM, Hopkins CE. Normal interpediculate distances (minimum and maximum) in children and adults. *Am J Roentgenol.* 1966;97(1):141-53.
 8. Amonoo-Kuofi HS. Maximum and minimum lumbar interpedicular distances in normal adult Nigerians. *J Anatomy.* 1982;135(2):225.
 9. Nirvan AB, Pensi CA, Patel JP, Shah GV, Dave RV. A study of inter-pedicular distances of the lumbar vertebrae measured in plain antero-posterior radiograph in Gujaratis. *J. Anat. Soc. India.* 2005;54(2):58-61.
 10. Olsewski JM, Simmons EH, Kallen FC, Mendel FC, Severin CM, Berens DL. Morphometry of the lumbar spine: anatomical perspectives related to transpedicular fixation. *J Bone Joint Surg. Am.* 1990;72(4):541-9.
 11. Eisentein S. Lumbar vertebral Canal morphometry for computerized tomography in spinal stenosis. *Spine.* 1983; 8(2):187-91.
 12. Janjua MZ, Muhammad F. Measurements of the normal adult lumbar spinal canal. *JPM. J Pak Med Assoc.* 1989;39(10):264-8.
 13. Eisenstein S. The morphometry and pathological anatomy of lumbar spine in South African Negroes and Caucasoid with specific reference to spinal stenosis. *J Bone Joint Surg.* 1977;59(2):173-80.
 14. Chhabra S, Gopinathan K, Chhibber SR. Transverse diameter of the lumbar vertebral canal in North Indians. *J Anat Soc. India.* 1991;41(1):25-32.
 15. Ahmad T, Goel P, Babu CR. A study of lumbar canal by MRI in clinically symptomatic and asymptomatic subjects. *J Anatom Soc India.* 2011;60(2):184-7.

Cite this article as: Bhaumik M, Bhaumik U. Study of inter pedicular distance of lumbar spinal canal in perspective of lumbar canal stenosis using plain antero-posterior radiographs in western population of Rajasthan, India. *Int J Res Med Sci* 2019;7:1455-8.