

Review Article

Spectrum and review of MRI findings in hypophysitis

Niharika Kadiyala, Arunan Murali*, Venkata Sai

Department of Radiology, Sri Ramchandra Medical College, Porur, Tamil Nadu, India

Received: 07 August 2018

Revised: 11 October 2018

Accepted: 13 October 2018

*Correspondence:

Dr. Arunan Murali,

E-mail: dr.arunan@gmail.com

Copyright: © the author(s), publisher and licensee Medip Academy. This is an open-access article distributed under the terms of the Creative Commons Attribution Non-Commercial License, which permits unrestricted non-commercial use, distribution, and reproduction in any medium, provided the original work is properly cited.

ABSTRACT

Inflammation of the pituitary infundibulum and pituitary gland (hypophysis) is called hypophysitis. The causes may be primary (lymphocytic hypophysitis, granulomatous hypophysitis, xanthomatous hypophysitis, necrotizing hypophysitis) or secondary due to spread of disease from elsewhere in the body. Authors report three cases of primary hypophysitis with radiological findings ranging from simple thickening of the infundibulum, posterior pituitary (infundibuloneurohypophysitis), thickening of the entire gland and infundibulum (panhypophysitis) and mass forming lesion in the anterior pituitary gland (adenohypophysitis). Diagnosis is arrived based on combined findings of clinical features, endocrinological assessment, Immunological markers, imaging studies and histopathology (if necessary). Conservative, supportive treatment is usually the treatment of choice with surgical decompression reserved for cases with extensive mass effect. Authors conclude that hypophysitis should be considered as a differential diagnosis for lesions of the pituitary.

Keywords: Adenohypophysitis, Granulomatous hypophysitis hypophysitis, Infundibuloneurohypophysitis, Lymphocytic hypophysitis, Panhypophysitis, Pituitary adenoma, Xanthomatous hypophysitis

INTRODUCTION

Inflammation of the pituitary gland is known as hypophysitis. Hypophysitis may be due to primary or secondary causes. Primary causes include lymphocytic (autoimmune), granulomatous and xanthomatous etiology.¹⁻³ Secondary caused maybe due local lesions or systemic diseases. Local lesions like germinomas, Rathke's cleft cysts, craniopharyngiomas and pituitary adenomas induce hypophysitis. Systemic diseases such as sarcoidosis, Wegner's granulomatosis, langerhans cell histiocytosis, syphilis, tuberculosis may infiltrate the pituitary gland and cause secondary hypophysitis

Autoimmune hypophysitis is the most common inflammation that affects the hypophysis. Secondary hypophysitis is relatively rare. There is considerable overlap in the clinical and radiological findings with sella

tumours. Patients present with headache, visual impairment or hypophyseal dysfunction.¹

Three radiological/morphological patterns are now recognized: adenohypophysitis (AH), infundibuloneurohypophysitis (INH) and panhypophysitis (PH). Authors describe three patients to illustrate the spectrum of the MRI findings in hypophysitis.

REVIEW OF LITERATURE

The exact is etiology of primary hypophysitis is still unknown. However, three clinicopathological forms have been described.

Lymphocytic hypophysitis is the most common among the primary hypophysitis. Females are more affected than

males. Mean age of presentation in females was 34.5 year and in the males was 44.7 year. Temporal association of lymphocytic hypophysitis with pregnancy is striking.^{4,5} Histologically, there is diffuse infiltration of the pituitary by inflammatory cells, predominantly lymphocytes that form lymphoid follicles.⁶

Granulomatous hypophysitis was first described by Simmonds M.⁷ There is equal incidence in males and female, in contrast to lymphocytic hypophysitis. Histologically, the pituitary shows diffuse collection of multinucleated giant cells, histiocytes with surrounding lymphocytes and plasma cells.

Pathogenesis of both lymphocytic and granulomatous hypophysitis are attributed to autoimmune mechanism, but the theory is yet to be substantiated. Xanthomatous hypophysitis is a rare form of hypophysitis with very few cases described in literature.⁸

Histologically, there is presence of lipid rich foamy histiocytes with variable numbers of lymphocytes resembling xanthomatous inflammatory processes elsewhere.

All the three primary hypophysitides share the same clinical and radiological features and there is no reliable and established way to distinguish them apart.

Clinical presentation of the hypophysitides are variable and can fall into four categories based the symptoms: Sella compression, hypopituitarism, diabetes insipidus and hyperprolactinemia.

Sella compression presents with headache and visual disturbances and are the most common and initial complaints. Headache is due to the mass effect on the diaphragmatic Sella and visual disturbances secondary to compression upon the optic chiasma. Autoimmune attack on the pituitary acinar cells produces the signs and symptoms of hypoadrenalism, hypothyroidism and hypogonadism. Destruction or compression on the posterior lobe and infundibular stem produces diabetes insipidus. Stalk compression leading to decrease in dopamine delivery to the anterior pituitary accounts for the hyperprolactinemia. Hyperprolactinemia manifests as amenorrhea/oligomenorrhea and galactorrhea.

Diagnosis dilemma of hypophysitis exists in distinction between the more common pituitary tumors, especially non-secreting adenomas. Clinical features, endocrinological assessment, immunological markers and imaging studies are taken into consideration to arrive at a diagnosis of hypophysitis.

Similarity exists in the clinical features of hypophysitis and other mass forming lesion of the pituitary. Clinical criteria have a low predictive value and cannot characterize the presentation of hypophysitis.

Complete or partial deficit of the anterior pituitary hormones, mainly ACTH, gonadotropins and prolactin are seen on endocrinological assessment.

Immunological markers (antibodies) against pituitary antigens may be measured by indirect immunofluorescence or immunoblotting.^{9,10} The specificity of pituitary antibodies is however poor, and may be seen in various nonautoimmune pituitary diseases such as Cushing's disease, pituitary adenomas, empty Sella syndrome, and Sheehan syndrome.¹¹⁻¹⁴ They can also be seen in other autoimmune diseases such as type I diabetes, Hashimoto's thyroiditis and Graves' disease.¹⁵⁻¹⁷

MRI is the modality of choice in the evaluation of the pituitary gland. Advantages include no exposure to ionizing radiation, excellent spatial resolution, superior soft tissue contrast, and a panoramic view of the Sella region. Recent advances allow high resolution images, and dynamic technique in which images are acquired simultaneously while administering contrast.

On pre-contrast T1-weighted images, the normal adenohypophysis shows a homogenous signal, isointense to the gray matter, whereas the normal neurohypophysis appears hyperintense. The hyperintensity of the neurohypophysis is believed to reflect the high phospholipid content of the ADH and oxytocin neurosecretory granules.¹⁸ After gadolinium, there is a physiological, homogeneous enhancement of the entire gland that makes the anterior and posterior lobes indistinguishable.

Table 1: MRI findings in adenohypophysitis and pituitary macroadenomas.

	LAH	Macroadenoma
Asymmetric mass	-	+
Precontrast homogenous signal	+	-
Intact sellar floor	+	-
Suprasellar extension	+	+
Stalk thickening	+	-
Stalk enhancement	-	+
Homogenous enhancement	+	-
Loss of posterior hyperintensity	+	-

Three characteristic findings have been identified in MRI of pituitary hypophysitis depending on the site of involvement (anterior pituitary, posterior pituitary and stalk). In adenohypophysitis (AH) pattern, there is symmetric enlargement of the pituitary gland, thickened undisplaced stalk with homogenous enhancement of the gland. The posterior pituitary bright spot is obscured and there is erosion or depression of the floor of sella.¹⁹⁻²¹ In contrast, macroadenomas displace the infundibular stalk,

depress or erode the floor of sella and display inhomogeneous enhancement. Some authors have described in adenohypophysitis, linear enhancing tissue at the adjacent duramater ("dural tail " or "meningeal tail").

In infundibuloneurohypophysitis pattern, there is thickening of the pituitary stalk more than 3mm at the level of the median eminence of the hypothalamus, loss of T1 hyperintensity of the posterior pituitary and swelling of the posterior pituitary.²²

In panhypophysitis, there is a combination of the adenohypophysitis and infundibuloneurohypophysitis.

The pattern of enhancement of the pituitary gland after gadolinium may help in differentiating hypophysitis from macroadenoma. Adenohypophysitis shows strong and homogenous enhancement of the pituitary, similar to the cavernous sinus.^{23,24}

Spontaneous recovery of the pituitary function and decrease or resolution of the pituitary mass has been described in cases of hypophysitis.²⁵⁻²⁸ Some patients may require active treatment. Bromocriptine is used to lower the hyperprolactinemia and improve visual field defects. Glucocorticoid therapy is advocated to reduce inflammation and give temporary relief. Surgery is the common form of treatment to reduce the pituitary mass and the associated compressive mass effects on the surrounding structures.

DISCUSSION

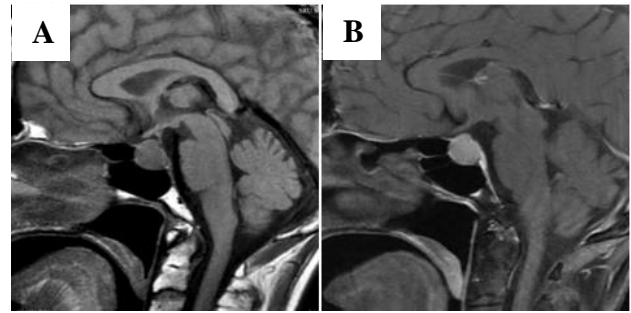
Clinical scenario

Scenario 1

A 57 years old women who is a follow up case of autoimmune hypophysitis on steroids came with complaints of multiple episodes of nausea and vomiting. Patients systemic examination and fundus examination were unremarkable.

Relevant laboratory investigations including HB - 9.8%, complete blood count, renal function test and liver function test parameters were within normal limits. A repeat thyroid profile was done and found to be elevated. Her prolactin still remains elevated -77mg (normal: 27mg/L), serum cortisol was 0.66 (normal:7-28µg/dL), anti TPO was elevated.

Follow up contrast enhanced MRI of the sella was performed, which showed reduction in size of the anterior pituitary mass lesion with suprasellar extension and also absence of posterior pituitary bright spot. Infundibular diameter was significantly reduced to 2mm. Patient was advised to continue steroids and asked for a follow up after 6months.

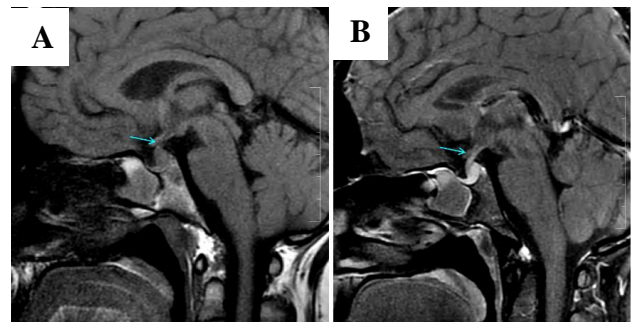


Images shows mass-like enlargement of the anterior pituitary with associated moderate contrast enhancement.

Figure 1: Imaging features suggestive of adenohypophysitis. (A): Sagittal T2w, (B): Post contrast T1w images.

Scenario 2

A 36 years old women presented with complaints of polyuria, polydipsia, galactorrhea, headache on and off. No history of visual complaints. She had no significant past medical history. Her pregnancy was unremarkable. Her family history was unremarkable for endocrine neoplasms or autoimmune conditions. Ophthalmologic evaluation and the physical examination were unremarkable.



Images shows thickening at the inferior aspect of the infundibulum and absence of posterior bright spot with associated intense contrast enhancement

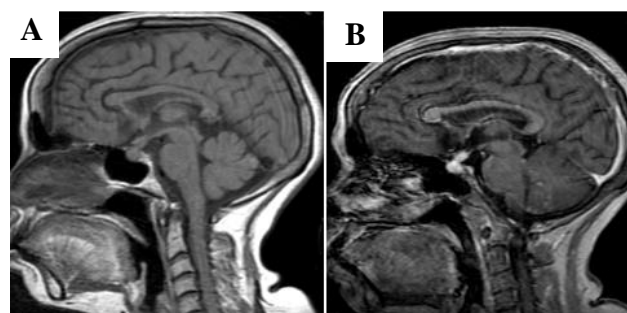
Figure 2: Imaging features suggestive of Infundibuloneurohypophysitis. (A): Sagittal T1w, (B): Post contrast T1w images.

Relevant laboratory investigations included an elevated serum prolactin of 77mg/L (normal:27mg/L). Her thyroid levels were found to be insufficient.

Contrast enhanced MRI of the Sella was done and showed thickening at the inferior portion of the infundibulum with loss of posterior pituitary bright spot. On contrast administration the infundibulum shows intense contrast. In view of her clinical, biochemical and radiological findings a diagnosis of infundibuloneurohypophysitis was given and patient was suggested asked for repeat MRI after 6months.

Scenario 3

A 60 years old female presented with history of giddiness on and off. She was a known case of tuberculous meningitis and was on treatment for the same. Her antenatal and family history was unremarkable. Her respiratory and cardiovascular systemic examination were unremarkable. Her neural examination was done, and she was found a bit drowsy, but however able to move all the four limbs with normal reflexes.



Images shows heterogenous thickened infundibulum, anterior and posterior pituitary gland and associated intense contrast enhancement.

Figure 3: Imaging features suggestive of panhypophysitis. (A): Sagittal T1w, (B): Post contrast T1w.

Relevant laboratory investigations included serum electrolytes which showed deranged Na^+ - 120, K^+ 2.9, Bicarb - 17 (normal values: K^+ - 3.5-5mmol/L, Na^+ - 135-145mmol/L, Bicarb - 18-30mEq/L). Her thyroid levels were elevated. CSF analysis was done in view of her history of meningitis which showed elevated counts.

In view of giddiness and drowsy state, contrast enhanced MRI of the brain was done. Study revealed heterogeneously thickened and hyperenhancing pituitary gland and the stalk. Based on her clinical, lab and radiological assessment a diagnosis of panhypophysitis was given and patient was started on steroids and antibiotics. A review scan 6months later, showed significant reduction in the pituitary gland and stalk size (response to steroids).

CONCLUSION

Hypophysitis is uncommon but being increasingly recognized in recent times due to advanced imaging techniques and increased awareness. It should consider as a differential diagnosis in case of any non-secreting pituitary mass, especially if presenting during pregnancy or post-partum period. Knowledge of the radiological presenting patterns of hypophysitis aids in raising the clinical suspicion in atypical clinical scenario.

Funding: No funding sources

Conflict of interest: None declared

Ethical approval: Not required

REFERENCES

1. Thodou E, Asa SL, Kontogeorgos G, Kovacs K, Horvath E, Ezzat S. Lymphocytic hypophysitis: clinicopathological findings. *J Clin Endocrinol Metab.* 1995;80:2302-11.
2. Scanarini M, d'Avella D, Rotilio A, Kitromilis N, Mingrino S. Giant-cell granulomatous hypophysitis: a distinct clinicopathological entity. *J Neurosurg.* 1989 Nov;71(5):681-6.
3. Folkerth RD, Price Jr DL, Schwartz M, Black PM, De Girolami U. Xanthomatous hypophysitis. *Am J Surg Pathol.* 1998 Jun 1;22(6):736-41.
4. Asa SL, Bilbao JM, Kovacs K, Josse RG, Kreines K. Lymphocytic hypophysitis of pregnancy resulting in hypopituitarism: a distinct clinicopathologic entity. *Ann Internal Med.* 1981 Aug 1;95(2):166-71.
5. Baskin DS, Townsend JJ, Wilson CB. Lymphocytic adenohypophysitis of pregnancy simulating a pituitary adenoma: a distinct pathological entity: Report of two cases. *J Neurosurg.* 1982 Jan;56(1):148-53.
6. Asa SL. Tumors of the pituitary gland, third series, fascicle 22. Washington, DC: Armed Forces Institute of Pathology. 1998.
7. Simmonds M. About the presence of giant cells in the pituitary gland. *Virchow's Arch Pathol Anatomy Physiol Clin Med.* 1917 Apr 1; 223 (3): 281-90.
8. Oishi M, Hayashi Y, Fukui I, Kita D, Miyamori T, Nakada M. Xanthomatous hypophysitis associated with autoimmune disease in an elderly patient: a rare case report. *Surgical neurology international.* 2016;7(Suppl 16):S449.
9. Bottazzo GF, Florin-Christensen A, Pouplard A, Doniach D. Autoantibodies to prolactin-secreting cells of human pituitary. *Lancet.* 1975 Jul 19;306(7925):97-101.
10. Crock P, Salvi M, Miller A, Wall J, Guyda H. Detection of anti-pituitary autoantibodies by immunoblotting. *J Immunol Methods.* 1993 Jun 4;162(1):31-40.
11. Scherbaum WA, Glück M, Schrell U, Fahlbusch R, Pfeiffer EF. Autoantibodies to pituitary corticotropin-producing cells: possible marker for unfavourable outcome after pituitary microsurgery for Cushing's disease. *Lancet.* 1987 Jun 20;329(8547):1394-8.
12. Pouplard A. 1982 Pituitary autoimmunity. *Horm Res.* 1982;16:289-97.
13. Mau M, Phillips TM, Ratner RE. Presence of anti-pituitary hormone antibodies in patients with empty sella syndrome and pituitary tumours. *Clin Endocrinol.* 1993 May;38(5):495-500.
14. Engelberth O, Ježková Z. Autoantibodies in Sheehan's syndrome. *Lancet.* 1965 May 15;285(7394):1075.
15. Mirakian R, Bottazzo GF, Cudworth AG, Richardson CA, Doniach D. Autoimmunity to anterior pituitary cells and the pathogenesis of

- insulin-dependent diabetes mellitus. *Lancet.* 1982 Apr 3;319(8275):755-9.
16. Kobayashi I, Inukai T, Takahashi M, Ishii A, Ohshima K, Mori M, et al. Anterior pituitary cell antibodies detected in Hashimoto's thyroiditis and Graves' disease. *Endocrinol Jap.* 1988;35(5):705-8.
 17. Hansen BL, Hegedüs L, Hansen GN, Hagen C, Hansen JM, Høier-madsen M. Pituitary-cell autoantibody diversity in sera from patients with untreated Graves' disease. *Autoimmunity.* 1989 Jan 1;5(1-2):49-57.
 18. Mark LP, Haughton VM. The posterior sella bright spot: a perspective. *Am J Neuroradiol.* 1990 Jul 1;11(4):701-2.
 19. Gutenberg A, Hans V, Puchner MJ, Kreutzer J, Brück W, Caturegli P, et al. Primary hypophysitis: clinical-pathological correlations. *European J Endocrinol.* 2006 Jul 1;155(1):101-7.
 20. Saiwai S, Inoue Y, Ishihara T, Matsumoto S, Nemoto Y, Tashiro T, et al. Lymphocytic adenohypophysitis: skull radiographs and MRI. *Neuroradiol.* 1998 Feb 1;40(2):114-20.
 21. Chelaifa K, Bouzaidi K, Harzallah F, Menif E, Ben Messaoud M, Turki I, et al. Lymphocytic hypophysitis. *J Neuroradiol.* 2002;29:57-60.
 22. Leggett DA, Hill PT, Anderson RJ. 'Stalkitis' in a pregnant 32-year-old woman: a rare cause of diabetes insipidus. *Austral Radiol.* 1999 Feb;43(1):104-7.
 23. Powrie JK, Powell Y, Ayers AB, Lowy C, Sönksen PH. Lymphocytic adenohypophysitis: magnetic resonance imaging features of two new cases and a review of the literature. *Clini Endocrinol.* 1995 Mar;42(3):315-22.
 24. Ahmadi J, Meyers GS, Segall HD, Sharma OP, Hinton DR. Lymphocytic adenohypophysitis: contrast-enhanced MR imaging in five cases. *Radiol.* 1995 Apr;195(1):30-4.
 25. McGrail KM, Beyerl BD, Black PM, Klibanski A, Zervas NT. Lymphocytic adenohypophysitis of pregnancy with complete recovery. *Neurosurg.* 1987 May 1;20(5):791-3.
 26. Bitton RN, Slavin M, Decker RE, Zito J, Schneider BS. The course of lymphocytic hypophysitis. *Surg Neurol.* 1991 Jul 1;36(1):40-3.
 27. Ozawa Y, Shishiba Y. Recovery from lymphocytic hypophysitis associated with painless thyroiditis: clinical implications of circulating antipituitary antibodies. *Acta Endocrinol.* 1993 Jun 1;128(6):493-8.
 28. Ober KP, Elster A. Spontaneously resolving lymphocytic hypophysitis as a cause of postpartum diabetes insipidus. *Endocrinol.* 1994 Mar 1;4(2):107-11.

Cite this article as: Kadiyala N, Murali A, Sai V. Spectrum and review of MRI findings in hypophysitis. *Int J Res Med Sci* 2018;6:3789-93.