

Case Report

Aesthetic management of complete calcific metamorphosis: a case report

Mona Tariq Aldaijy^{1*}, Laila Alsahaly²

¹Ministry of Health, ²Program Director, Saudi Board Restorative Dentistry, Riyadh, Saudi Arabia

Received: 04 August 2018

Accepted: 06 September 2018

***Correspondence:**

Dr. Mona Tariq Aldaijy,

E-mail: aldeijimona@gmail.com

Copyright: © the author(s), publisher and licensee Medip Academy. This is an open-access article distributed under the terms of the Creative Commons Attribution Non-Commercial License, which permits unrestricted non-commercial use, distribution, and reproduction in any medium, provided the original work is properly cited.

ABSTRACT

Calcific metamorphosis teeth are a great challenge to the clinician. Its diagnosis and treatment procedures are of utmost importance in providing the best treatment. Understanding the mechanism behind the discoloration of teeth is the key to get the best treatment. Internal bleaching is one conservative treatment for complete calcific metamorphosis in certain conditions, where signs and symptoms of periapicalpathosis are absent. The present paper involves a case study of 36 years old Saudi woman who faced an injury 20 years ago and presented with yellow discoloration. The patient was thoroughly informed regarding the case; all the plan options were discussed with her prior implementation. Treatment plan comprised of internal bleaching without any endodontic root canal treatment. Vital bleaching is comparatively expensive and was not chosen since the patient had financial issues. The internal bleaching proved a more economic option for her. The patient signed an informed consent form after considering all the details of the procedure.

Keywords: Calcific metamorphosis, Dental aesthetics, Dental trauma

INTRODUCTION

Dental trauma is a common issue to the primary and permanent dentition and gives rise to several complications and management challenges for the practitioners. Some common complications include the internal resorption, surface inflammation or replacement resorption, pulpal necrosis, invasive cervical resorption, and calcific metamorphosis.¹ Calcific metamorphosis (CM) is one particular complication that complicates entry into the root canal system and makes it difficult for practitioners to access the canal. CM has been defined as the pulpal response against the trauma resulting in rapid deposition of the hard tissue within the canal space.² CM also refers to calcific degeneration, dystrophic calcification, pulp canal obliteration, diffuse calcification,

and dystrophic calcification. In addition to the dystrophic calcification, CM is one of the most common responses towards dental trauma. However, the degree of response largely depends upon the severity of the trauma to the neurovascular in the apical foramen.³

Uncovering the calcified canals form a daunting process for dental practitioners.⁴ This study presents a case to reflect how the CM complications are managed aesthetically. The selected case presents calcification of the pulp space resulting from dental traumatic injury. CM is more common in the anterior teeth and it is possible to identify it three months earlier after an incidence of the injury. Sometimes, it remains undetected for even a year. Even the vital pulp testing maybe negative, irrespective if

the vital pulp is present; this is because of the increased dentine thickness.⁵

CM commonly occurs following traumatic injuries like luxation, subluxation, and concussion. It may occur as complete or partially obliteration of the root canals depending upon the severity of the injury of development stage of the tooth.⁶ The case also involves issue of trauma and discoloration. CM is asymptomatic and most of the time is identified based on yellow discoloration of the affected crown tooth. Discoloration occurs due to the thickness of dentine deposition. It is important to consider that color change takes place uniformly across all the teeth.⁵ Clinical relevance of the study can be stated by the fact that appropriate management of CM forms a challenging task for clinicians. They feel the need of making rational decisions for endodontic intervention that must be used or either the available restorative options such as aesthetic treatment.

CASE REPORT

A 36-years old Saudi woman presented to the clinic with discoloration in the upper anterior tooth. Her case history revealed a traumatic injury. She suffered 20 years ago due to falling from stairs. An extra-oral examination was performed to analyze functioning of different facial aspects. There were no such impacts found in the facial symmetry and the skin, lips, lymph, and muscular nodes were found in perfect working condition. There were no signs of pain or swelling identified and also no deviation or limitation for opening the mouth. In addition, an intra-oral examination was also performed to observe working of the tongue, palate, cheeks, mouth floor, and mucosa (Figure 1).

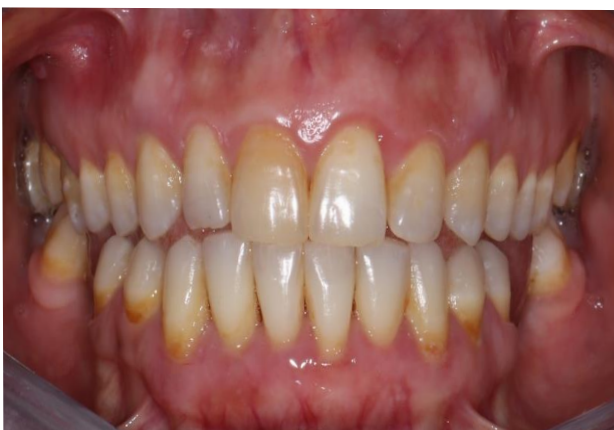

Figure 1: Preoperative frontal view showing discoloration of teeth.

A clinical examination revealed darkness in color on the upper right central incisor and the loss of cervical enamel. A panoramic periapical and cone beam computed tomographic scan was also performed (Figure 3). Reports revealed a complete calcified canal in the upper right central incisor with a normal periapical area, an intact

lamina dura, and no widening of the periodontal space (Figure 2). The patients was told regarding her condition and presented with the treatment options. After mutual discussion, the patient signed an informed consent form and showed her consent for internal bleaching without an endodontic intentional root canal treatment.

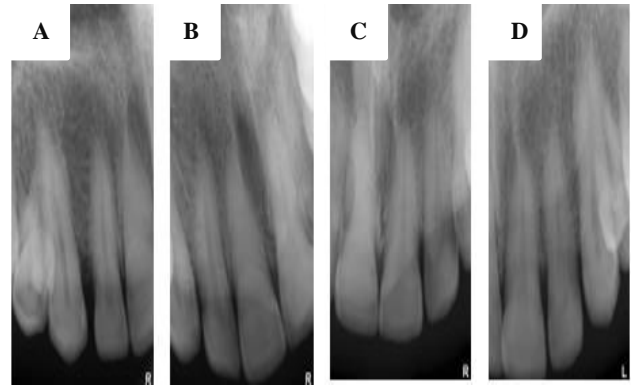


Figure 2: (A, B, C and D) Preapical radiograph of teeth.

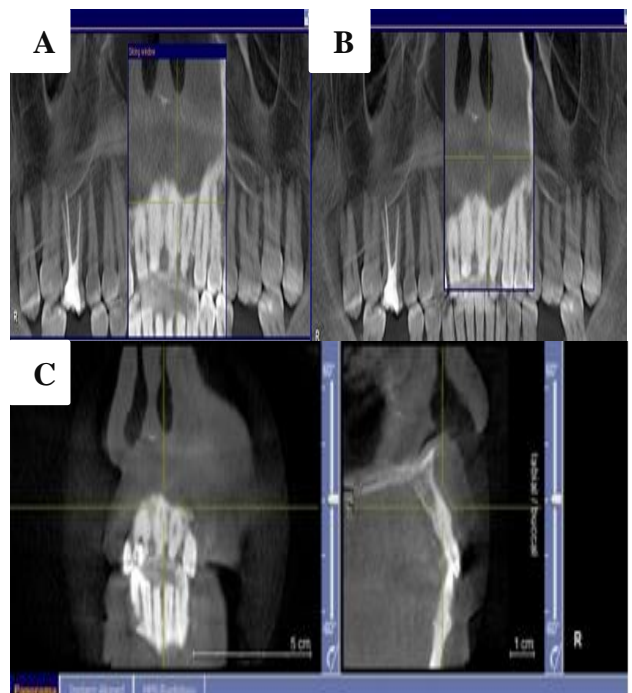


Figure 3: (A, B and C) Cone beam computed tomography CB-CT radiograph.

In order to perform the process, a before-treatment photograph was taken for future reference. Tooth shades were recorded in both the cervical and medial regions. At cervical, it was recorded at A3.5 whereas medially at A2. This process was performed using a VITA classical Shade Guide. The patient was administered with local anesthesia in the gingiva surroundings of the tooth. Rubber dam clamps #9 were used for the anterior teeth to isolate them from the tooth (Figure 4).

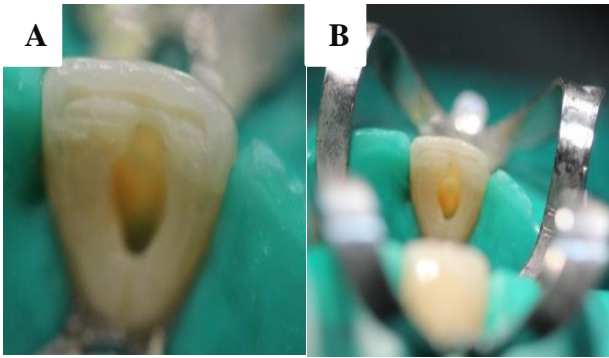


Figure 4: (A and B) Access preparation.

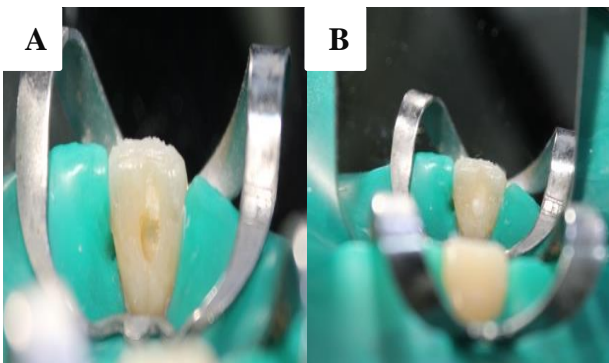


Figure 5: (A and B) Glass inomer cement base.



Figure 6: 35% hydrogen peroxide.

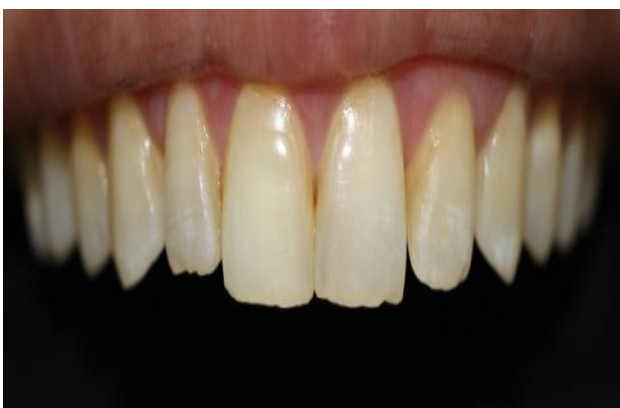

Figure 7: After a two-week follow-up.

Small grooves were made to access the cavity using the carbide round bur number #4 and tapered fissure bur

#170 with high-speed hand pieces and water cooling from the lingual side. A Glass ionomer cement (GIC) restoration was placed at the cemento-enamel junction (CEJ) level as a barrier; this was also assisted with a condenser and plastic instruments (Figure 5). Saline solution was used to irrigate the tooth chamber. Opalescence Endo (Ultradent Products, South Jordan, UT, USA), a 35% hydrogen peroxide specially formulated gel (pH 5) was applied using the “walking” bleach technique (Figure 6). The gel was also applied to the cavity. Finally, Cavit™ ESPE temporary filling material from 3M (Maplewood, MN, USA) with a high surface hardness was applied to seal the tooth. The patient was provided with postoperative instructions and asked to immediately notify if the temporary filling does not remain intact. A constant follow-up was taken from the patient at intervals one week; two weeks; and one month (Figure 7).

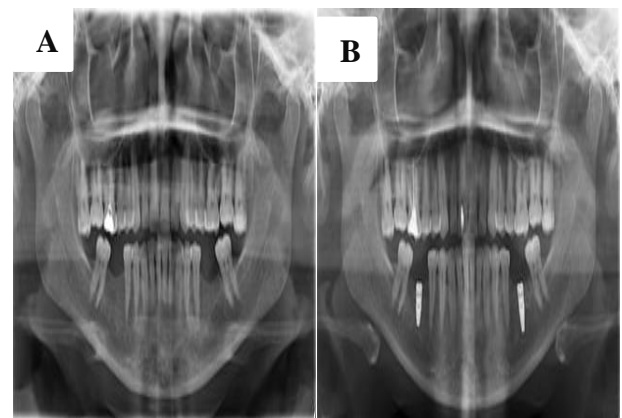


Figure 8: (A and B) Pre and post panoramic radiograph.

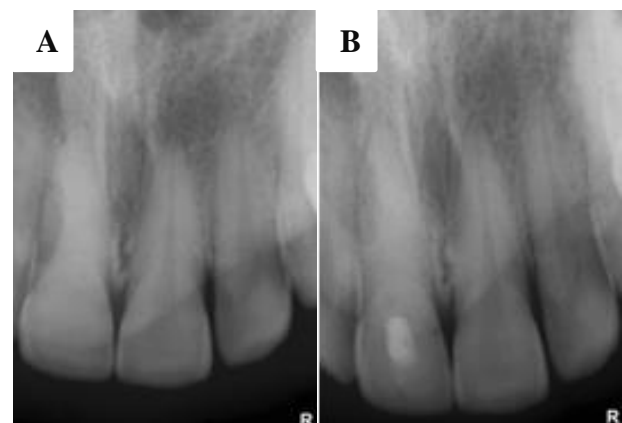


Figure 9: (A and B) Pre and post preapical radiograph.

The bleaching agent was changed after one week and two weeks. After the satisfied result, the access cavity was restored with a resin composite, using the acid-etch technique to improve the stability of the new color of the tooth and avoid recontamination with bacteria⁵. Figures 8 and 9 show the pre and post treatment panoramic and

periapical radiographs for evaluation of procedure's quality.

DISCUSSION

The case involves issue of traumatic injury, discoloration, and calcified canals. The case is significant since it addresses the challenge of uncovering calcified canals and its aesthetic management in CM. The case presents sound knowledge of root canal anatomy and the possible variations for its management. It is beneficial to first prepare the access cavity before the clinician places the rubber dam. This helps evaluate how the root functions along the tooth axis.⁷ Once the practitioner is successful in locating the canal, he should immediately place the rubber dam before further treatment is done. It is important that the access cavity must be kept of normal shape and size.⁸ Change in the dentine colour in the root's center helps determine the root canal position.

For deciding root canal treatment, practitioners must show sound knowledge towards the canal anatomy and also the possible variations. This greatly helps them prepare a better access to the cavity prior placing the rubber dam. Further, this helps in evaluation of the root relationships and work over the longer axis of the tooth. The rubber dam was placed once the canal was located followed with further treatment execution. The access cavity was kept normal size and shape and the change in dentine color was used to gain indications for position of the canal. It is also recommended to use indicators such as bubble test using sodium hypochlorite or methylene blue for visualizing location of the calcified canal.^{9,10}

The first and foremost step to deal with CM is to consider the rational options for treatment. Teeth showing pulp obliteration with no periapical disease can be managed conservatively through period radiographic examination along and clinical observation.^{11,12} Tooth assessment can also be performed using Periapical Index (PAI). PAI scores equivalent to 3 or above indicates for root canal treatment.¹³

It is suggested that root canal treatment must be performed that do not respond towards thermal and electrical tests and are tender to percussion. Vitality tests conducted in the given study confirmed non-vitality of the teeth and indicated presence of the pathological condition making it important to attempt the root canal treatment. The patient was warned regarding any risks involved and particularly the perforation risk while accessing the root canal and the possible danger of instrument separation.

Use of operating microscope is indispensably required to localise the calcified canals.¹⁴ Using the microscope makes it easier for the practitioner to reach the pulp chamber floor. High-intensity light beams are used to reveal the intimate details in the area or otherwise the risks of inaccessibility increases.¹⁵ Even the slightest difference in calcification and color patterns may

subsequently become obvious that serve as the guiding light to remove the obstructions. Therefore, it was used in the present case to assess anatomy of the involved teeth.

Radiographic images taken at multiple angles are necessary for making deep access preparations; this helps maintain the direction and alignment. It might be beneficial to remove the rubber dam in certain situation. In the given case, it obstructed the visualisation of canal for radiograph and therefore was removed to allow clear radiographs. Initial path finding can be performed through small files. However, they must show certain level of rigidity to transverse the restricted spaces. One particular approach is to alternate the size between 8 and 10 k files applying minimal vertical pressure with gentle watch-winding motion. Instruments should be replaced with regular intervals before fatigue occurs.¹⁶

The incidence of CM in traumatic injuries ranges from 4-24%.¹⁷ In CM cases, typically, the anterior teeth show a high dentin deposition rate of 3.5µm/day as compared to the average normal rate of 2.8µm/day for deciduous teeth and 1.5µm/day for permanent teeth.¹⁸ There is no pulp chamber found in the CM if viewed radiographically. Moreover, the lamina dura remains intact without preapical lesions and when there is no widening in the periodontal membrane space. Radiographical diagnosis of CM requires a complete or partial obliteration of the pulp chamber and canal. However, a complete obliteration does not require a complete absence of the pulp or canal space, as the apparent radiographic diameter of the canal does not always correspond to its true width. In contrast, a partial obliteration is when pulp chamber is not visible and the canal is markedly narrowed but still visible.

It is necessary to consider a few endodontic concerns regarding clinical management of the CM. Firstly, continuous follow-up and observations must be taken from the patient before making the decision to intervene as studies reveal that development of pathology is 1-16% suspected in the calcified tooth. Secondly, a conventional endodontic approach should be considered in cases of the pulpal pathology if there is no endodontic surgical management option left for the practitioners. The notable aesthetic considerations for CM management include the use of vital (external) bleaching with hydrogen peroxide; this should be considered as a first option.¹⁸ However, the clinical success of this technique is dependent on the thickness of the dentin and irregularity of the reparative dentin. In addition, internal bleaching with intentional root canal treatment should also be considered.¹⁹ It was also found that osteoid tissue with cellular inclusions adjacent to mineralized areas in the pulp could have been observed due to either an initial calcification of isolated pulp tissue components or epithelio-mesenchymal interactions.²⁰

If the trauma leads to discoloration of teeth, this means that patients has aesthetic concerns and must be addressed accordingly. External bleaching forms the most

suitable option that must be preferred. Since the dentin is formed in an irregular reparative manner and therefore decreases the translucency and acquisition of the yellowish color, external bleaching of the enamel may not result in significant outcomes. It is possible to facilitate internal bleaching through an intentional root canal treatment. This can be done regardless the pulp is vital or necrotic.²¹ Lundberg and Cvek showed that content of collagen increases in the permanent maxillary incisors after the trauma with markedly decreased cell number.²²

CONCLUSION

Successful outcomes depend upon the ability to access the canal and removal of the deposited dentine. There might be situations where dentine deposits restrict the access to the canal affecting the treatment. Bleaching forms an essential element of the aesthetic management of CM and must be performed. It is a simple, affordable yet a conservation procedure that may bring excellent results by using a 35% hydrogen peroxide gel.

Funding: No funding sources

Conflict of interest: None declared

Ethical approval: Not required

REFERENCES

- Malhotra N, Mala K. Calcific metamorphosis. Literature review and clinical strategies. *Dental Update.* 2013;2:40(1):48-60.
- Munley PJ, Goodell GG. Calcific metamorphosis. Clinical Update for Naval Postgraduate Dental School. 2005;27(4).
- Kuster CG. Calcific metamorphosis/internal resorption: a case report. *Pediatr. Dent.* 1981;3(3):274-5.
- Koli P, Pujar M, Yalgi V, Uppin V, Vagarali H, Hosmani N. Ultrasonic management of calcified canal: a case report. *Oral surgery, oral Medicine, Oral radiology.* 2014;2(2):11-3.
- Lise DP, Gutiérrez C, Da Rosa TP, Vieira LC. Bleaching Options for Pulp-Calcified Teeth: Case History Reports. *Operative dentistry.* 2014;39(6):572-7.
- Rotstein I, Walton RE. Bleaching discolored teeth: internal and external. In: Walton RE, Torabinejad M, eds. *Principles and practice of endodontics.* 3rd ed. Philadelphia: W.B. Saunders Company;2002:408.
- Vertucci FJ. Root canal morphology and its relationship to endodontic procedures. *Endodontic Topics.* 2005;10:3-29.
- Amir FA, Gutman JL, Witherspoon DE. Calcific metamorphosis: a challenge in endodontic diagnosis and treatment. *Quintessence Int.* 2001;32(6):447-55.
- Bab I, Lustmann J, Azaz B, Gazit D, Garfunkel A. Calcification of noncollagenous matrix in human gingiva: a light and electron microscopic study. *J Oral Pathol.* 1985;14:573-80.
- Appleton J, Williams MJR. Ultrastructural observations on the calcification of human dental pulp. *Calcif Tissue Res.* 1973;11:222-37.
- Schindler WG, Gullickson DC. Rationale for the management of calcific metamorphosis secondary to traumatic injuries. *J Endodontics.* 1988;14(8):408-12.
- Robertson A, Andreasen FM, Bergenholtz G, Andreasen JO, Norén JG. Incidence of pulp necrosis subsequent to pulp canal obliteration from trauma of permanent incisors. *J Endodontics.* 1996 Oct 1;22(10):557-60.
- Oginni AO, Adekoya-Sofowora CA, Kolawole KA. Evaluation of radiographs, clinical signs and symptoms associated with pulp canal obliteration: an aid to treatment decision. *Dental Traumatol.* 2009 Dec;25(6):620-5.
- Carr GB, Murgel CA. The Use of operating microscope in endodontics. *Dental Clinics North America.* 2010;54(2):191-214.
- Selden HS. The role of dental operating microscope in improved nonsurgical treatment of calcified canals. *Oral Surg Oral Med Oral Pathol.* 1989;68(1):93-8.
- Allen MJ, Glickman GN, Griggs JA. Comparative analysis of endodontic pathfinders. *J Endodontics.* 2007 Jun 1;33(6):723-6.
- Patterson S, Mitchell D. Calcific metamorphosis of the dental pulp. *Oral Surg Oral Med Oral Pathol.* 1965;20:94-101.
- Goga R, Chandler NP, Oginni AO. Pulp stones: a review. *Int Endod J.* 2008;41:457-68.
- McCabe PS, Dummer PMH. Pulp canal obliteration: an endodontic diagnosis and treatment challenge. *Int Endod J.* 2011;45:177-97.
- Amir FA, Gutman JL, Witherspoon DE. Calcific metamorphosis: a challenge in endodontic diagnosis and treatment. *Quintessence Int.* 2001;32(6):447-55.
- Munley PJ, Goodell GG. Calcific metamorphosis. Clinical Update for Naval Postgraduate Dental School. 2005;27(4).
- Lundberg M, Cvek M. A light microscopy study of pulps from traumatized permanent incisors with reduced pulpal lumen. *Acta Odontol Scand.* 1980;38:89-94.

Cite this article as: Aldaijy MT, Alsahly LM. Aesthetic management of complete calcific metamorphosis: a case report. *Int J Res Med Sci* 2018;6:3782-6.