

## Case Report

# Correction of kyphotic deformity due to neglected fracture dislocation thoracolumbar spine with posterior vertebral column resection

Andhika Yudistira, Syaifullah Asmiragani, Ery Satriawan\*

Spine Division of Department of Orthopedic & Traumatology, Brawijaya University, Saiful Anwar General Hospital Malang, East Java, Indonesia

**Received:** 18 November 2018

**Accepted:** 29 December 2018

### \*Correspondence:

Dr. Ery Satriawan,

E-mail: [ery\\_triple8@yahoo.co.id](mailto:ery_triple8@yahoo.co.id)

**Copyright:** © the author(s), publisher and licensee Medip Academy. This is an open-access article distributed under the terms of the Creative Commons Attribution Non-Commercial License, which permits unrestricted non-commercial use, distribution, and reproduction in any medium, provided the original work is properly cited.

## ABSTRACT

Kyphotic deformity is serious problem for sagittal spinal balance and resulting back pain, neurologic impairment, and also cosmetic problem. Post traumatic kyphotic deformity most common occur following unstable spine. A circumferential approach with anterior release via discectomies and corpectomies, followed by posterior instrumentation and fusion has been the standard of care. This is a case of progressive post traumatic kyphotic deformity due to fracture dislocation which was performed laminectomy without posterior instrumentation and successfully corrected with single step posterior vertebral column resection.

**Keywords:** Kyphotic deformities, Laminectomy, Posterior vertebral column resection, Thoracolumbar fracture-dislocation

## INTRODUCTION

Kyphotic deformity is serious problem for sagittal spinal balance and resulting back pain, neurologic impairment, and cosmetic problem. The etiologies of kyphosis include degenerative disc disease, neuromuscular disease, spinal tumors, post-traumatic and surgical iatrogenic causes.<sup>1,2</sup> Post traumatic kyphotic deformity most common occur following unstable spine. Laminectomy as an isolated procedure for spinal cord decompression in burst fracture or fracture dislocation should not be performed as it increase instability, promotes neurological deficits and progression of khyphosis.<sup>3,4</sup> We reporting a case of progressive after traumatic kyphotic deformity due to fracture dislocation which was performed laminectomy without posterior instrumentation.

## CASE REPORT

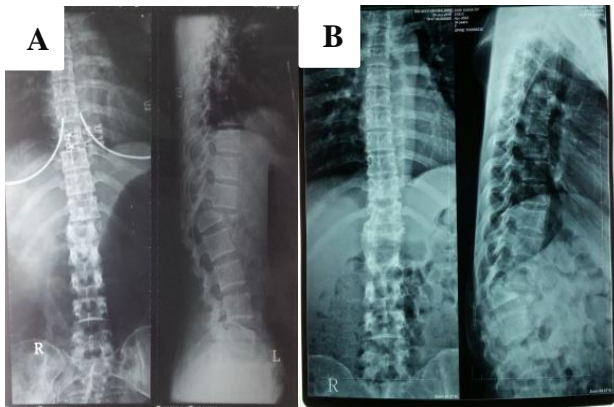
A 34-years-old female was admitted to the hospital due to pain in the back and unable to move both lower extremity

since 1 year previously. Patient brought to the hospital and underwent surgery. Previous surgery just performed laminectomy for neural decompression without any reduction and instrumentation. From the initial thoracolumbar x-ray after trauma, there was fracture dislocation of thoracic XII-lumbar I vertebra with regional Cobb's angle 30 degrees and progression of khyphosis became 50 degrees (Figure 1).

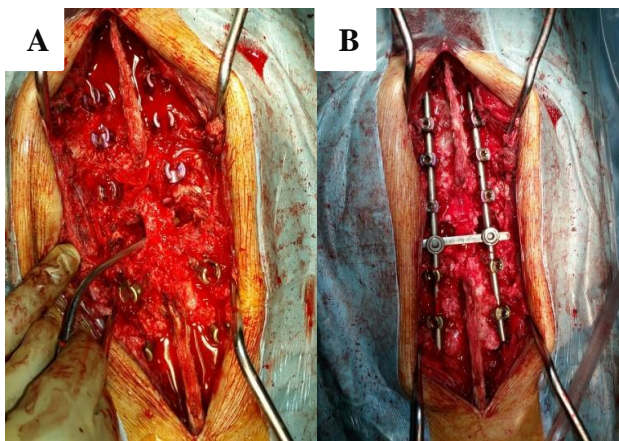
We performed posterior decompression, posterior instrumentation and kyphotic deformity correction by total posterior spondylectomy (VCR) of vertebra lumbar I and anterior column bone graft using corticocancellous graft (fibula). There was no laceration nor transection of spinal cord (Figure 2).

One day after surgery, patient recovered well without any complication. From the thoracolumbar radiograph, cobb's angle was decreased to 12 degrees. One week after surgery, patient started to feel burning sensation in both lower leg and also pain was decrease significantly with

VAS 3-4 and more comfortable. Patient was able to sit with TLSO and mobilization with wheelchair within 2 weeks after operation.



**Figure 1: A) Thoracolumbar radiograph after injury. B) 1 year after laminectomy, khyphosis progress become 50 degrees.**



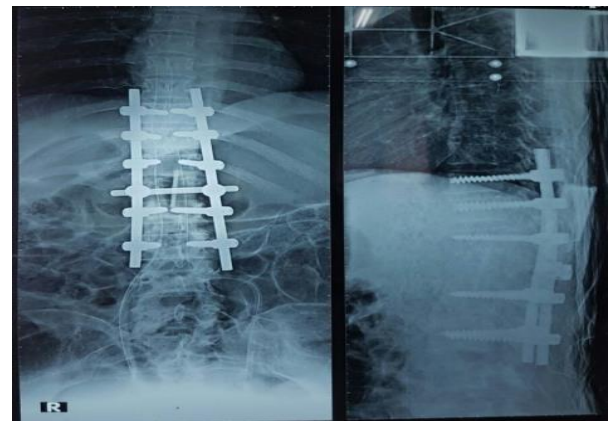
**Figure 2: After performing posterior VCR. A) Autologous corticocancellous fibular graft inserted to anterior column B) and posterior column supported with pedicle screw.**

## DISCUSSION

Fracture dislocation of spine is the most unstable type of spinal injury with failure of all 3 column.<sup>1</sup> Surgical intervention with decompression of neurologic element must be followed by reduction of abnormal alignment and stabilization with spine fusion. Failure to reduce and stabilize the spine, kyphosis progression will be consequence.<sup>2,3</sup> In this case there was progression of kyphosis, from 30 degree to 50 degree of Cobb's angle.

Many techniques have been described to achieve correction of severe angular kyphotic deformities of spine. A circumferential approach with anterior release via discectomies and corpectomies, followed by posterior instrumentation and fusion has been the standard of care, but double approach of surgery will increase morbidity,

higher risk of injury to anterior vascular and visceral structures, prolongation of operation time, and higher cost.<sup>4-6</sup> Therefore in correction of kyphotic deformity in this case, we used PVCR. Wafa and Elbadrawi in their 40 cases study of PVCR, found that the mean operative time is 249minute and blood loss 850ml.<sup>2,8</sup> In this case, operation time was 330minutes with blood loss 1800ml. More time consumed and blood loss as a consequence of bony union in the anterior column. Suk et al, reported a correction of 61.9 degrees in the coronal plane and 45.3. degrees in sagittal plane in their series of 70 patients.<sup>9,10,11</sup> In this case we corrected about 38 degrees in sagittal plane of deformity (Figure 3). There was no complication after surgery, consider the patient was complete neurologic deficit from trauma. However, one nerve root (Th XII) on one side was sacrificed during surgery to achieve access to put corticocancellous graft in the anterior column.



**Figure 3: Post operative thoracolumbar radiograph showed the kyphosis decrease about 38 degrees.**

## CONCLUSION

Thoracolumbar fracture-dislocation is unstable type of spine fracture and laminectomy as an isolated procedure should not be performed in unstable spine. Because of laminectomy alone will make fracture more unstable and progression of deformity. Posterior vertebral column resection using fibula was effective and efficient for achieving adequate correction of kyphotic deformity in thoracolumbar junction.

*Funding: No funding sources*

*Conflict of interest: None declared*

*Ethical approval: Not required*

## REFERENCES

1. Schwartz E, Flanders A. Spinal trauma: Imaging, Diagnosis, and Management. Philadelphia, PA: Lippincott Williams Wilkins; 2007:317.
2. Zhang H, Liu S. Posterior vertebral column resection for rigid angular kyphosis. *Chinese J Orthopaed.* 2009;29(12):1099-103.

3. Munting E. Surgical treatment of post-traumatic kyphosis in Thoracolumbar spine: indications and technical aspects. *Eur Spine J.* 2010;19(suppl 1):S69-S73.
4. Jain A, Kumar S. Neglected musculoskeletal injuries. New Delhi: Jaypee Brothers Medical Publishers; 2010:2.
5. Ozer KT, Elias CA. Iatrogenic spinal deformities. *Turkish Neurosurg.* 2014;24(1):75-83.
6. Khatri K, Farooque K, Sharma V, Gupta B, Gamanagatti S. Neglected thoraco lumbar traumatic spine injuries. *Asian Spine J.* 2016 Aug 1;10(4):678-84.
7. Walker C, Ballestro C, Iborra M, Ubierna, MT, Tomasi SO. Adult spinal deformity: sagittal imbalance. *Int J Orthopaedics.* 2014;1(3):64-72.
8. Zhou T, Li C, Liu B, Tang X, Su Y, Xu Y. Analysis of 17 cases of posterior vertebral column resection in treating thoracolumbar spinal tuberculous angular kyphosis. *J Orthopad Surg Res.* 2015 Dec;10(1):64.
9. Kim B, Dan JM, Shin DE. Treatment of Thoracolumbar fracture. *Asian Spine J.* 2015;9(1):133-46.
10. Vetrile ST, Kuleshov MS, Vetrile MS, Chelpachenko OB. Surgical treatment of extended kyphotic deformities of the thoracic and lumbar spine. *Digest of spine surgery J.* 2014;2:(C.47-54).
11. Jian-zheng Z, Zhi L, Ji-xin R, Tian-sheng S. Modified decancellation posterior closing-wedge osteotomy for correction of traumatic thoracolumbar kyphotic deformity: a cadaveric and preliminary clinical study. *Int J Phys Med Rehabil.* 2014;2:5.

**Cite this article as:** Yudistira A, Asmiragani S, Satriawan E. Correction of kyphotic deformity due to neglected fracture dislocation thoracolumbar spine with posterior vertebral column resection. *Int J Res Med Sci* 2019;7:610-2.