

Case Report

Alcohol and tobacco induced infiltrating ductal carcinoma male: a case report

Akhila Janga Yadav*, Bhavana Pamulapati Chowdary, Divya Bharathi Jekkula Yadav, Rajender Penthala, Vineeth Bonkuri

Department of Pharmacy Practice, St.Peters Institute of Pharmaceutical Sciences, Warangal, Telangana, India

Received: 23 November 2018

Accepted: 29 December 2018

*Correspondence:

Dr. Akhila Janga Yadav,

E-mail: akhila2795@gmail.com

Copyright: © the author(s), publisher and licensee Medip Academy. This is an open-access article distributed under the terms of the Creative Commons Attribution Non-Commercial License, which permits unrestricted non-commercial use, distribution, and reproduction in any medium, provided the original work is properly cited.

ABSTRACT

Male breast cancer is a rare cancer that forms in the breast tissue of men, it accounts for 1% of all the cancers in men. Recent epidemiological studies suggest that the incidence of MBC is increasing by 1.1% per year. Due to lack of knowledge and awareness, MBC cases are diagnosed lately, mostly during stages III /IV. Early detection and reduction of mortality and morbidity related to male breast cancer is essential. The present article provides a detailed study of a patient with Infiltrating ductal carcinoma, grade III with regional nodal metastasis and the patient is positive for both oestrogen and progesterone receptors. In this case the patient is alcoholic and had habit of chewing tobacco since childhood and one of the patient's relative had female breast cancer. These are the probable risk factors in this particular case. The better knowledge regarding the male breast carcinoma can be obtained through the thorough study of the available male breast cases.

Keywords: Adjuvant radiation therapy, Infiltrating breast carcinoma, Klinefelter syndrome, Mastectomy, Neoplastic lesions, Nipple retraction

INTRODUCTION

Among various rare cancers observed male breast carcinoma accounts for 1 % among men.¹ Recent epidemiological studies suggest that the incidence of MBC is increasing by 1.1% per year. As these are rare they are mostly undiagnosed till the end stages like stage III/IV, which is due to lack of knowledge and awareness among the general population. Among them 40% of cases are associated with cirrhosis, testicular trauma, obesity.² The risk of MBC enhances due to various factors which may be pathological or environmental. Pathological include mutations in BRCA 1 or BRCA 2 genes, or inherited DNA changes like transduction pathways, whereas environmental include tobacco, alcohol, modified life style changes. The clinical manifestations most commonly observed include nipple retraction or

discharge, painless lump, pain and ulceration.³ The NCCN guidelines suggest that men with breast cancer should be treated using the guidelines for post-menopausal women with consideration of patient preference.⁴ Based upon the stage of carcinoma surgery or radiation are preferred. The present article provides a detailed study of a Infiltrating male breast carcinoma case, observed during our internship.

CASE REPORT

A 45-year-old Indian male was referred to Susrutha Cancer Hospital on 25, July 2017 complaining a small ulcer in the left breast since 2 months and then it progressed with pain and discharge. The patient reported no alleviating or aggravating factors. Previous medical and surgical history did not appear to contribute to the present illness. He denied using drugs or anabolic

steroids, or any exposure to radiation. He admitted drinking alcohol occasionally and he had a habit of chewing tobacco since childhood. Family history includes, one of the patient's relative had female breast cancer. The patient had no known drug allergies and he used NSAIDs occasionally. He reported normal sexual life with 2 children. Patient is alert and oriented to place, person and time. He has no distress but was very concerned about lump in the left breast. Vital signs include, temperature 98 Fahrenheit, heartrate 80beats/minute and regular respiration with 18/minute and blood pressure was 120/80mmHg, height 165cm, weight 50kgs and body mass index is 18.4 which indicate underweight.

General examination

- The patient is lean and has no loss of appetite and denied any shortness of breath.
- 2D Echo reveals no LV RWMA and good LV systolic function and had no pericardial effusion. Chest X-ray PA view was normal. Ultra sound scanning of whole abdomen reveals cholelithiasis (receiving 300mg ursodeoxycholic acid) and bilateral grade I renal parenchymal changes.

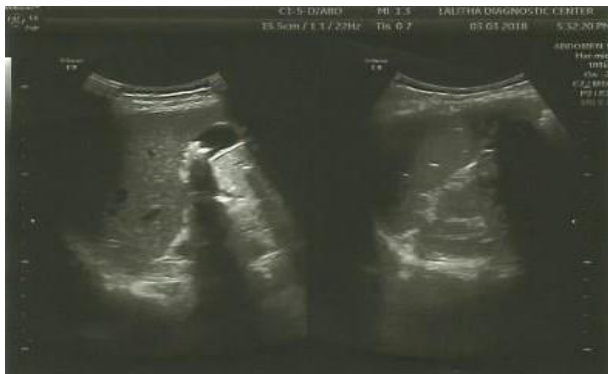

Figure 1: Ultra sound abdomen.

Histopathology analysis

Biopsy from ulcerated left breast was sent to HPE, and sections show pigmented skin with a neoplastic lesion in the sub epithelial stroma composed of infiltrating, atypical cells arranged predominantly in sheets, focal trabeculae and occasional ducts of moderately pleomorphic atypical cells with vesicular nucleus, prominent nucleolus in abundant densely desmoplastic stroma. The lesion is extending up to the surgical resection margins at foci. Other margins are free from lesion. Finally the features are consistent with infiltrating breast carcinoma.

No randomized clinical trials to date have evaluated treatment of men with breast cancer. The patient condition was more evaluated before starting of the treatment. The patient and his attenders were informed

priorly regarding the diagnosis done, pathological findings, stage of the disease and further plans for chemotherapy, surgery or radiation. As patient lump is not feasible for the surgery, based on the condition chemotherapy was first preferred rather than surgery.

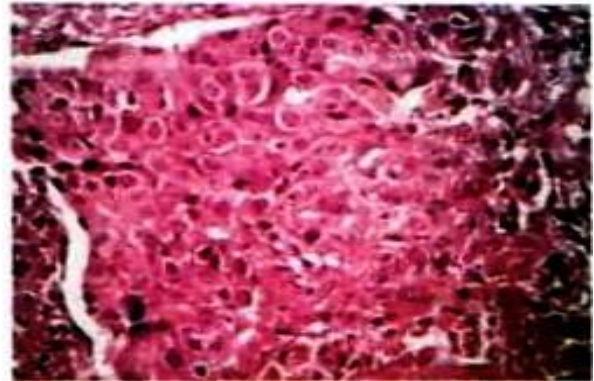


Figure 2: Infiltrating breast carcinoma.

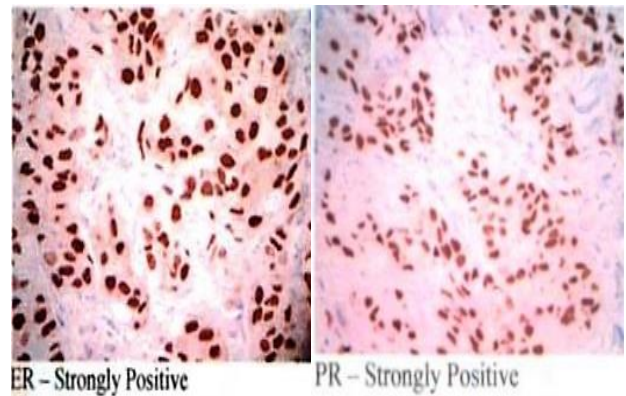


Figure 3: Immunohisto-chemistry reveals oestrogen and Progesterone status. (A): Oestrogen ER positive, (B): Progesterone PR positive.

After complete analysis of diagnostic reports patient has started with chemotherapy; doxorubicin 77mg (slow infusion) and endoxon770mg (slow IV) for 4 cycles (26/07/2017 to 26/10/2017) and evaluated the condition. Along with these drugs supportive therapy was also given which includes ondansetron 16mg, dexamethasone 8mg, ranitidine 300mg, 1 pint 5% dextrose and 1 pint dextrose normal saline for 4 cycles with a gap of 21 days for a cycle to next. Post chemotherapy includes ondansetron 16mg, ranitidine 300mg, a multivitamin capsule and sufficient IV fluids were administered (as patient is with grade I renal parenchymal changes). During these 4 cycles of chemotherapy patient was evaluated for any abnormalities in blood urea and creatinine levels. Meanwhile regular evaluation of the patient was done regarding the effects of chemotherapy given. Next 4 cycles of chemotherapy (22/11/2017 to 12/02/2018) was changed to Paclitaxel 270mg infusion for 3hours along with supportive therapy. Blood urea and creatinine levels, complete blood picture and any abnormalities if present

were observed and patient has discharged with a review confirmation after 15 days.

After 25 days of completion of chemotherapy, surgery was recommended for this patient by the oncology team. The patient was referred to a surgeon and plans were made to prepare for surgery. Blood test for HBs Ag, HCV, and HIV were negative, and RBS and blood pressure were normal. Surgery has done (on 07/03/2018) with all required precautions. Left elliptical incision was taken and upper and lower flaps raised. Breast tissue and parts of pectoralis major muscle removed, and axillary clearance done. Drain kept and incision closed. After completion of surgery patient was on antibiotics and other required supportive treatment for next 7 days (up to 12/03/2018) and discharged with a review after 10 days for adjuvant radiation therapy. In blocking the development of potential cancer cells, the oncology team recommended radiation therapy. 50 Grays of radiation was given in 25 fractions from 29/03/2018 to 01/05/2018.

During patient education, the benefit of continuing treatment plan was stressed and need for follow-up treatment was discussed. Patient education was also given about chemotherapy side effects to watch for such as changes in appetite, mucositis, and signs of alopecia. Information regarding life style modifications, medication adherence, and diet to follow were informed to patient attenders.

DISCUSSION

As male breast carcinoma is rare, and no definite pathogenesis evidence is available for the disease, most of the risk factors are considered as probable. According to the International Agency for Research on Cancer, tobacco smoking and alcohol consumption are considered as Group 1 carcinogen.⁵ They have been associated with increased risk of various cancers. There is evidence that supports the plausibility of causality-such as detection of tobacco smoke constituents in breast tissue, fluid and milk, and *in vitro* carcinogenic transformation of human breast epithelial cells. In men, there is evidence both for and against associations between alcohol consumption and circulating sex steroid hormone concentrations. Due to increase ethanol intake estrogen concentrations increases and cell proliferation gets activated which is regarded as primary hypothesis. Patient with positive family history is also a most predominant factor to be considered. Patients with a positive first degree family history have a 2.0 times greater risk, which increases to more than 5.0 times with the number of affected relatives and relatives of the first onset, thus suggesting an important role of genetic factors in the risk of MBC.⁶ When compared with women, men with breast carcinoma has more positivity rate receptor.⁷ In several studies, ER and PR positivity was reported 75-93%.

CONCLUSION

As we know male breast carcinoma is extremely rare, early detection and reduction of mortality and morbidity related to male breast cancer is essential. In this case, patient is diagnosed with Infiltrating ductal carcinoma, grade III with regional nodal metastasis and the patient is positive for both oestrogen and progesterone receptors. Despite an absence of a genetic disease, the patient is alcoholic and had habit of chewing tobacco since childhood and one of the patient's relative had female breast cancer (No confirmation). These are the probable risk factors in this particular case, other than this the causative factors for this patient were unable to identify. The exact mechanism of male breast carcinoma is not adequately understood; hence, through the thorough study of the available male breast carcinoma cases the better knowledge regarding the male breast carcinoma can be obtained.

ACKNOWLEDGEMENTS

Authors would like to thank Dr. Hemanth Kumar, Dr. Rajeev Chowdary, Dr. Devender Kodeti and Mr. Rajeev Gollapalli for their support and guidance.

Funding: No funding sources

Conflict of interest: None declared

Ethical approval: Not required

REFERENCES

1. Fentiman IS. Male breast cancer: a review. *ecancer*. 2009;3:140.
2. Rushton M, Kwong A, Visram H, Graham N, Petrlich W, Dent S. Treatment outcomes for male breast cancer: a single-centre retrospective case-control study. *Current Oncol*. 2014 Jun;21(3):e400.
3. Harlan LC, Zujewski JA, Goodman MT, Stevens JL. Breast cancer in men in the United States: a population-based study of diagnosis, treatment, and survival. *Cancer*. 2010 Aug 1;116(15):3558-68.
4. Onami S, Ozaki M, Mortimer JE, Pal SK. Male breast cancer: an update in diagnosis, treatment and molecular profiling. *Maturitas*. 2010 Apr 1;65(4):308-14.
5. Korde LA, Zujewski JA, Kamin L, Giordano S, Domchek S, Anderson WF, et al. Multidisciplinary meeting on male breast cancer: summary and research recommendations. *J Clin Oncol*. 2010 Apr 20;28(12):2114.
6. Comet B, Cutuli B, Penault-Llorca F, Bonnetterre J, Belkacemi Y. Male breast cancer: a review. *Bulletin du cancer*. 2009 Feb;96(2):181-9.
7. Yalaza M, İnan A, Bozer M. Male breast cancer. *The J Breast Health*. 2016 Jan;12(1):1.

Cite this article as: Yadav AJ, Chowdary BP, Yadav DBJ, Penthala R, Bonkuri V. Alcohol and tobacco induced infiltrating ductal carcinoma male: a case report. *Int J Res Med Sci* 2019;7:613-5.