

Case Report

Cutaneous tumours of vascular origin: two rare entities

Annu E. Prakash^{1*}, Gopalan Sulochana², Thundiparampil Thankappan³,
Annamma M. Oommen²

¹Department of Pathology, Sree Narayana Institute of Medical Sciences, Ernakulam, Kerala, India

²Department of Pathology, ³Department of Dermatology, Pushpagiri Institute of Medical Sciences, Tiruvalla, Kerala, India

Received: 01 January 2019

Accepted: 30 January 2019

*Correspondence:

Dr. Annu E. Prakash,

E-mail: annelizprakash@gmail.com

Copyright: © the author(s), publisher and licensee Medip Academy. This is an open-access article distributed under the terms of the Creative Commons Attribution Non-Commercial License, which permits unrestricted non-commercial use, distribution, and reproduction in any medium, provided the original work is properly cited.

ABSTRACT

Skin and subcutaneous tissue are the most common location of benign and malignant vascular tumors. The benign or malignant nature of the lesion may not always be identified clinically because of the varying presentations. The histology of the lesion, especially in malignancies may not exhibit definite vascular pattern. In such cases, clinical presentation has to be correlated with histopathological picture as well as immunohistochemical characteristics to reach a specific diagnosis. Judicious use of immunohistochemical markers proves to be invaluable. Two rare cases of cutaneous vascular tumors which presented at our institution are cited, the diagnosis of which involved correlation of these modalities.

Keywords: Epithelioid angiosarcoma, Immunohistochemistry, Malignant vascular tumours, Skin tumours, Verrucous hemangioma, Vascular neoplasms

INTRODUCTION

Vascular tumours present a broad spectrum of morphological features which render it difficult to distinguish between benign and malignant forms. The most frequent sites of occurrence are the skin and subcutaneous tissue. Vascular neoplasms may originate from the endothelial lining, pericytes or glomus cells. Their histology is characterized by the presence of vascular elements in varying patterns, not always recognizable as such. Ultrastructural features of endothelial cells include several pinocytotic vesicles, microvilli, cytoplasmic microfilaments, continuous basal lamina and Weibel-Palade bodies. Vascular markers such as CD 31, CD 34, vWF, podoplanin and FLI 1 play an important role in identifying these neoplasms. CD 31 is reportedly the most sensitive and specific among these,

whereas CD 34 has a broader spectrum of reactivity.¹ Vascular neoplasms are classified as benign, intermediate and malignant based on their clinical behaviour.² It is often difficult to differentiate between vascular malformations and neoplasms as well as to identify the origin and nature of the neoplasm. Here authors present two cases of vascular tumour of the skin where the combination of clinical examination, histopathology and immunohistochemistry aided in the diagnosis.

CASE REPORTS

Case 1

An 84-year-old man presented with a localized erythematous plaque measuring 3x2cm, on the dorsal aspect of nose (Figure 1), which showed rapid increase in

size. The lesion showed varying consistency on palpation. Biopsies were taken from the hard as well as the soft areas.

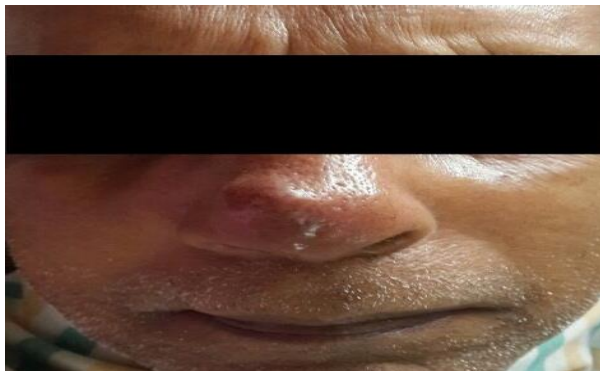

Figure 1: Epithelioid angiosarcoma presenting as an erythematous plaque on the dorsum of nose.

Microscopy showed sections of skin with flattened epidermis and a thin Grenz zone. Subepithelial region showed sheets and lobules of large cells with pale eosinophilic cytoplasm and vesicular nuclei with prominent eosinophilic nucleoli. Irregular cells with scanty cytoplasm and hyperchromatic nuclei were also seen (Figure 2).

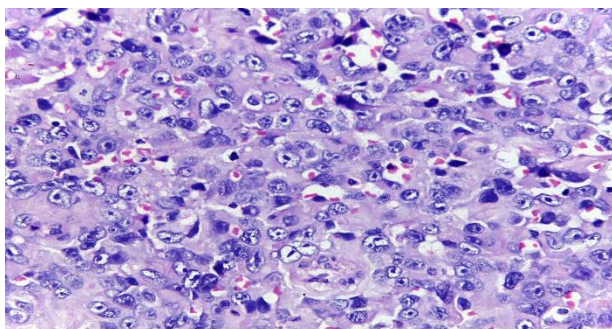


Figure 2: Histopathology of neoplastic cells with scanty cytoplasm and irregular hyperchromatic nuclei. Hematoxylin and eosin, 40 X.

Tumor cells were positive for CD 31 (Figure 3), CD 34 and focally positive for LCA. CK and HMB were negative.

Considering all these findings, diagnosis was given as a vascular tumor with epithelioid morphology suggestive of Epithelioid angiosarcoma.

Case 2

A 27-year-old man presented with multiple hyperpigmented hyperkeratotic verrucous plaques and papules over both lower legs for 4 years. A punch biopsy was taken from the lesion on the left leg.

Microscopy shows epidermis showing hyperkeratosis, papillomatosis and acanthosis. Superficial and deep vessels show dilated and congested capillaries and veins (Figure 4). Diagnosis was given as Verrucous Hemangioma.

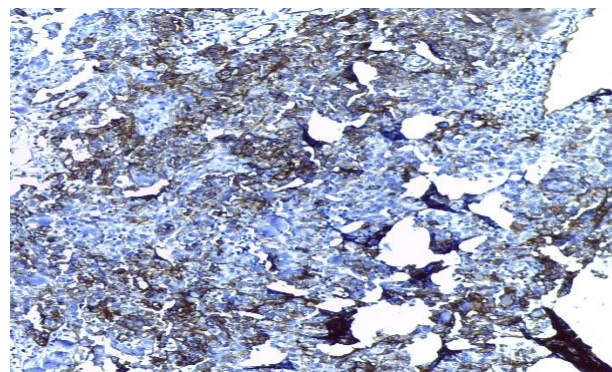


Figure 3: Neoplastic cells showing positivity for CD 31.

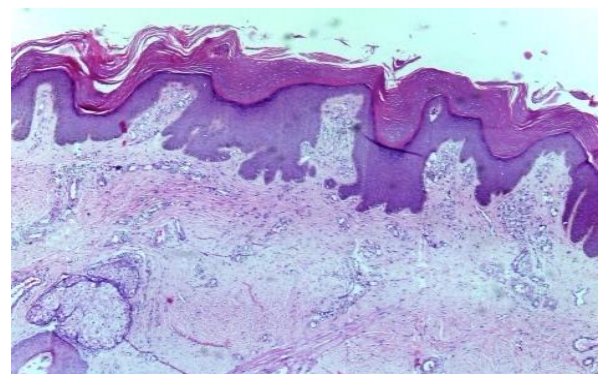


Figure 4: Histopathology of Verrucous hemangioma showing epidermal changes and thin walled blood vessels in dermis. Hematoxylin and Eosin, 10 X.

DISCUSSION

Epithelioid angiosarcoma is a rare neoplasm which denotes the malignant end of the spectrum of epithelioid vascular tumours. It has been reported in various locations such as head and neck, adrenals, thyroid, pleura, pulmonary artery, breast, bone and vagina.¹ Epithelioid angiosarcoma of skin and soft tissue has been recently acknowledged as a distinctive entity. This type of tumor is characterized by poor differentiation and biological aggressiveness.³ They present as rapidly growing tumors in middle aged to elderly males. Histology shows large cells with epithelioid features arranged in sheets showing cleft like vascular spaces and occasional papillary formations. The epithelioid appearance is possibly due to the accumulation of intermediate filaments including vimentin. Histological differential diagnoses include epithelioid hemangioendothelioma and poorly differentiated carcinomas.^{2,4} Epithelioid hemangioendothelioma, despite sharing many histological features with epithelioid angiosarcoma, is a

low-grade neoplasm with little pleomorphism and low malignant potential. Poorly differentiated carcinoma lacks features like slit like vascular spaces and cytoplasmic vacuolations containing red blood cells.

Epithelioid angiosarcoma often demonstrates early nodal and solid organ metastasis, especially to the lungs, bone, soft tissue, and skin.² Wide resection is advised considering the aggressive nature of the neoplasm. Advanced age of the patient, increased tumor size, and increased proliferation index are factors adversely affecting the prognosis.

The term Verrucous Hemangioma was coined by Halter in 1937 but it was described as a specific entity in 1967 by Imperial and Helwig.^{5,6} It is an uncommon angiomatous lesion of skin and subcutaneous tissue, lower extremities being the most common site of occurrence. It is a structural variant of capillary or cavernous hemangioma in which hyperkeratosis, acanthosis and papillomatosis occur as a reactive change.^{6,7} These lesions are commonly detected at birth or during early years of life and may show increase in size and number. Rarely, they may present in adulthood also. The lesions are usually seen as hyperkeratotic, bluish, and partly confluent papules and plaques on the legs, trunk and arms. They have not yet been classified definitely as a neoplasm or as a vascular malformation since they show features of both.⁸ Unlike other hemangiomas, they do not involute with time and have to be excised.

Histology shows epidermal hyperkeratosis and acanthosis with numerous thin walled vessels extending to deep dermis. Verrucous hemangioma is distinguished from its closest differential, angiokeratoma by deep tissue involvement.^{6,9} Recurrence is frequent in verrucous hemangioma following physical treatments like cryotherapy because of the involvement of the deeper tissue and possibly because of altered hemodynamics opening up preexisting noncanalized malformed vessels.^{6,10} Early diagnosis and surgical removal is necessary for satisfactory cosmetic results.

CONCLUSION

Vascular lesions, both reactive and neoplastic, are common in skin and subcutaneous tissue.

Epithelioid angiosarcoma is a markedly aggressive malignancy which is difficult to diagnose by histology alone. A panel of vascular markers including CD31,

CD34, FLI 1, vWF, Ulex lectin and type IV collagen can be used to identify endothelial differentiation.

Verrucous hemangioma is a rare benign lesion with a high chance of recurrence. Early detection and treatment prevent worsening of the condition.

Funding: No funding sources

Conflict of interest: None declared

Ethical approval: Not required

REFERENCES

1. Calonje JE, Fletcher CDM. Vascular Tumours. In: Fletcher CDM. *Diagnostic Histopathology of Tumors*. Vol 1. 4th ed. Philadelphia, PA: Elsevier Saunders; 2013:70-71.
2. Hart J, Mandavilli S. Epithelioid Angiosarcoma. A Brief Diagnostic Review and Differential Diagnosis. *Arch Pathol Lab Med*. 2011;135(2):267-72.
3. Sakamoto A, Takahashi Y, Oda Y, Iwamoto Y. Aggressive clinical course of epithelioid angiosarcoma in the femur: a case report. *World J Surgical Oncol*. 2014;12:281.
4. Muzumder S, Das P, Kumar M, Bhaskar S, Sarkar C, Medhi K, et al. Primary epithelioid angiosarcoma of the breast masquerading as carcinoma. *Current Oncol*. 2010;17(1):64.
5. Halter K. Haemangioma verrucosum mit Osteoatrophie. *Dermatol*. 1937;75(5):271-9.
6. Imperial R, Helwig EB. Verrucous hemangioma: A clinicopathologic study of 21 cases. *Arch Dermatol*. 1967; 96:247-53.
7. Koc M, Kavala M, Kocatürk E, Zemheri E, Zindanci I, Sudogan S, et al. An unusual vascular tumor: verrucous hemangioma. *Dermatol Online J*. 2009;15(11).
8. Mestre T, Amaro C, Freitas I. Verrucous haemangioma: a diagnosis to consider. *Case Reports*. 2014;2014.
9. Kaliyadan F, Dharmaratnam AD, Jayasree MG, et al. Linear verrucous hemangioma. *Dermatol Online J* 2009;15:15.
10. França ER, Gurgel A, Campos T, Souza JA, França K, Azevedo R. Verrucous hemangioma. *Bras Dermatol*. 2006;81(5):S290-2.

Cite this article as: Prakash AE, Sulochana G, Thankappan TP, Oommen AM. Cutaneous tumours of vascular origin: two rare entities. *Int J Res Med Sci* 2019;7:952-4.