

## Original Research Article

# Cemented monoblock hemiarthroplasty: a dependable option in femoral neck fracture in elderly

Santosh Kumar, Vikas Verma\*, Sanjiv Kumar

Department of Orthopaedics, King George Medical University, Lucknow, Uttar Pradesh, India

**Received:** 06 January 2019

**Revised:** 10 February 2019

**Accepted:** 01 March 2019

### \*Correspondence:

Dr. Vikas Verma,

E-mail: [surgeonvikas@yahoo.co.in](mailto:surgeonvikas@yahoo.co.in)

**Copyright:** © the author(s), publisher and licensee Medip Academy. This is an open-access article distributed under the terms of the Creative Commons Attribution Non-Commercial License, which permits unrestricted non-commercial use, distribution, and reproduction in any medium, provided the original work is properly cited.

## ABSTRACT

**Background:** Femoral neck fracture in elderly continues to pose a treatment dilemma. Associated co-morbidities and high mortality (1-year mortality of 25–30% and only 25% survivorship at 10 years) often skews the surgical decision. The underlying treatment goal is minimum revision and maximum functional outcome. Lack of clear guidelines is reflected by the continued debates regarding their management namely osteosynthesis vs arthroplasty; hemiarthroplasty vs total hip arthroplasty, unipolar vs bipolar and cemented vs uncemented. A review of joint registries, uniformly suggest that cemented fixation in elderly patient results in early mobilization, less residual pain and the lowest risk of revision. We analyzed clinical outcome of cemented monoblock hemi-arthroplasty (modified design) in femoral neck fracture in elderly.

**Methods:** Total 94 cemented hemiarthroplasty, performed since January 2009, with a minimum follow up of 3 years are included in the study. Mean modified Harris Hip score at 2 years, 3 years and in the last follow up was 88 (72-91), 84 (70-89) and 81 (65-86) respectively. Acetabular erosion was noted in three patients (3.19%) (one was symptomatic) and aseptic loosening in another two patients (2.12%). Major complications such as deep wound infection, dislocation or peri-prosthetic fracture were not noted in any patient.

**Results:** Result of the present study is consistent to marginally superior when compared to cemented Thompson monoblock and the cemented bipolar prostheses. We attribute this to routine use of cement in the elderly osteoporotic bone along with design modification of the monoblock stem. Long term result of THA is marginally (not statistically significant) better compared to hemiarthroplasty. However, it is associated with prolonged surgery, more blood loss and higher dislocation rate. The rates of dislocation following THA, bipolar and unipolar arthroplasty were 11%, 3%, and 2% respectively.

**Conclusions:** Cemented monoblock hemiarthroplasty is effective and viable option in displaced femoral neck fracture in elderly in terms of excellent functional outcome, low reoperation without adversely affecting morbidity and mortality. Being cost effective procedure this may be considered as first line surgical option especially in socio-economically disadvantaged section of the society.

**Keywords:** Cement, Elderly, Hemiarthroplasty, Monoblock, Neck of femur

## INTRODUCTION

Fracture neck of femur in elderly continues to pose a dilemma to Orthopaedic surgeon. Patient's mobility,

morbidity, life expectancy, financial constraints (especially in developing nations) and expectations are major considerations in the decision making. The underlying goal of any modality of treatment is to

minimize revisions and maximize the functional outcome. A survey conducted in United Kingdom reported that there is lack of consensus on choosing the treatment option for this fracture.<sup>1</sup> The surgical options available are internal fixation, hemi arthroplasty or total hip arthroplasty (THR). A study reported that unipolar implants may be considered sufficient for oldest patients with more comorbidities.<sup>2</sup> A Cochrane systematic review has reported no difference in results of unipolar versus bipolar prosthesis.<sup>3</sup> A study comparing internal fixation with arthroplasty has reported 30% revision rates with internal fixation but lower survival rates with arthroplasty.<sup>4</sup> A study on ten year results of internal fixation and arthroplasty has reported a 45.6% failure rate with internal fixation compared with 8.8% with replacement.<sup>5</sup> They reported similar rates (75%) of mortality ten years. Significantly lower rates of impaired walking and severe pain have been reported in arthroplasty compared to internal fixation.<sup>6</sup> In comparison with internal fixation, arthroplasty for the treatment of a displaced femoral neck fracture has been reported to significantly reduce the chance of revision surgery, at the cost of greater infection rates, blood loss, and operative time and possibly an increase in early mortality rates.<sup>7,8</sup> Studies that compared internal fixation with arthroplasty in elderly patients of fracture neck femur have reported a higher rates of painful hip and revision with internal fixation but similar mortality rates.<sup>9-10</sup> However a study has reported higher mortality rates at 1 month in the arthroplasty although the difference was not significant.<sup>11</sup> Reasons for revision include either osteonecrosis (16-19%) or non-union (23- 33%). It is also reported that clinical outcome of secondary arthroplasty<sup>11-15</sup> after failed attempt of osteosynthesis is not satisfactory in majority of patients. This is because by the time the decision to do an arthroplasty is taken; the patients are already confined to the wheelchair with limited potential for rigorous demands of rehabilitation. Furthermore, THR performed after failed fixation results in more residual pain and worse function when compared with primary THR.<sup>12-15</sup> Recent literature largely favours using arthroplasty over fixation in elderly patients of fracture neck of femur.<sup>7-11</sup> Most randomized control trials (RCT) and metanalysis support hemiarthroplasty over total hip arthroplasty (THA) in elderly patients of femoral neck fracture.<sup>16-18</sup> The reason cited are associated co-morbidities and high mortality at one and 5 year (30% and 75% respectively) after hip fracture.<sup>19-21</sup> Besides, THA is associated with prolonged surgery, more blood loss and higher dislocation rate.

Regarding hemiarthroplasty, there are proponents of bipolar prosthesis which has the theoretical advantage of reducing acetabular erosion. Clinical results are however ambiguous and it is established that at one-year movement of the inner head ceases due to fibrosis.<sup>22,23</sup> Furthermore, better result with bipolar could be due to its use in relatively younger patients and this four times costlier (compared to Thompson prosthesis) implant is not ethically warranted in patients presenting to our setup

as most of these patients hail from lower socio-economical strata.

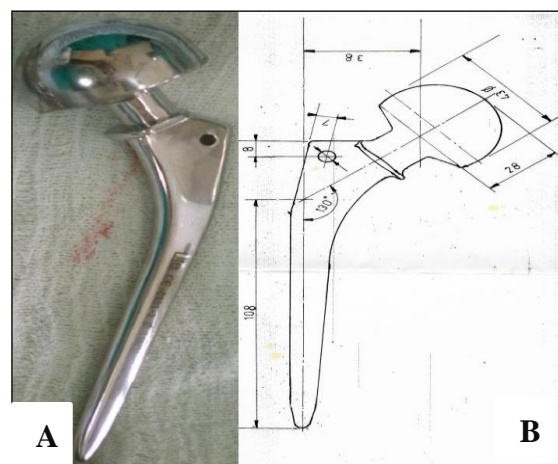
An element of uncertainty and lack of clear guidelines is reflected by the continued debate regarding use of Thompson and Austin Moore prosthesis.<sup>21-24</sup> These two popular (in UK, Australia) prosthesis have witnessed design modifications such as uncemented Austin-Moore prosthesis with a hydroxyapatite-coated Furlong prosthesis, cemented Muller and Exeter monoblock design but their superiority is yet not established.<sup>24</sup>

Cemented vs uncemented prosthesis further intrigues the treating surgeons.<sup>25-27</sup> Cemented stem has the merit of immediate secure fixation, early mobility, less residual pain, less revision and better survivorship benefit. A Cochrane study noted lower risk of intraoperative femur fracture when using cement.<sup>28</sup> Whereas advocates of uncemented stem draws attention to the risk of cardiovascular compromise and prolonged surgery associated with cement use.

There is a paucity of studies conducted on Indian patients that have described long term functional outcome following the use of cemented monoblock hemiarthroplasty to treat elderly patients with fracture neck of femur. The objective of this retrospective study was to describe the outcome of cemented monoblock hemiarthroplasty (modified design) in femoral neck fracture in elderly population. Functional outcome at a minimum follow up of three years was the primary end point while revision rate, morbidity and complication were secondary outcome.

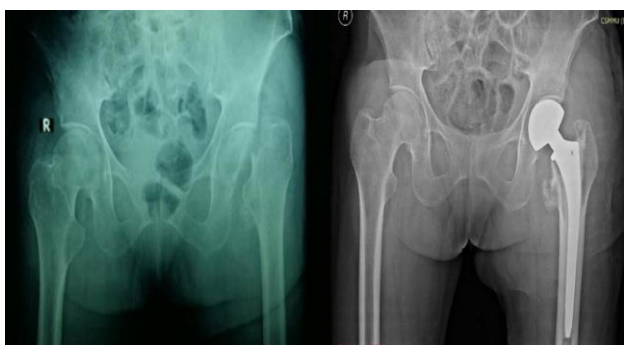## METHODS

Patients aged more than 60 years with femoral neck fracture and treated by monoblock (unipolar) cemented hemiarthroplasty were included in the study (Figure 1A and 1B).



**Figure 1: Monoblock cemented design prosthesis along with its schematic representation of measurements.**

Patients with more than three years follow up were included in the study. Patients with poor mental condition, pathological fracture, rheumatoid arthritis and those of ASA grade V are not managed using monoblock cemented hemiarthroplasty in our centre. All the operations were performed by the senior author (SK) using a modified Hardinge anterolateral approach with the patient in the lateral decubitus position. After preparation of the femoral canal (reaming, cleaning and drying) a distal restrictor (Harding's) was first inserted at appropriate depth followed by application of low viscosity cement. Proximal seal was used to pressurize the cement in the canal. Patients were mobilized from the next day with crutches or walking frame. After six weeks they were permitted to mobilize without further restriction.



**Figure 2: Radiographs of the pelvis AP view showing preoperative and postoperative neglected fracture neck of femur in a female patient aged 65 years.**

The patients were reviewed at 6 weeks, 3 month and then every 6 month. Peri-operative data, including intra-operative blood loss, need for blood transfusion and duration of surgery, were recorded. At every follow up modified Harris Hip Score and visual analogue scores was documented. Any complication such as deep wound infection, dislocation, peri-prosthetic fracture, radiological signs of loosening of the femoral component and radiological signs of acetabular erosion were also recorded (Figure 2). SPSS 13.0 for Windows statistical software (SPSS Inc., Chicago, Illinois) was used.

## RESULTS

There were 94 cemented hemiarthroplasty, performed since January 2009, with a minimum follow up of 4 years are included in the study. 56 were female and 38 were male (female to male ratio 1.47) with mean age of 66.5 (60-74) year. Our mean follow up was 4.6 (4-7.6) years. Mean duration of surgery was 58minute range being 50-80 minute. Four patients developed wound hematoma (4.16%) and another four (4.16%) had superficial infection which was treated using extended oral antibiotics for 3 weeks. The choice of antibiotic was based on the results of culture and sensitivity. None of the patients had deep infection. Major complications such as deep wound infection, dislocation or peri-prosthetic

fracture were not reported in any patient. Three patients (3.12%) had groin and or thigh pain. Two of them underwent revision at 3 and 5 years follow up while the third patient opted to continue with oral analgesics. Critical analysis of radiograph showed acetabular erosion in three patients (3.19%) of which one had groin pain while others were asymptomatic. Another two (2.12%) patients had groin pain due to aseptic loosening of stem.

At a mean follow up of 4.6 years the mean modified Harris Hip score was 84 (70-89). Mean modified Harris Hip score at 2 year, 3 year and in the last follow up was 88 (72-91), 84 (70-89) and 81 (65-86) respectively. Visual analogue score for pain averaged 2.1 (1.6 to 3.4). The mean duration of hospital stay was 14.2 days (12-21 days).

## DISCUSSION

Average hospital stay in our study was 14.2 (12-21) days which is longer than the standard protocol. A majority of our patients hail from far flung rural areas without any facilities for rehabilitation and therefore patients are discharged after initiating rehabilitation. We noted that HHS reaches a maximum score at 18 months, maintains a plateau and then start declining after three years despite no evidence of stem subsidence or acetabular erosion. We attribute this to the natural course of ageing process. Bauer et al, similarly observed that the functional score reaches its peak at one year and then it either maintains a plateau or declines.<sup>29</sup>

A study by Friensendorff V et al, states that for an elderly patient with limited life expectancy, a quick procedure which can achieve pain free mobility with minimum risk of revision in their remaining life should be the surgical goal. Our results with cemented hemiarthroplasty satisfactorily achieved the said goal. Result of the present study is consistent to marginally superior when compared to cemented Thompson monoblock and the cemented bipolar prostheses in terms of functional outcome (ambulation, activities of daily living, Harris Hip Score, pain, and satisfaction).<sup>29,30</sup> We attribute our superior result to higher neck cut possible with the new design which improves offset and neck-shaft angle and achieves better cement pressurization due to modified stem design. The new monoblock stem has added advantage of easy conversion to THR as the conventional Thompson's bow and surface finish is modified. This observation is consistent with the reported decline of Thompson's monoblock and bipolar arthroplasty in Australia and United States.<sup>34</sup> In order to make future revision of Thompson prosthesis easier Faraj et al<sup>35</sup> suggested that femoral neck osteotomy could be performed well above the calcar femoris without detrimental complications.

Compared to hemiarthroplasty, THA has marginally better functional outcome at 5 years and longer follow up but this difference has not been found to be statistically significant.<sup>16-21,34</sup> However, total hip arthroplasty is a

more demanding procedure and causes more blood loss. Furthermore, cost difference assumes importance in developing countries (constrained health budget) with ever increasing incidence of these fractures. Finally, the rate of dislocation following THA is significantly higher (11%) when compared with hemiarthroplasty (3% with bipolar and 2% with unipolar arthroplasty).<sup>31-34</sup> None of our case required revision either due to dislocation or peri-prosthetic fracture.

In the hemiarthroplasty there are two viable option such as bipolar and unipolar arthroplasty. Proponents of bipolar advocates reduction of acetabular erosion and thereby better functional outcome. Proponents of unipolar state that movement of the inner head ceases due to fibrosis at about one year and thereafter it functions like unipolar.<sup>22,23,30-33</sup> The better result obtained with bipolar could be due to its use in relatively younger age group. We believe that bipolar arthroplasty which is four times costlier is not warranted in the elderly patients.

Cement was used in all our cases as it achieved immediate stability and integrates well with osteoporotic bone.<sup>25-28</sup> Our routine use of cement in the elderly patients get support of Porte L et al, who also emphasized that osteoporosis interferes with bone ingrowth and congruent fit; both of these preclude establishment of rigid initial stability.<sup>36</sup> Furthermore, a review of all joint registries uniformly suggests that cemented fixation in elderly patient results in the lowest risk of revision.<sup>39,40-45</sup>

Gromov et al, noted failure before 5 years was more likely in cementless femoral components than cemented femoral components (91% versus 44%) and stated that increased use of cementless fixation in primary THA lead to inferior survivorship.<sup>40</sup> Despite this there is a clear trend to avoid potential risk of cardiac arrhythmias and cardio-respiratory collapse prior information to anesthetist and optimizing cement pressurization are warranted.<sup>38-40</sup> Retrospective design of the study and small number of patients are certain limitations of the study however based on the follow up of 6 years fair conclusion can be drawn from the study" to "Retrospective design of the study and small number of patients are limitations of our study. However, a long duration of follow up adds to the strength of the study.

## CONCLUSION

Cemented monoblock hemiarthroplasty is effective and viable option in displaced femoral neck fracture in elderly in terms of excellent functional outcome, low reoperation without adversely affecting morbidity and mortality. Being cost effective this may be considered as first line surgical option especially in socio-economically disadvantaged section of the society.

*Funding: No funding sources*

*Conflict of interest: None declared*

*Ethical approval: The study was approved by the Institutional Ethics Committee*

## REFERENCES

1. Crossman PT, Khan RJ, MacDowell A, Gardner AC, Reddy NS, Keene GS. A survey of the treatment of displaced intracapsular femoral neck fractures in the UK. *Injury* 2002;33:383-6.
2. Rogmark C, Leonardsson O. Hip arthroplasty for the treatment of displaced fractures of the femoral neck in elderly patients. *Bone Joint J.* 2016;98-B:291-7.
3. Parker MJ, Gurusamy KS, Azegami S. Arthroplasties (with and without bone cement) for proximal femoral fractures in adults. *Cochrane Database Syst Rev.* 2010;(6):CD001706.
4. Davison JNS, Calder SJ, Anderson GH, Ward G, Jagger C, Harper WM and Gregg PJ. Treatment for displaced intracapsular fracture of the proximal femur. A prospective randomized trial in patients aged 65 to 79 years. *J Bone Joint Surg Br.* 2001;83-B:206-12.
5. Leonardsson O, Sernbo I, Carlsson A, Akesson K, Rogmark C. Long-term follow-up of replacement compared with internal fixation for displaced femoral neck fractures: results at ten years in a randomised study of 450 patients. *J Bone Joint Surg Br.* 2010;92(3):406-12.
6. Rogmark C, Carlsson A, Johnell O, Sernbo I. A prospective randomised trial of internal fixation versus arthroplasty for displaced fractures of the neck of the femur. Functional outcome for 450 patients at two years. *J Bone Joint Surg Br.* 2002;84(2):183-8.
7. Keating JF, Grant A, Masson M, Scott NW, Forbes JF. Randomized comparison of reduction and fixation, bipolar hemiarthroplasty, and total hip arthroplasty. Treatment of displaced intracapsular hip fractures in healthy older patients. *J Bone Joint Surg Am.* 2006;88(2):249-60.
8. Bhandari M, Devereaux PJ, Swiontkowski MF, Tornetta 3rd P, Obremskey W, Koval KJ, et al. Internal fixation compared with arthroplasty for displaced fractures of the femoral neck. A meta-analysis. *J Bone Joint Surg Am.* 2003;85-A(9):1673-81.
9. Rogmark C, Johnell O. Primary arthroplasty is better than internal fixation of displaced femoral neck fractures: a meta-analysis of 14 randomized studies with 2,289 patients. *Acta Orthop.* 2006;77(3):359-67.
10. Blomfeldt R, Törnkvist H, Ponzer S, Söderqvist A, Tidermark J. Comparison of internal fixation with total hip replacement for displaced femoral neck fractures: randomized, controlled trial performed at four years. *Am J Bone Joint Surg.* 2005;87-A:1680-8.
11. Jing Wang and Baoguo Jiang and Roger J. Marshall and Peixun Zhang. Arthroplasty or internal fixation

- for displaced femoral neck fractures: which is the optimal alternative for elderly patients? A meta-analysis. *International Orthopaedics (SICOT)*. 2009;33:1179-87.
12. Leonardsson O, Rogmark C, Kärrholm J, Åkesson K and Garellick G. Outcome after primary and secondary replacement for subcapital fracture of the hip in 10 264 patients. *Br J Bone Joint Surg*. 2009;91-B:595-600.
  13. Nilsson LT, Stromqvist B, Thorngren KG. Secondary arthroplasty for complications of femoral neck fracture. *Br J Bone Joint Surg*. 1989;71-B:777-81.
  14. McKinley JC, Robinson CM. Treatment of displaced intracapsular hip fractures with total hip arthroplasty: comparison of primary arthroplasty with early salvage arthroplasty after failed internal fixation. *Am J Bone Joint Surg*. 2002;84-A:2010-15.
  15. Blomfeldt R, Tornkvist H, Ponzer S, Soderqvist A, Tidermark J. Displaced femoral neck fracture: comparison of primary total hip replacement with secondary replacement after failed internal fixation: a 2-year follow-up of 84 patients. *Acta Orthop*. 2006;77:638-43.
  16. Baker RP, Squires B, Gargan MF, Bannister GC. Total hip arthroplasty and hemiarthroplasty in mobile, independent patients with a displaced intracapsular fracture of the femoral neck. A randomized, controlled trial. *J Bone Joint Surg Am*. 2006;88(12):2583-9.
  17. Blomfeldt R, Törnkvist H, Eriksson K, Söderqvist A, Ponzer S, Tidermark J. A randomized controlled trial comparing bipolar hemiarthroplasty with total hip replacement for displaced intracapsular fractures of the femoral neck in elderly patients. *J Bone Joint Surg Br*. 2007;89(2):160-5.
  18. Hedbeck CJ, Enocson A, Lapidus G, Blomfeldt R, Törnkvist H, Ponzer S, et al. Comparison of bipolar hemiarthroplasty with total hip arthroplasty for displaced femoral neck fractures: a concise four-year follow-up of a randomized trial. *J Bone Joint Surg Am*. 2011;93(5):445-50.
  19. Vochteloo AJH, Niesten DD, Riedijk R, Rijnberg WJ, Bolder SBT, Koëter S, et al. Cemented versus non-cemented hemiarthroplasty of the hip as a treatment for a displaced femoral neck fracture: design of a randomised controlled trial *BMC Musculoskeletal Disorders*. 2009;10:56.
  20. Foss NB, Kehlet H. Mortality analysis in hip fracture patients: implications for design of future outcome trials. *Br J Anaesth*. 2005;94:24-9.
  21. vonFriesendorff M, Besjakov J, Akesson K. Long-term survival and fracture risk after hip fracture: a 22-year follow-up in women. *J Bone Miner Res*. 2008;23:1832-41.
  22. Raia FJ, Chapman CB, Herrera MF, Schweppe MW, Michelsen CB, Rosenwasser MP. Unipolar or bipolar hemiarthroplasty for femoral neck fractures in the elderly? *Clin Orthop Relat Res*. 2003;414:259-65.
  23. Figved W, Opland V, Frihagen F, Jervidal T, Madsen JE, Nordsetten L. Cemented versus uncemented hemiarthroplasty for displaced femoral neck fractures. *Clin Orthop Relat Res*. 2009;467(9):2426-35.
  24. Livesley PJ, Srivastava VM, Needoff M, Prince HG, Moulton AM. Use of a hydroxyapatite-coated hemiarthroplasty in the management of subcapital fracture of the femur. *Injury*. 1993;24:236-40.
  25. Parker MI, Pryor G, Gurusamy K. Cemented versus uncemented hemiarthroplasty for intracapsular hip fractures: A randomized controlled trial in 400 patients. *Br J Bone Joint Surg*. 2010;92-B:116-22.
  26. Branfoot T, Faraj AA, Porter P. Cemented versus uncemented Thompson's prosthesis: a randomised prospective functional outcome study. *Injury*. 2000;31:280-1.
  27. Phillips TW. The Bateman bipolar femoral head replacement: a fluoroscopic study of movement over a four-year period. *Br J Bone Joint Surg*. 1987;69-B:761-4.
  28. Verberne GH. A femoral head prosthesis with a built-in joint: a radiological study of the movements of two components. *Br J Bone Joint Surg*. 1983;65-B:544-7.
  29. Bauer S, Isenegger P, Gautschi OP, Ho KM, Yates PJ and Zellweger R. Cemented Thompson versus cemented bipolar prostheses for femoral neck fractures. *J Orthopaed Surg*. 2010;18(2):166-71.
  30. Calder SJ, Anderson GH, Jagger C, Harper WM and Gregg PJ. Unipolar or bipolar prosthesis for displaced intracapsular hip fracture in octogenarians. A randomized prospective study. *Br J Bone Joint Surg*. 1996;78-B:391-4.
  31. van den Bekerom MPJ, Hilverdink EF, Sierevelt IN, Reuling EMBP, Schnater JM, Bonke H, et al. A comparison of hemiarthroplasty with total hip replacement for displaced intracapsular fracture of the femoral neck a randomized controlled multicentric trial in patients aged 70 years and over. *Br Bone Joint Surg*. 2010;92-B:1422-8.
  32. Lu-Yao GL, Keller RB, Littenberg B, Wennberg JE. Outcomes after displaced fractures of the femoral neck. A meta-analysis of one hundred and six published reports. *Am J Bone Joint Surg*. 1994;76(1):15-25.
  33. Blewitt N, Mortimore S. Outcome of dislocation after hemiarthroplasty for fractured neck of the femur. *Injury*. 1992;23:320-2.
  34. Pajarinen J, Savolainen V, Tulikoura I, Lindahl J, Hirvensalo E. Factors predisposing to dislocation of the Thompson hemiarthroplasty: 22 dislocations in 338 patients. *Acta Orthop Scand*. 2003;74:45-8.
  35. Faraj AA, Branfoot T. Cemented versus uncemented Thompson's prostheses: a functional outcome study. *Injury*. 1999;30(10):671-5.

36. LaPorte DM, Pont MA, Hungerford DS: Proximally porouscoated ingrowth prostheses: limits of use. *Orthopedics.* 1999;22(12):1154-60.
37. Clark DI, Ahmed AB, Baxendale BR, Moran CG: Cardiac output during hemiarthroplasty of the hip. A prospective, controlled trial of cemented and uncemented prostheses. *Br J Bone Joint Surgery.* 2001;83(3):414-8.
38. Azegami S, Gurusamy KS, Parker MJ. Cemented versus uncemented hemiarthroplasty for hip fractures: a systematic review of randomised controlled trials. *Hip Int.* 2011;21(5):509-17.
39. Troelsen A, Malchau E, Sillesen N, Malchau H. A review of current fixation use and registry outcomes in total hip arthroplasty: the uncemented paradox. *Clin Orthop Relat Res.* 2013 Jul;471(7):2052-9.
40. Gromov K, Pedersen AB, Overgaard S, Gebuhr P, Malchau H, Troelsen A. Do rerevision rates differ after first-time revision of primary THA with a cemented and cementless femoral component? *Clin Orthop Relat Res.* 2015;473(11):3391-8.
41. Rogmark C, Leonardsson O, Garellick G, Kärrholm J. Monoblock hemiarthroplasties for femoral neck fractures-A part of orthopaedic history? Analysis of national registration of hemiarthroplasties 2005-2009. *Injury.* 2012 Jun;43(6):946-9.
42. Ahn J, Man X, Park SD, Sodl JF, Esterhai JL. Systematic Review of Cemented and Uncemented Hemiarthroplasty Outcomes for Femoral Neck Fractures. *Clin Orthop Relat Res.* 2008;466:2513-8.
43. Abdulkarim A, Ellanti P, Motterlini N, Fahey T, O'Byrne JM. Cemented versus uncemented fixation in total hip replacement: a systematic review and meta-analysis of randomized controlled trials. *Orthopedic reviews.* 2013 Feb 22;5(1):e8.
44. Taylor F, Wright M, Zhu M. Hemiarthroplasty of the Hip with and without Cement: A Randomized Clinical Trial. *Am J Bone Joint Surg.* 2012;94(7):577-83 .
45. Jämsen, E, Eskelinen A, Peltola M, Mäkelä, K. High early failure rate after cementless hip replacement in the octogenarian. *Clin Orthop Relat Res.* 2014;472(9):2779-89.

**Cite this article as:** Kumar S, Verma V, Kumar S. Cemented monoblock hemiarthroplasty: a dependable option in femoral neck fracture in elderly. *Int J Res Med Sci* 2019;7:1178-83.