

Case Report

Neurofibroma of lumbosacral region: a case report

Elfiah*, Syaifullah Asmiragani

Department of Orthopaedic and Traumatology, Brawijaya University, Saiful Anwar General Hospital Malang, East Java, Indonesia

Received: 06 February 2019

Revised: 21 March 2019

Accepted: 28 March 2019

***Correspondence:**

Dr. Elfiah,

E-mail: elfiahmarekar@yahoo.com

Copyright: © the author(s), publisher and licensee Medip Academy. This is an open-access article distributed under the terms of the Creative Commons Attribution Non-Commercial License, which permits unrestricted non-commercial use, distribution, and reproduction in any medium, provided the original work is properly cited.

ABSTRACT

Neurofibromas are benign tumors of the peripheral nerve sheath. Spinal neurofibroma often asymptomatic. Symptoms may present include sensory changes. Neurofibroma mostly encountered cervical cord, difficult to distinguish from schwannomas. This slow growing tumor remodel the bone resulting pedicle thinning and posterior vertebral body scalloping. MRI shows hyperintense rim. Although this highly suggestive neurofibroma, occasionally also seen in schwannoma and malignant PNST. Treatment choice for symptomatic lesions is surgery. We are reporting a case of neurofibroma in the 5th lumbar and 1st sacral region.

Keywords: Decompression, Lumbosacral, Neurofibroma, Posterior stabilisation

INTRODUCTION

Neurofibromas are nerve sheath tumors, or tumors of the layer of insulation that surrounds nerve fibers. Neurofibromas arise from Schwann cells, which produce the insulating sheath for all nerves outside the brain and spinal cord. These tumors do not arise in the spinal cord, which is part of the central nervous system. These tumors are instead on the nerves that leave the spinal cord to branch out to the rest of body. Nerve roots leave the spine through small openings in the spinal canal called the foramen. The neurofibroma that grow along nerve roots are therefore often dumbbell shaped. That is, one part of the mass is inside the spinal canal and one part is outside. They are connected by a narrow section that passes through the foramen. Neurofibroma of the spine can occur spontaneously but are found at a high frequency in patients with neurofibromatosis type I (NF-I).¹⁻⁸ This spinal nerve sheath tumors constitute one-fourth of all spinal tumors and more than one-third of intradural

extramedullary tumors of the spinal cord. They commonly occur at an age between 25-50 years of age, with no clear discrepancy between men and women. This tumour are typically extradural lesions that may extend proximally to an intradural location. Neurofibroma can be located inside the Dural sac (intradural), entirely outside the Dural sac, according to the location of the tumor origin along the spinal nerve root. In the literature, 70-80% of spinal neurofibromas are intradural, and those extending through the Dural aperture as a dumbbell mass with both intradural and extradural components account for another 15%.^{1,2}

Symptoms result when a growing tumor encroaches on the surrounding structures. Common symptoms that occur when a neurofibroma compresses the spinal cord or nerve roots include change in sensation such as pain, numbness, and tingling; changes in movement such as clumsiness in hand and trouble walking; changes in bowel or bladder such as a sense of urgency when

urinating and bowel or bladder incontinence. These tumors can also create an abnormal curvature called scoliosis that result from muscular imbalance or erodes bones of the spine.^{1,3}

Neurofibroma are grade I lesions, which represent a proliferation of all components of a nerve, including Schwann cells, collagen, and perineurial cells, resulting in a fusiform expansion. Neurofibroma often have myxoid matrix in which mast cell are common. The appearance of small, haphazardly arrayed aggregates of collagen has been likened to “shredded carrots”. Radiological imaging, the best diagnostic clue is bulky, multilevel spinal nerve root tumors in patients with stigmata of NF-I. On CT, the mass shows isodense image to the spinal cord. Neural foramen enlargement can accompany the mass. On T2WI MRI, neurofibroma can be of isointense or hyperintense signal intensity.^{5,6} Sometimes, central high signal and peripheral low signal may be seen (target sign). On T1WI MRI, the mass signal is similar to the spinal cord. With contrast, the mass demonstrates moderate or bright enhancement.^{2,7} Neurofibroma most often occur in people who have a genetic condition called neurofibromatosis. Two forms of this condition, NF 1 and NF2, cause neurofibromas throughout the body. To identify these problems, authors can use MRI (magnetic resonance imaging) and CT (computed tomography) scans.

On the scans, neurofibromas resemble schwannomas, another type of nerve tumor.^{7,8} These tumor types may be impossible to distinguish on imaging and often require tissue biopsy for pathologic evaluation in the laboratory. Neurofibromas are the more difficult type of tumor to remove because they are more intimately involved with nerve fibers. However, with meticulous surgical technique, most can be removed safely.^{9,10} No treatment is needed in spinal neurofibroma, but in some certain condition mostly clinical symptoms that manifest, certain treatment is needed. The treatment choice depends on the size, location, and symptoms of the tumor. Small tumors producing no pressure on nearby structures in patient with no symptoms can often be observed over time with yearly MRI. For larger or symptomatic tumors, or tumors showing growth over time, surgical removal is usually recommended. In most patient, complete removal of these tumors can be safely achieved using surgical microscope.¹⁻⁴

Authors reporting a case of neurofibroma in the 5th lumbar and 1st sacral region accompanied by pain, tingling, seizure, and progressively worse which was performed L5 laminectomy, L4 and S1 left hemilaminectomy, and pedicel screw insertion in the L4, L5, and S1.

CASE REPORT

A 44-years-old female admitted due to pain, tingling, seizure in the left foot for 6 months and getting worse.

Bowel bladder is good, tingling worsens when she strained. No history of trauma recently.

Thoracolumbar x-ray shows straight lumbosacral, chronic indentation, pedicle thinning. MRI shows hyperintense of L5 and S1 and extend to outside lateral foramen. Shape is dumbly-bell, cystic, multilocular, invading wall and septum, intracystic component is hypo intensely in T1W1, hyperintense in T2W1, recess in left lateral and neural foramen at L4-L5, L5-S1.

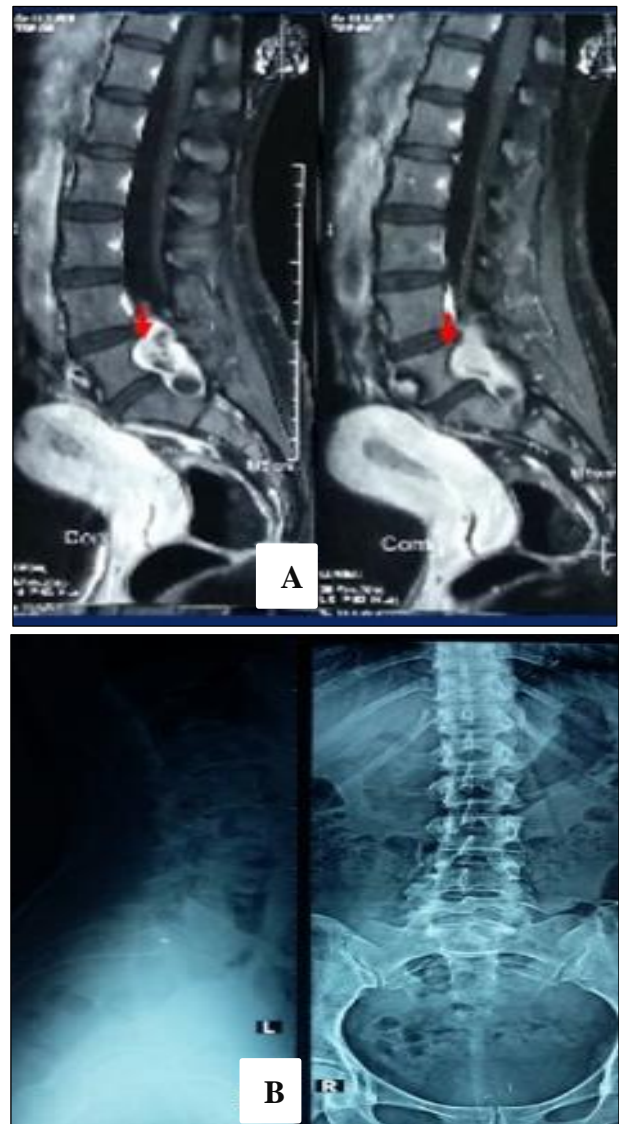

Figure 1 A): Lumbo-sacral MRI with contrast. B): Lumbo-sacral plain X-ray AP-lateral view.

Authors perform tumor extraction performed by L5 laminectomy, L4 and S1 left hemilaminectomy. Extradural mass in L4-S1, enter extra canal. The mass is difficult to define from nerve root, so it performed for aminectomy (Figure 2).

Family was informed during operation to cut the root of L5 and posterior fusion. It performed pedicel screw

insertion in the L4, L5, and S1. In L5-S1 pedicle screw was inserted only in left side because cortex is thin (Figure 3).

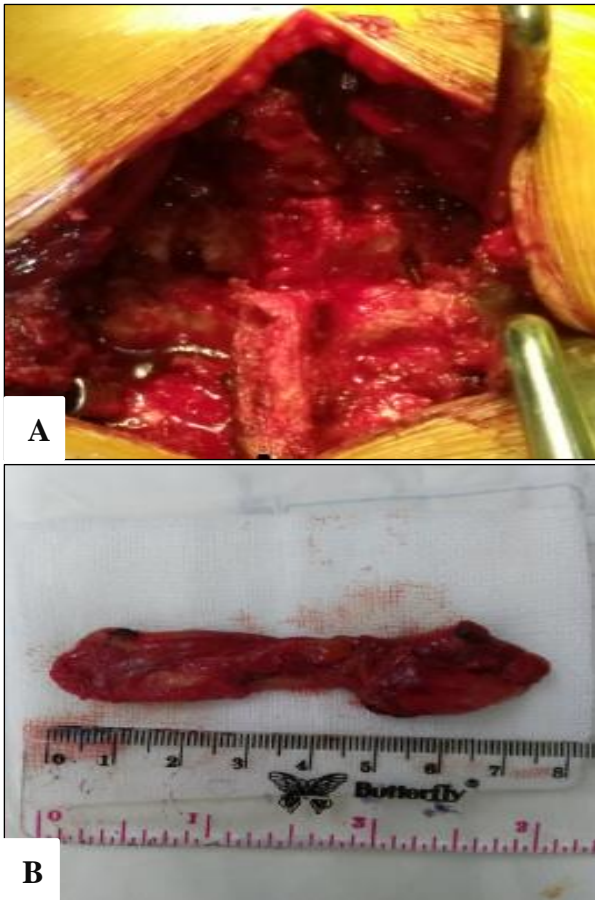


Figure 2 (A): During operation procedure. **(B):** After removal we found 8 x 1.5 x 1 cm mass.

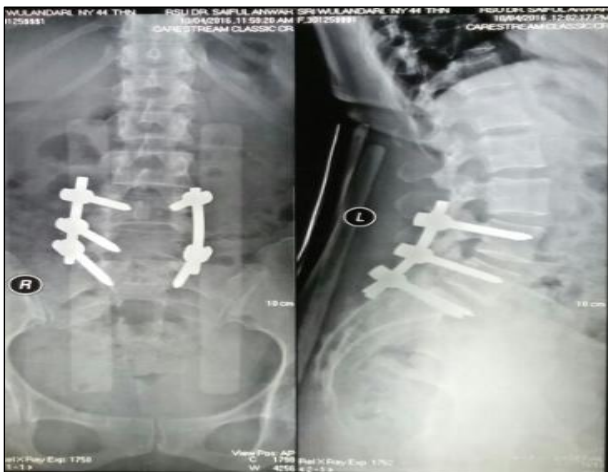

Figure 3: Post-operative lumbar radiograph showed spinal instrumentation.

One day after surgery patient recovered well with inability to extent great toe, numbness of 1st web and no complain of bowel bladder function. Three weeks after,

complain is remaining the same but patient is able to walk. Biopsy shows manifestation match to clinical appearance of hollow shaped mass, yellowish liquid, unilocular part and pathological appearance of mesenchymal cells spindle shaped, oval-spindle center, no malignancy sign.

DISCUSSION

Neurologic compromise due to compression of spinal cord manifest as radiculopathy. Depending on the level, several clinical symptoms may emerge. Cortex depletion and chronic indentation in plain photo indicate slow growing tumor. MRI shows hyperintense mass outside durometer compress spinal cord. Clinical appearance, tumor is in the root of L5, because neurofibroma is not well margined, authors cut the L5 root resulting in inability to extend great toe and 1st web numbness. Biopsy shows neurofibroma.

Neurofibromas usually found in the cervical region but here, found in lumbosacral. In other case, common tumor found in lumbosacral is schwannoma. Manifestation-slow growing tumor, widening of the neural exit foramen, and pedicle thinning-indicate neurofibroma, produce fusiform enlargement of involving nerve with presence of nerve fibers within tumor stroma, making impossible to dissect from nerve root. This arrangement makes surgical resection more difficult and creates higher risk of neurologic injury.

CONCLUSION

Even though neurofibroma is mostly found in cervical region, it also can develop in lumbosacral region. Decompression and posterior stabilization were effective to correct neurological deficit.

Funding: No funding sources

Conflict of interest: None declared

Ethical approval: Not required

REFERENCES

1. Ferner RE. Neurofibromatosis 1. *European J Human Genet.* 2007;15(2):131.
2. Kim D, Chang U, Kim S, Bilsky M, eds. *Tumors of the Spine.* Philadelphia: Saunders Elsevier.2008: 130-131.
3. Solomon L, Warwick D, Nayagam S, eds. *Apley's system of orthopaedics and fractures.*10th ed. New York:Taylor & Francis group. 2010:78-9.
4. Sarica FB, Tufan K, Cekinmez M, Erdoğan B, Şen O. Dumbbell-shaped neurofibroma of the upper cervical spine: A Case Report. *J Nervous Sys Surg.* 2008;1:190-4.
5. Levy WJ, Latchaw J, Hahn JF, Sawhny B, Bay J, Dohn DF. Spinal neurofibromas: a report of 66 cases and a comparison with meningiomas. *Neurosurg.* 1986;18(3):331-4.

6. Abul-Kasim K, Thurnher MM, McKeever P, Sundgren PC. Intradural spinal tumors: current classification and MRI features. *Neuroradiol.* 2008;50(4):301-14.
7. Calandruccio AH, Gear BJ, Mauck MB, Sawyer RJ, Toy PC, Weinlein CJ. *Orthopaedic clinics of North America.* 2009;47(4).
8. Patt JC. Oncology of the spine: neurofibromatosis and malignant peripheral nerve sheath tumor of the thoracic spine tomasi SO. *Adult spinal deformity: Sagittal imbalance. Int J Orthopaedics.* 2014;1(3):64-72.
9. Wein S. Spinal neurofibroma. *Radioped.* 2010.
10. Moghaddasi M, Aghaii M, Mamarabadi M. Perianal pain as a presentation of lumbosacral neurofibroma: a case report. *J Neurol Surg Reports.* 2014;75(02):e191-3.

Cite this article as: Elfiah, Asmiragani S. Neurofibroma of lumbosacral region: a case report. *Int J Res Med Sci* 2019;7:1948-51.