

## Original Research Article

# Role of ACR-TIRADS in risk stratification of thyroid nodules

Jayashree Mohanty, Sanket\*, Pooja Mishra

Department of Radiodiagnosis, SCBMCH, Cuttack, Odisha, India

**Received:** 20 February 2019

**Accepted:** 11 March 2019

**\*Correspondence:**

Dr. Sanket,

E-mail: [dr.sanketkulkarni@gmail.com](mailto:dr.sanketkulkarni@gmail.com)

**Copyright:** © the author(s), publisher and licensee Medip Academy. This is an open-access article distributed under the terms of the Creative Commons Attribution Non-Commercial License, which permits unrestricted non-commercial use, distribution, and reproduction in any medium, provided the original work is properly cited.

### ABSTRACT

**Background:** This study was performed to prospectively investigate the diagnostic reliability of the daily use of ACR-TIRADS classification system, in differentiating between a benign and a malignant lesion.

**Methods:** In this prospective observational study, 50 patients with thyroid nodules underwent ultrasound examination and fine needle aspiration. The ultrasound studies were evaluated according to the ACR-TIRADS greyscale characteristics of composition, echogenicity, margins, shape, and echogenic foci. Each feature in a particular USG characteristic was scored and ACR-TIRADS categorization done from 1 to 5. This was compared to FNAC/histopathology findings and risk of malignancy was calculated for each feature and ACR-TIRADS category.

**Results:** Of the 50 nodules included in the study, 38 were found to be benign and 12 were found to be malignant. Risk of malignancy for all ultrasound features showed an increasing trend with higher scored feature. Risk of malignancy for various features were as follows: Composition-cystic (0%), spongiform (0%), solid-cystic (0%) and solid (36%); echogenicity-anechoic(0%), hyperechoic (4%), isoechoic (11%), hypoechoic (47%) and markedly hypoechoic (100%); shape-wider-than-tall (21%) and taller-than-wide (66%); margins-smooth (18%), illdefined (0%), lobulated/irregular (38%) and extrathyroid extension (100%); echogenic foci-none (13%), large comet-tail artefacts (0%), macrocalcification (42%), rim calcification (50%) and punctate echogenic foci (50%). Amongst ACR-TIRADS(TR) categories TR1, TR2 and TR3 had 0% risk while TR4 had 30% and TR5 had 56% risk of malignancy with p value of 0.001.

**Conclusions:** ACR-TIRADS is a high specific, accurate classification system for categorizing the thyroid nodules based on ultrasound features, for assessing the risk of malignancy.

**Keywords:** ACR-TIRADS, TIRADS, Thyroid nodule imaging

### INTRODUCTION

A thyroid nodule is defined as a region of parenchyma sonographically distinct from the remainder of the thyroid.<sup>1</sup> Ultrasound is the most widely used imaging modality to evaluate thyroid nodules for risk of malignancy.<sup>2,3</sup> On ultrasound upto 60% of adult Indian population was found to have thyroid nodules.<sup>4</sup>

However, the incidence of thyroid malignancy is low.<sup>4</sup> Ultrasound is frequently misperceived as unhelpful for identifying features that distinguish benign from malignant nodules. There are, however, well established

ultrasound findings that differentiate benign and malignant thyroid nodules and there are several classification systems which categorize thyroid nodules according to the risk of cancer.<sup>5</sup> Thyroid lesions detected during ultrasound scanning show highly diverse pattern which comes in way of common reporting system and understanding and therefore several studies and classification systems were formulated in different parts of world which categorize thyroid nodules according to the risk of cancer. This leads to confusions in understanding among radiologists and also between radiologists and clinicians. Several studies and classification systems have been proposed in the past like

TIRADS (2009), modified TIRADS (2011), British U-system (2014), ATA guidelines (2015).<sup>5</sup> The classification system by American College of Radiology, called ACR-TIRADS has been widely popularised since it came out in 2017.<sup>6,7</sup>

This system uses an easy to apply pattern-oriented system for risk stratification, to identify most clinically significant malignancies while reducing the number of biopsies performed on benign nodules.<sup>8</sup> To do so the system need to be able to accurately classify thyroid nodules and stratify their risk for malignancy.

This study was performed to prospectively investigate the diagnostic reliability of the daily use of ACR-TIRADS classification system, in differentiating between a benign and a malignant lesion.

**METHODS**

The study is a hospital based prospective observational study done in the department of Radio-diagnosis, SCB Medical college between 2017 and 2018 on patients referred to the department for ultrasound of thyroid. Patients having either clinically palpable/sonologically detected thyroid nodules were included in the study. In keeping with the definition of thyroid nodule, patients with diffuse thyroid diseases, with non thyroid lesions were excluded. Patients who did not give consent to FNAC and those with bleeding diathesis were also excluded.

Ultrasound of the nodules was done using GE (Logiq F8 ultrasound machine with a 6-12MHz linear-array transducer) and Samsung (HS70A ultrasound machine with 4-18MHz linear-array transducer) in keeping with ACR-TIRADS recommendations as briefly described below. Each nodule further underwent FNAC under ultrasound guidance to establish pathological diagnosis and nodules with FNAC findings of ‘follicular neoplasm’ who underwent surgery were followed up for post-operative histopathology, as FNAC could not differentiate between benign and malignant follicular nodule.<sup>9,10</sup>

**Image interpretation**

All the nodules were assessed using ultrasound for the five feature categories in the ACR TI-RADS lexicon: composition, echogenicity, shape, margin, and echogenic foci. A score was assigned for feature (s) noted in each category and scored accordingly. Total score was added and used to classify nodules from TR1 through TR5. This system as described in ACR TI-RADS lexicon is summarised in Table 1.

Additional details that were collected included patient particulars and demographics, nodule location and size. Size measurement was done in the maximum dimension

of the nodule and also included the surround halo when present.

**Table 1: ACR-TIRADS scoring system.**

Characteristic	Score
<b>Composition (choose 1)</b>	
Cystic	0
Spongiform	0
Mixed solid-cystic	1
Solid	2
<b>Echogenicity (choose 1)</b>	
Anechoic	0
Hyperechoic	1
Isoechoic	1
Hypoechoic	2
Markedly hypoechoic	3
<b>Shape (choose 1)</b>	
Wider than Tall	0
Taller than Wide	3
<b>Margin (choose 1)</b>	
Smooth	0
Illdefined	0
Lobulated/Irregular	2
Extrathyroid extension	3
<b>Echogenic foci (choose all that apply)</b>	
None	0
Large Comet Tail artefacts	0
Macrocalcification	1
Rim calcification	2
Punctate Echogenic Foci	3
<b>ACR TIRADS category</b>	<b>Total score</b>
ACR-TIRADS 1(TR1)	0
ACR-TIRADS 2(TR2)	2
ACR-TIRADS 3(TR3)	3
ACR-TIRADS 4(TR4)	4-6
ACR-TIRADS 5(TR5)	7+

**Analysis of data**

Microsoft Word was used to generate tables and data was entered in Excel spreadsheet to produce master chart. Ultrasound findings were compared to FNAC/histopathology as gold standard and statistical analysis done using IBM-Statistical Package for Social Sciences. Positive predictive value/risk and p-value were calculated for individual suspicious malignant features and also for individual TIRADS categories. The P values were measured using Fischer exact test since individual frequency was less than 5 in many observations. P-value less than 0.05 was taken as statistically significant

**RESULTS**

The median patient ages in the benign and malignant groups were 46 years and 44.5 years respectively. A female predilection was found in our study, with 40

(80%) females and 10 (20 %) males with a male to female ratio of 1:4. The right lobe of thyroid was the most common location for both benign (n=25) and malignant (n=7) thyroid nodules. On the whole, the malignant thyroid nodules (average 2.4cm, range=0.9 to 5.6cm) were found to be slightly smaller in size than the benign nodules (average 2.6cm, range=0.7 to 5.4cm).

Pathological results showed that out of 50 nodules 12 were malignant and 38 were benign. Malignancy of only 4 of the nodules could not be determined by FNAC

(finding=Follicular Neoplasm) and were established on post operative histopathology.

The most common benign nodule was colloid nodule (n=34) and most common malignant nodule was papillary carcinoma (n=7). Other pathologic findings included follicular adenoma (n=2), inflammatory pseudonodule (n=1) granulomatous thyroiditis (n=1), Medullary thyroid carcinoma (n = 2), follicular carcinoma (n = 1), follicular variant of papillary carcinoma (n=1) and anaplastic carcinoma (n=1).

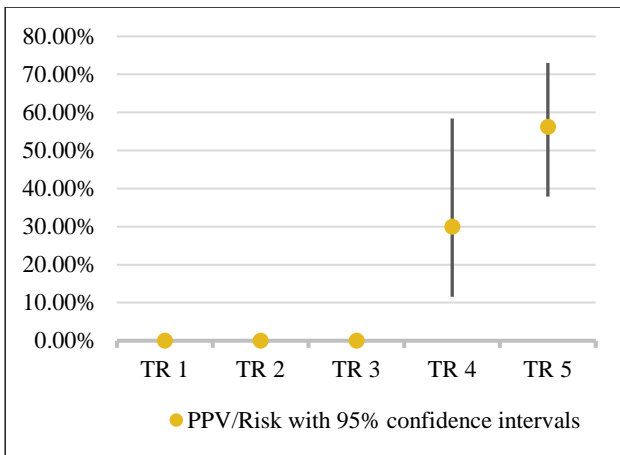
**Table 2: Ultrasound findings with risk of malignancy.**

Characteristic	Benign	Malignant	Total	Risk of malignancy
<b>Composition</b>				
Cystic	1	0	1	0%
Spongiform	8	0	8	0%
Mixed solid-cystic	8	0	8	0%
Solid	21	12	33	36.6%
<b>Echogenicity</b>				
Anechoic	1	0	1	0%
Hyperechoic	8	1	9	4.7%
Isoechoic	20	1	21	11.1%
Hypoechoic	9	8	17	47%
Markedly Hypoechoic	0	2	2	100%
<b>Shape</b>				
Wider than Tall	37	10	47	21.2%
Taller than Wide	1	2	3	66.6%
<b>Margin</b>				
Smooth	26	6	32	18.7%
Illdefined	4	0	4	0%
Lobulated/Irregular	8	5	13	38.4%
Extrathyroid extension	0	1	1	100%
<b>Echogenic foci</b>				
None	26	4	30	13.3%
Comet Tail	3	0	3	0%
Macrocalcification	4	3	7	42.8%
Rim Calcification	1	1	2	50%
Punctate Echogenic Foci	4	4	8	50%
<b>ACR-TIRADS Category</b>				
TR 1	8	0	8	0%
TR 2	5	0	5	0%
TR 3	11	0	11	0%
TR 4	7	3	10	30%
TR 5	8	0	8	56 %

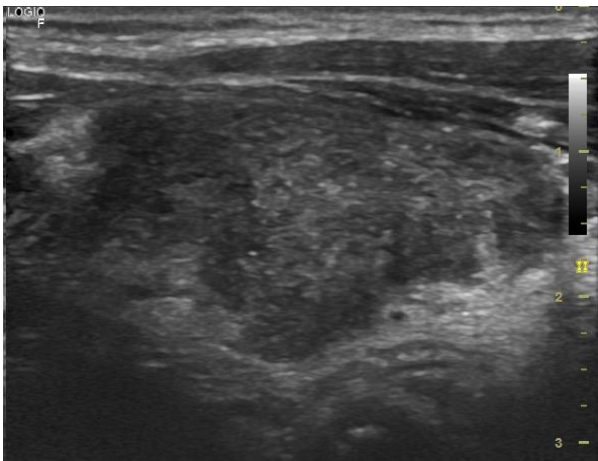
Table 2 enumerates the grey scale characteristics as described in ACR-TIRADS lexicon with associated risk estimated for each feature. Individual ACR-TIRADS category with its estimated risk (including 95% confidence interval) is depicted in Figure 1. For risk of

malignancy as estimated ACR-TIRADS category, p-value was found to be 0.01 (Fischer exact test).

Figure 2 shows a representative case from our study which was categorised as ACR-TIRADS 5 and correlated with FNAC report proving it to be malignant.



**Figure 1: Risk of malignancy (y-axis) with ACR-TIRADS (TR) categories (x-axis).**



**Figure 2: A solid, wider-than-tall, irregular marginated, hypoechoic nodule with punctate echogenic foci. The ACR-TIRADS score was 9 and categorized as TR5, FNA showing it to be a papillary carcinoma.**

**DISCUSSION**

Our study showed an increasing risk of malignancy with higher scored characteristic as described in ACR-TIRADS lexicon. Solid nodules were the most common composition comprising 66% of all nodules. Mixed solid-cystic and spongiform nodules were each 16% and cystic nodules were 2% in numbers. All the malignant nodules were found to be solid. The solid nodules had a 36% risk of malignancy. None of the other nodules were found to be malignant and entailed a 0% risk of malignancy. Middleton et al, reported the risk of malignancy with spongiform, mixed and solid nodules to be 0.3%, 4% and 12% respectively.<sup>11</sup>

Hyperechoic nodules were found to be the most common type (42%), followed by hypoechoic (34%) and isoechoic nodules (18%). Markedly hypoechoic nodules comprised of 4% and anechoic nodules were only 2%. Risk of

malignancy was highest with markedly hypoechoic nodules (100% risk), followed by hypoechoic nodules (47% risk). Isoechoic nodules had a risk of 11%, and Hyperechoic nodules had risk of 4%. Anechoic nodule was not found to be malignant (0% risk). Middleton et al, reported the risk of malignancy with hyperechoic, isoechoic, hypoechoic and very hypoechoic nodules to be 6.8%, 8.7%, 11.8% and 32% respectively.<sup>11</sup>

Most of the nodules in our study were wider than tall (94%). Only 6% were taller than wide. Taller than wide nodules had a malignancy risk of 66.6% whereas the wider than tall nodules had a malignancy risk of 21%.

Most of the nodules in our study had a smooth margin (64%). 26% showed irregular/lobulated margin. 8% of the nodules had an illdefined margin and only 2% had extra thyroid extension. Extra thyroid extension entailed a 100% risk of malignancy in our study. Risk with lobulated/irregular margin was 38% and with smooth margin had 18% risk. None of the illdefined nodules were malignant indicating a 0% risk of malignancy. Middleton et al, reported the risk of malignancy with smooth and irregular nodules to be 12.9% and 44.7% respectively.<sup>11</sup>

Most of the nodules in our study did not have any echogenic foci (60%). 16% of the nodules had punctate echogenic foci, 14% had macro calcification, 6% had large comet tail artefacts and 4% had rim calcification. Both punctate echogenic foci and rim calcification carried a 50% risk of malignancy. Nodules with rim calcification had 42% risk and those without any echogenic foci had 13% risk. None of the nodules with large comet tail artefacts turned out to be malignant indicating 0% risk. Middleton et al, reported the risk of malignancy of nodules with no echogenic foci, macrocalcifications, peripheral calcifications, punctate echogenic foci to be 9.7%, 11.8%, 20.2% and 35% respectively.<sup>11</sup>

Out of all the suspicious features of malignancy highest risk was found for Marked hypoechoic and extrathyroid extension with 100% risk. Cystic, spongiform and mixed solid-cystic composition, anechoic echogenicity, illdefined margins and long comet tail artefacts had 100% PPV for benignity with 0% malignancy risk.

On categorising nodules into ACR-TIRADS categories from TR1 to TR5, number of nodules in each category was found to be 8,5,11,10 and 16 respectively. On correlating with the FNAC/Histopathology results our study showed an increase in risk of malignancy with increase in ACR-TIRADS categories with 0% risk in TR1, TR2 and TR3, 30% risk in TR4 and 56% risk in TR5. A statistically significant correlation was noted with p-value 0.001.

White Paper of the ACR TI-RADS Committee by Tessler et al, has categorized the risk as <2% for TIRADS 1 and 2, 2-5% for TIRADS 3, 5-20% for TIRADS 4 and >20%

for TIRADS 5.<sup>6,7</sup> Middleton et al, reported the risk as 0.3%, 1.5%, 4.8%, 9.1% and 35% for TIRADS categories 1, 2, 3, 4 and 5 respectively.<sup>11</sup>

Limitations of the study included that of a small sample size (N=50), selection bias in including only patients that presented to the department after prior clinical workup by referring physician and lack of follow-up.

## CONCLUSION

In conclusion, ACR-TIRADS was found to be a highly specific and accurate classification system for categorizing the thyroid nodules based on ultrasound features, for assessing the risk of malignancy.

*Funding: No funding sources*

*Conflict of interest: None declared*

*Ethical approval: The study was approved by the Institutional Ethics Committee*

## REFERENCES

1. Cooper DS, Doherty GM, Haugen BR, Kloos RT, Lee SL, Mandel SJ, et al. Revised American Thyroid Association management guidelines for patients with thyroid nodules and differentiated thyroid cancer: the American Thyroid Association (ATA) guidelines taskforce on thyroid nodules and differentiated thyroid cancer. *Thyroid*. 2009 Nov 1;19(11):1167-214.
2. Nachiappan AC, Metwalli ZA, Hailey BS, Patel RA, Ostrowski ML, Wynne DM. The thyroid: review of imaging features and biopsy techniques with radiologic-pathologic correlation. *Radiographics*. 2014 Mar;34(2):276-93.
3. Loevner LA, Kaplan SL, Cunnane ME, Moonis G. Cross-sectional imaging of the thyroid gland. *Neuroimaging Clin North America*. 2008 Aug 1;18(3):445-61.
4. Unnikrishnan A, Menon U. Thyroid disorders in India: An epidemiological perspective. *Indian J Endocrinol Metab*. 2011 Jul;15(Suppl2):S78.
5. Mahajan A, Vaidya T, Vaish R, Sable N. The journey of ultrasound-based thyroid nodule risk stratification scoring systems: Do all roads lead to Thyroid Imaging, Reporting and Data System (TIRADS)? *J Head Neck Physicians Surg*. 2017;5(2):57.
6. Tessler FN, Middleton WD, Grant EG, Hoang JK, Berland LL, Teefey SA, et al. ACR Thyroid Imaging, Reporting and Data System (TI-RADS): White Paper of the ACR TI-RADS Committee. *J Am Coll Radiol*. 2017 May 1;14(5):587-95.
7. Grant EG, Tessler FN, Hoang JK, Langer JE, Beland MD, Berland LL, et al. Thyroid ultrasound reporting lexicon: White paper of the ACR thyroid imaging, reporting and data system (TIRADS) committee. *J Am Coll Radiol*. 2015 Dec 1;12(12):1272-9.
8. Grani G, Lamartina L, Ascoli V, Bosco D, Biffoni M, Giacomelli L, et al. Reducing the number of unnecessary thyroid biopsies while improving diagnostic accuracy: Toward the "Right" TIRADS. *J Clin Endocrinol Metab*. 2018 Oct 8;104(1):95-102.
9. Kapur U, Wojcik EM. Follicular Neoplasm of the Thyroid-Vanishing cytologic diagnosis? *Diagn Cytopathol*. 2007 Aug;35(8):525-8.
10. Sobrinho-Simões M, Eloy C, Magalhães J, Lobo C, Amaro T. Follicular thyroid carcinoma. *Mod Pathol*. 2011 Apr 1;24(S2):S10.
11. Middleton WD, Teefey SA, Reading CC, Langer JE, Beland MD, Szabunio MM, et al. Multiinstitutional analysis of thyroid nodule risk stratification using the American College of radiology thyroid imaging reporting and data system. *Am J Roentgenol*. 2017 Jun;208(6):1331-41.

**Cite this article as:** Mohanty J, Sanket, Mishra P. Role of ACR-TIRADS in risk stratification of thyroid nodules. *Int J Res Med Sci* 2019;7:1039-43.