

Case Report

Diagnostic surprises in early pregnancy: two case reports

Madhuri N.*

Department of Obstetrics and Gynaecology, J.S.S. Medical College, Mysuru, Karnataka, India

Received: 24 January 2016

Accepted: 15 February 2016

***Correspondence:**

Dr. Madhuri N.,

E-mail: drmadhuri.n@gmail.com

Copyright: © the author(s), publisher and licensee Medip Academy. This is an open-access article distributed under the terms of the Creative Commons Attribution Non-Commercial License, which permits unrestricted non-commercial use, distribution, and reproduction in any medium, provided the original work is properly cited.

ABSTRACT

Early pregnancy poses diagnostic challenges to the clinician in developing countries because of lack of early antenatal check-up and lack of ultrasound use in first trimester. Extrauterine pregnancies are rare and mostly tubal. Non tubal ectopic pregnancies are still rarer and most often surprise the surgeons intraoperatively. Here two such cases are reported, of women presenting with acute abdomen, no significant period of amenorrhea and no specific risk factors for ectopic pregnancy. First is an ovarian pregnancy managed conservatively by wedge resection. Second is a case of cornual pregnancy managed by cornual resection and uterine repair.

Keywords: Ovarian pregnancy, Cornual pregnancy, Non tubal ectopic pregnancy

INTRODUCTION

Early pregnancy poses myriad possibilities to the practicing clinician. Diagnosis is a challenge in the absence of a significant period of amenorrhea. Extrauterine pregnancy is rare and is usually located in the fallopian tube. Rarely it occurs in the ovary (1-3%), cornu (2-4%), cervix or abdomen.^{1,6} Here are two such case reports of women presenting with acute abdomen, no significant period of amenorrhea and no specific risk factors for ectopic pregnancy.

CASE REPORT

Case 1

A 31 year old G2P1L1 presented with pain abdomen since 12 hours. Her previous cycles were regular and LMP was 25 days ago with moderate flow for 5 days. On examination pulse was 110 bpm and BP 90/60 mmhg. On abdominal examination, tenderness was present on the right side and bowel sounds were present. Per vaginal examination revealed right forniceal tenderness and normal uterus and no adnexal mass. UPT was positive and ultrasound showed a heterogenous mass of 8×6 cms

in right adnexa with moderate amount of free fluid noted in the abdomen suggestive of right ruptured ectopic pregnancy. Hemoglobin was 8.1 gm% and rest of the laboratory investigations was normal. Patient was taken for emergency laparotomy with cross matched blood. Intraoperatively uterus and B/I tubes were normal. Hemoperitoneum of about 250 ml and clots of about 100 grams were noted. Right ovary showed a mass of about 4×5 cms, bleeding actively and appeared either like a ruptured cyst or ruptured ovarian pregnancy. A wedge resection of the ovary was done and contents were sent for histopathology. Hemostasis was achieved and patient had an uneventful post operative period with one pint blood transfusion. HPE report confirmed the diagnosis of right ovarian pregnancy.

Case 2

A pale 22 yr old primigravida with a similar profile as case 1 was referred from a private clinic with an ultrasound report of a gestational sac measuring 6 weeks in the right iliac fossa and free fluid in the abdomen. Hemoglobin was 6.9 gm% and blood group B positive. A diagnosis of right sided ruptured ectopic pregnancy was made and patient was taken for emergency laparotomy. A

right cornual pregnancy of 5×3 cms which had ruptured on the posterior surface was noted. A cornual resection and uterine repair was undertaken. Hemostasis was achieved. 3 pints of blood were transfused. Patient recovered well. Histopathology confirmed products of conception.

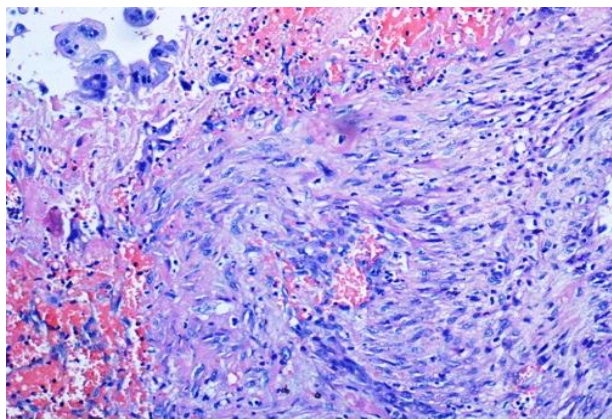


Figure 1: Ovarian stroma with hemorrhagic material with fibrin and polymorphism showing syncytiotrophoblasts.

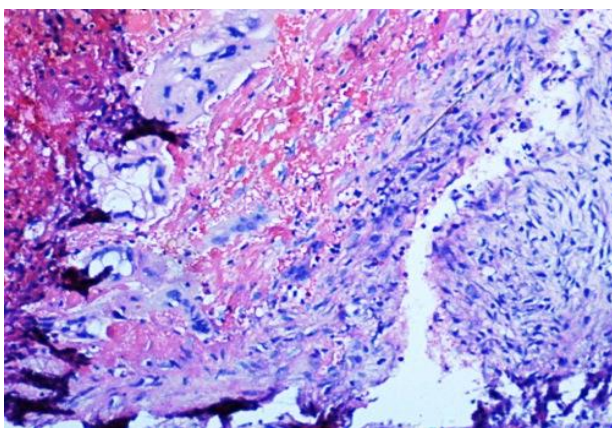


Figure 2; Chorionic villi embedded in ovarian stroma along with areas of haemorrhage and inflammation.

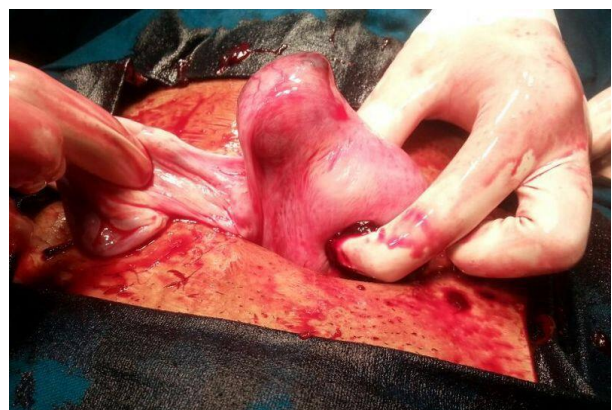

Figure 3: Right sided cornual pregnancy.

DISCUSSION

One of the leading causes of maternal morbidity and mortality in our country remains ectopic pregnancies. Ectopic pregnancies are estimated to have an incidence of 1-2% worldwide and there is an increasing trend owing to increase in use of IUCD, tubal surgeries, increase in incidence of infertility, assisted reproductive techniques and incidence of pelvic infections.^{1,6}

Amongst ectopic pregnancies, non tubal pregnancies are most difficult to diagnose preoperatively and present therapeutic dilemmas intraoperatively. Diagnosis remains a challenge owing to insignificant period of amenorrhea, limited use of ultrasound for diagnosis of early pregnancy in developing countries and emergency presentation as acute abdomen. An accurate diagnosis is made only on emergency laparotomy/laparoscopy later confirmed by histopathological examination.

The first report is a case of primary ovarian pregnancy which accounts for less than 3% of ectopic pregnancies.¹ It is diagnosed by Spiegelbergs criteria which are:²

1. The fallopian tube with its fimbriae should be intact and separate from the ovary.
2. The gestational sac should occupy the normal position of the ovary.
3. The gestational sac should be connected to the uterus by the ovarian ligament.
4. Histologically proven ovarian tissue should be located in the sac wall.

The exact cause for ovarian pregnancy is unknown. Various hypothesis have been put forward like fertilization of ovum inside the ovary or implantation of fertilized ovum in ovary, PID, reverse migration of fertilized ovum, tubal diseases and thickened tunica albuginea, interference with release of ovum from ruptured follicles.³⁻⁵ Additionally IVF and IUCD's are implicated to increase its incidence.⁴

Treatment of almost all known ovarian ectopic pregnancies has been surgical. Although there are successful case reports with methotrexate management in hemodynamically stable and low HCG titre patients.⁵

The second case is a rare case of cornual (interstitial) pregnancy. The definition of cornual ectopic pregnancy is still debated. Most of the authors accept "interstitial" and "cornual" as synonyms, however some use the "cornual" term in pregnancies in bicornuate or septate uterus.⁶ The interstitial part of the fallopian tube is the proximal portion that lies within the muscular wall of the uterus. Pregnancies implanted in this site are called interstitial (cornual) pregnancies.⁷ The eccentric position of the gestational sac and thinning of the myometrial layer means that preoperative ultrasound differentiation between eccentric intrauterine and cornual pregnancy is always difficult. With the availability of better resolution

transvaginal ultrasound facilities, rate of diagnosis can be improved using three criteria:^{8,9}

1. An empty uterus
2. A gestational sac seen separately and <1 cm from the most lateral edge of the uterine cavity
3. A thin myometrial layer surrounding the sac.

Care must be taken to avoid mistaking a normal intrauterine gestational sac in an anomalous uterus (bicornuate uterus) or an angular pregnancy with a cornual pregnancy. In an angular pregnancy the sac is implanted medial to the round ligament contrary to the cornual pregnancy where it is lateral to the round ligament.

Since the region has abundant blood supply from ovarian and uterine vessels and presence of vascular and muscular support, rupture of cornual pregnancies occur later in gestation than other ectopics. Also often leads to severe haemorrhage and rapidly results in shock, morbidity and mortality. Interestingly in our case it had ruptured at a much earlier gestation and hence the associated severe complications were averted. Most often consultants have to resort to emergency laparotomy followed by cornual resection and repair or even hysterectomy. A laparoscopic approach can also be tried provided the surgeon is skilled in laparoscopic techniques and patient condition is suitable. If diagnosed earlier, medical management with systemic methotrexate has been successfully tried in a few cases.¹⁰ This avoids extensive surgery and future obstetric disasters like rupture of uterus.

CONCLUSION

Since non tubal ectopic pregnancies have low preoperative diagnosis they most often present as an intraoperative surprise to the consultant. This brings in therapeutic dilemmas as one has to decide n choose between conservative surgeries like ovarian wedge resection versus radical decisions like oophorectomy. Also since they carry the risk of rupture, massive haemorrhage and increased morbidity/mortality - a high index of suspicion, early diagnosis by timely use of USG in first trimester and referral to a tertiary centre with emergency OT and blood bank facilities must be

undertaken to reduce morbidity and mortality associated with rare ectopic pregnancies.

Funding: No funding sources

Conflict of interest: None declared

Ethical approval: Not required

REFERENCES

1. Das S, Kalyani R, Lakshmi V, Kumar HML. Ovarian pregnancy. Indian J Pathol Microbiol. 2008;51:37-8.
2. Spiegelberg O. Zur casuistik der ovarialschwangerschaft. Arch Gynaekol. 1878;13:73-5.
3. Sharma B, Preston J, Olibo N. Ovarian pregnancy: An unusual presentation of an uncommon condition. J Obstet Gynecol. 2002;5:565-6.
4. Gaudoin MR, Coulter KL, Robins AM, Verghese A, Harretty KP. Is the incidence of ovarian ectopic pregnancy increasing? Eur J Obstet Gynecol Reprod Biol. 1996;70:141 .
5. Ismail MI, Özge Ö, Terek MC, Aygül S. Primary Ovarian pregnancy: A Case report and review of the literature, Ege Tıp Dergisi. 2004;43(2):113-5.
6. Birge O, Erkan MM, Ozbey EG, Arslan D. Ruptured cornual ectopic pregnancy: case reports. POG in Press. 2015.
7. Tulandi T, Al-Jaroudi D. Interstitial pregnancy: results generated from the Society of Reproductive Surgeons Registry. Obstet Gynecol. 2004;103:47-50.
8. Auslender R, Arodi J, Pascal B, Abramovici H. Interstitial pregnancy: Early diagnosis by ultrasonography. Am J Obstet Gynecol 1983;146:717-8.
9. Timor-Tritsch IE, Monteagudo A, Matera C, Veit CR. Sonographic evolution of cornual pregnancies treated without surgery. Obstet Gynecol. 1992;79:1044-9.
10. Jermy K, Thomas J, Doo A, Bourne T. The conservative management of interstitial pregnancy. BJOG. 2004;111:1283-8.

Cite this article as: Madhuri N. Diagnostic surprises in early pregnancy: two case reports. Int J Res Med Sci 2016;4:972-4.