

Original Research Article

Role of special stains as a useful complementary tool in the diagnosis of renal diseases: a case series study

Veena Venkatesh¹, Vinuta Malaichamy^{2*}

¹Department of Pathology, Karpagam Faculty of Medical Science and Research, Coimbatore, India

²Department of Pathology, Coimbatore Medical College, Coimbatore, India

Received: 04 March 2019

Revised: 07 April 2019

Accepted: 11 April 2019

*Correspondence:

Dr. Vinuta Malaichamy,

E-mail: vinurg1010.vu@gmail.com

Copyright: © the author(s), publisher and licensee Medip Academy. This is an open-access article distributed under the terms of the Creative Commons Attribution Non-Commercial License, which permits unrestricted non-commercial use, distribution, and reproduction in any medium, provided the original work is properly cited.

ABSTRACT

Background: Renal diseases constitute a major cause of morbidity in clinical practice and their incidence is on rise. Investigation usually requires division into even smaller samples to permit the application of specialized techniques.

Methods: This is a prospective study conducted over a period of one year from January 2018 to December 2018 in the Department of Pathology, Coimbatore. A total of 58 renal biopsies were received from the Nephrology Department and the tissues were subjected to light microscopic and special stain studies.

Results: Total 53 patients (91.38%) had high blood urea nitrogen value more than 20.0 mg/dl. 48 patients (82.76%) had high serum creatinine value more than 1.2 mg/dl. Out of 58 biopsy specimens, 46 (79.31%) showed primary glomerular lesions, 10 (17.24%) showed secondary glomerular lesion and 2 (3.45%) showed tubulointerstitial nephritis. Jones's methanamine silver stain along with PAS stain helped in typing/staging of membranous glomerulopathy and membranoproliferative glomerulonephritis. Various changes in GBM like spike formation, thickening and moth-eaten appearance of GBM was noted which is seen in MGN stage II, IV and III respectively. Double contour and thickening of GBM was noted which is seen in type I and II MPGN respectively. In Myeloma cast nephropathy, tubular casts stained negative with Congo red which was used to differentiate it from amyloid deposition.

Conclusions: The special stains used in this study helped in supplementing the light microscopic findings for diagnosis of kidney lesions. However, the use of other ancillary techniques like immunofluorescence and electron microscopy would help the pathologists in better and more accurate diagnosis.

Keywords: Renal diseases, Special stains

INTRODUCTION

Renal biopsy invention was one of the major events that took place in the history of nephrology.¹ First attempt of renal biopsy was made by Allwall in Sweden in 1944 but it was unpublished.² In 1951, Brun and Iversen published their experiences in renal biopsy with patients in the sitting position.³ But the success rate was low. Kark and Muehreke in 1954 performed the first kidney biopsy in

prone position.⁴ Vim-Silverman needle was first used for this procedure.⁵ From then, this technique became popular and now nephrologists prefer ultrasound (USG) and Contrast Tomography (CT) guided biopsy to locate the lesions and simplify the technique.

Indications for renal biopsy⁶

- Nephrotic syndrome

- Permanent proteinuria associated with microhematuria
- Systemic Lupus Erythematosus
- Patients presenting with acute renal failure of unknown origin
- Systemic diseases with renal involvement
- Isolated hematuria
- Intermittent proteinuria

Contraindications

Renal biopsies are contra-indicated in -uncontrolled bleeding diathesis

Relative contraindications include

- uncontrolled hypertension (>160/95)
- uncooperative patient
- patient unable to consent
- solitary kidney
- obstructed kidneys
- small kidneys
- anatomical abnormalities
- renal neoplasm, multiple cysts, abscess, pyelonephritis.

Procedure of renal biopsy

Renal biopsy is usually performed in prone position. Lower pole of kidney is preferred due to reduced risk of injury to major vessel. Trucut needle (Vim-Silverman needle) and automated biopsy guns are used to do the procedure with equal efficacy.

Renal biopsy is done by either USG or CT guided approach. Other accesses include laproscopic biopsy and tranjugular kidney biopsy.

Adequacy of sample⁷

Needle gauge: 18 gauge

Number of glomeruli needed for adequate diagnosis

- For glomerular lesions- 5
- For tubule-interstitial lesions-6-10
- For transplant kidney-7

Tissue fixation and staining

Tissue sections should not be more than 2 to 3 microns thick. Sections should include light microscopy and special stains, immunofluorescence and electron microscopy. 10% buffered formalin is the ideal fixative for kidney biopsy.⁷

High magnification light microscopy is very essential to evaluate glomerular diseases. It should be possible to cut sections at 3 microns thickness or less. As a minimum,

sections should be routinely stained by a technique that highlights cells, such as Hematoxylin and Eosin and one that highlights basement membrane and connective tissue matrix, such as methanamine silver. Periodic Acid Schiff stain (PAS) is sometimes used to achieve both these goals. However, the procedure of methanamine silver staining is difficult because overstaining or understaining can be of no use.⁸

Various other stains can be used under special circumstances. Congo red stain is used for amyloid. Extremely small quantities of amyloid which are undetectable by Hematoxylin and Eosin stain can be detected by this stain.

Post biopsy care

After the procedure of renal biopsy is over, patients are given 8 to 10 hours rest and their vitals are monitored. Rare complications include pain, bleeding and hematoma.

This study was done to analyse the clinical features and parameters in the spectrum of renal diseases and to correlate with the histomorphological diagnosis and to special stains including Periodic acid Schiff (PAS) and Jone's methanamine silver (JMS) stains in renal diseases.

METHODS

The present study was conducted in the Department of Pathology, Coimbatore Medical College, Coimbatore from January 2018 to December 2018. A total of 58 cases, two renal biopsies for each case were received. The study was performed based on the following proforma.

Inclusion criteria

Renal biopsy specimens of the patients of all age groups and both sexes with altered renal function suggestive of kidney disease from the Department of Nephrology, Coimbatore Medical College and Hospital, Coimbatore were included in this study.

Exclusion criteria

- Specimens that are very tiny for processing and considered inadequate with no glomeruli in subsequent serial sections for light microscopy.
- Specimen without required clinical and histopathological details.
- Clinically suspected cases of diabetic nephropathy.
- Patients that are considered unfit for biopsy (coagulation abnormalities, poor cardiac function).

Indications for biopsy

- All nephrotic syndrome and nephritic syndrome patients who are willing for renal biopsy.
- Patients with acute renal failure not recovering within 4 weeks of duration.

- All patients with systemic lupus erythematosus who are willing for biopsy.

Methods of collection of samples

Before the procedure a pre-renal anaesthetic assessment including prothrombin time, bleeding time, complete blood count was checked and xylocaine needle test dose was given.

After obtaining informed consent, under local anaesthesia and aseptic precautions, two cores of percutaneous ultrasound guided biopsy specimens of kidney were taken from the patients with altered renal functions and tissue was sent in 10% neutral buffered formalin for routine light microscopic examination. The procedure was performed with an informed consent by the clinician as a routine procedure for diagnosis and treatment.

Light microscopy

The renal tissue obtained in 10% neutral buffered formalin is kept for fixation for 12 hours to 24 hours and it is then processed and embedded in paraffin. The sections of 3µ to 4µ thickness were cut and stained using haematoxylin and eosin.

Special stains like Periodic Acid Sciff and Jone’s methanamine silver stain were performed to look for the abnormalities in the glomerular basement membrane.

RESULTS

The present study is a prospective study of renal biopsies received over a period of one year. The total number of biopsies received are 58 from the Department of Nephrology, Coimbatore Medical College and Hospital, Coimbatore.

The highest number of patients were in the age group 31years to 40 years (16) which constituted 27.5% of patients followed by the age group 41 years to 50 years (15) which constituted 25.8% of the patients. The mean age was 33.03 years and median were 35 years. The youngest patient was 9 years and the oldest patient was 57 years.

The most common lesion in the age groups 3 (between 21years to 30 years) and 4 (31years to 40 years) was diffuse proliferative glomerulonephritis. The most common lesion in the groups 1 and 2 (between 1 year to 20 years) was focal segmental glomerulosclerosis and in the age group 5 (41 years to 50 years) was membranous glomerulonephritis.

Patients belonging to group 6 (between 51 years to 60 years) had the diagnoses of diffuse proliferative glomerulonephritis, membranoproliferative glomerulonephritis and mesangioproliferative glomerulonephritis.

It was noted that there was equidistribution of patients among males and females. Of the 58 cases, 28 patients were males constituting 48.27% and 30 patients were females constituting 51.27%. The male to female ratio was found to be 0.933:1. The most common glomerular lesion noted in males was diffuse proliferative glomerulonephritis (10 out of 28 cases) and in females was Lupus nephritis (7 out of 30 cases).

Of the 58 patients, 53 patients (91.38%) had high blood urea nitrogen value (>20.0 mg/dl). Blood urea nitrogen value was normal in 5 patients (8.62%) whose diagnoses included focal segmental glomerulosclerosis (1 patient), minimal change disease (1 patient), membranoproliferative glomerulonephritis (1 patient), IgA nephropathy (1 patient) and acute tubular necrosis (1 patient) (Table 1).

Table 1: Distribution of cases based on blood urea nitrogen value (mg/dl).

BUN (mg/dl)	Frequency	Percent
Normal (7-20.0)	5	8.62
High (>20.0)	53	91.38
Total	58	100.0

Of the 58 patients, 48 patients (82.76%) had high serum creatinine value and 10 patients (17.24%) had normal serum creatinine value whose diagnoses included diffuse proliferative glomerulonephritis (4 patients), focal segmental glomerulosclerosis (2 patients), IgA nephropathy (2 patients), mesangioproliferative glomerulonephritis (1 patient), and membranoproliferative glomerulonephritis (1 patient).

Table 2 shows distribution of cases based on 24 hours protein levels.

Table 2: Distribution of cases based on 24 hours urine protein levels (g/day).

Urine protein (g/day)	Frequency	Percent
<3.5	35	60.34
>/=3.5	23	39.66
Total	58	100.0

Table 3: Distribution of renal diseases.

Diagnosis	Frequency	Percent
Primary glomerulonephritis	46	79.31
Secondary glomerulonephritis	10	17.24
Tubulointerstitial nephritis	2	3.45
Total	58	100.0

Renal diseases were categorized as primary glomerulonephritis, secondary glomerulonephritis and tubulointerstitial nephritis. Table 3 shows distribution of renal diseases in the present study.

Table 4 shows distribution of cases based on the diagnosis obtained by renal biopsy.

Special stains performed in this study were Periodic Acid-Schiff stain, Jones Methanamine Silver stain, Congo Red stain and Masson Trichrome stain. The findings of special stains were elaborated in Table 5.

Figures 1(A), 1(B) and 1(C) show renal biopsy with membranous glomerulonephritis with features of glomerular basement membrane thickening. JMS stain highlights the spikes in the basement membrane. Jones's methanamine silver stains helped in typing/staging of membranous glomerulopathy and membrano proliferative glomerulonephritis.

In 5 patients of MGN, spike formation was noted in GBM in 2 patients which is seen in stage II MGN, thickening of GBM was noted in 2 patients which is seen in stage IV MGN and moth eaten appearance of GBM was seen in 1 patient which is noted in stage III MGN.

Out of 8 patients of MPGN, double contour of GBM was noted in 3 patients which is seen type I MPGN (Figures 2(A), 2(B) and 2(C)) and thickening of GBM was noted in 5 patients which is seen in type II MPGN. However, confirmatory typing/staging should be done when special stains findings are combined with electron microscopy findings of location of immune complex deposits.

Table 4: Distribution of cases based on diagnosis.

Final diagnosis	Frequency	Percent
A.Primary glomerulonephritis	(N=46)	79.31
Diffuse proliferative glomerulonephritis	13	28.26
Membranoproliferative glomerulonephritis	8	17.39
Focal segmental glomerulosclerosis	7	15.22
Membranous nephropathy	5	10.87
Minimal change disease	5	10.87
Ig A Nephropathy	2	4.35
C1q Nephropathy	2	4.35
Mesangioproliferative glomerulonephritis	2	4.35
Chronic glomerulonephritis	1	2.17
Sclerosing glomerulonephritis	1	2.17
B. Secondary glomerulonephritis	(N=10)	17.24
Lupus nephritis	7	70
Hypertension glomerulopathy	2	20
Myeloma cast nephropathy	1	10
C. Tubular interstitial disease	(N=2)	3.45
Acute tubular necrosis	2	100.0
Total	(N=58)	100.0

Table 5: Special stains findings.

Diagnosis	Stains performed	Findings
Focal segmental glomerulosclerosis (n=7)	PAS	PAS-positive sclerosed part of glomeruli (n=7)
	JMS	Wrinkled lines of GBM in sclerosed part of glomeruli (n=7)
Membranous nephropathy (n=5)	PAS	Thickened GBM (n=5)
	JMS	Spike formation in GBM (n=2)
		Thickened GBM (n=2)
Membranoproliferative glomerulonephritis (n=8)	PAS	Thickened GBM (n=8)
	JMS	Double contour of GBM (n=3)
		Thickening of GBM (n=5)
Myeloma cast nephropathy (n=1)	PAS	Weak Positive in tubular casts (n=1)
	JMS	Negative in tubular casts (n=1)
	Congo red	Negative in tubular casts (n=1)
	Masson Trichrome stain	Casts appear green color (n=1)

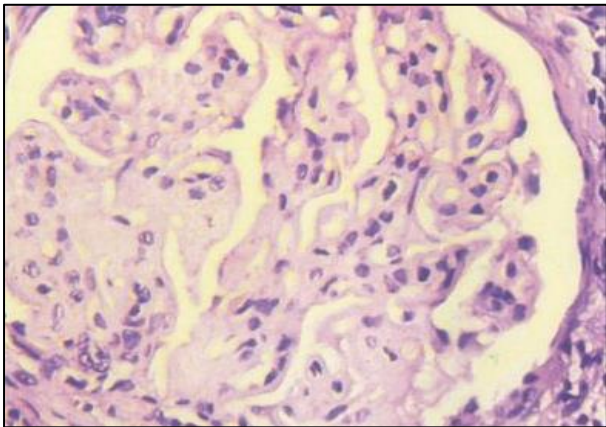


Figure 1 (A): Membranous glomerulonephritis showing uniform thickening of glomerular basement membrane (H&E 40X).

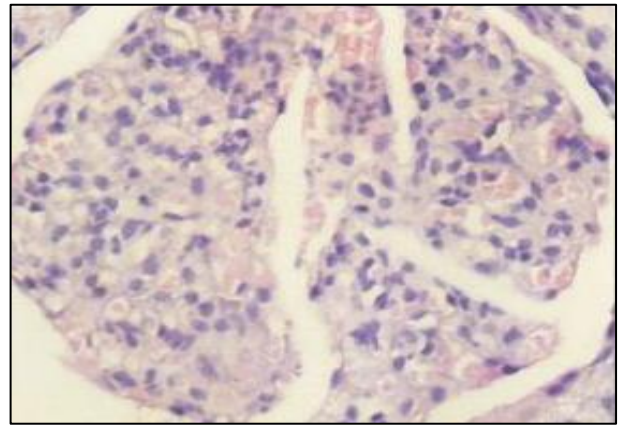


Figure 2 (A): Membranoproliferative glomerulonephritis showing mesangial and endocapillary proliferation (H&E 40X).

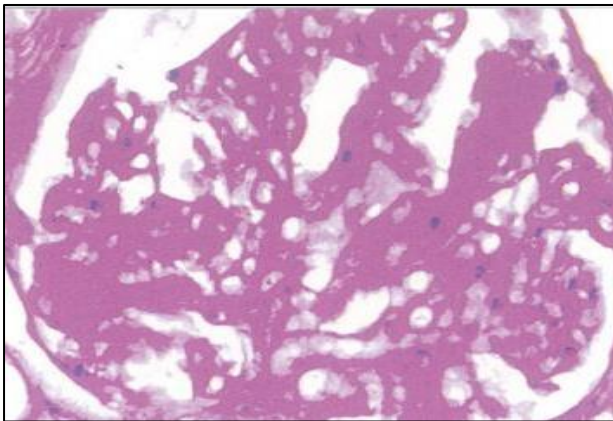


Figure 1 (B): Membranous glomerulonephritis with uniform thickening of glomerular basement membrane highlighted by PAS stain (40X).

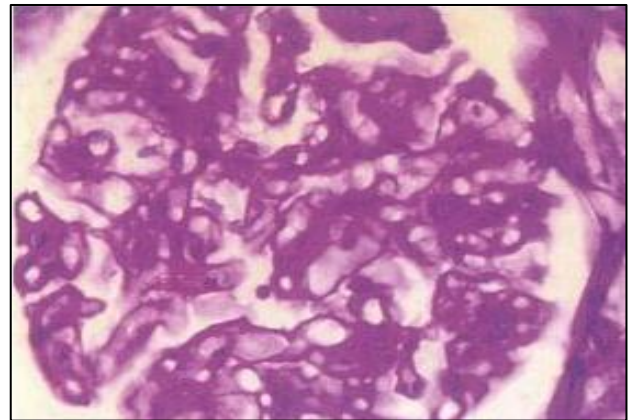


Figure 2 (B): PAS stain showing thickened glomerular basement membrane (40X).

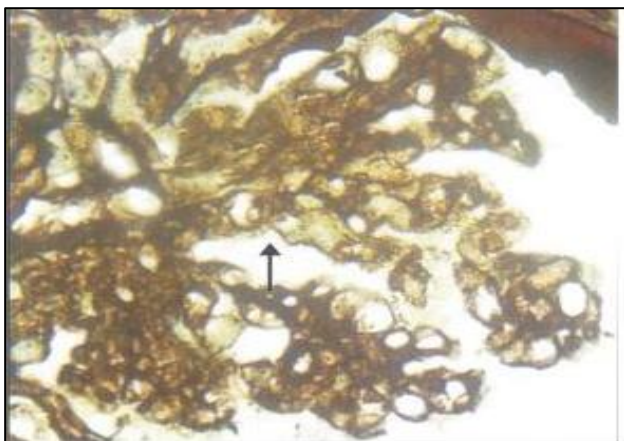


Figure 1 (C): Arrow showing spikes in glomerular basement membrane (40X).

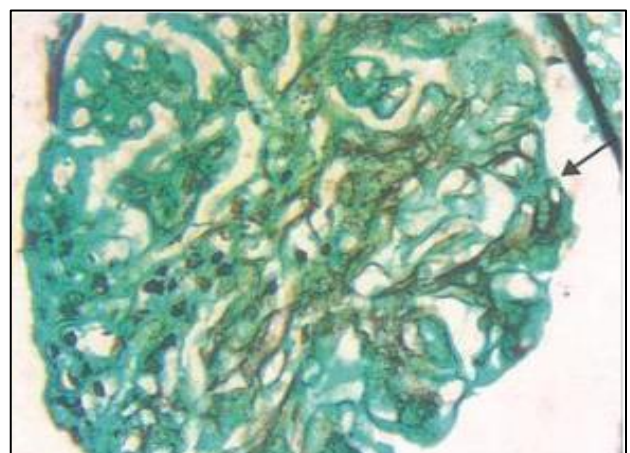


Figure 2 (C): Membranoproliferative glomerulonephritis stained by JMS stain showing classical double contour of glomerular basement membrane (arrow) (40X).

In a patient of myeloma cast nephropathy, tubular casts stained negative with Congo red which was used to differentiate it from amyloid deposits. Other stains like PAS, JMS and Masson trichrome were performed which stained weakly positive, negative and green color respectively (Figures 3(A) and 3(B)).

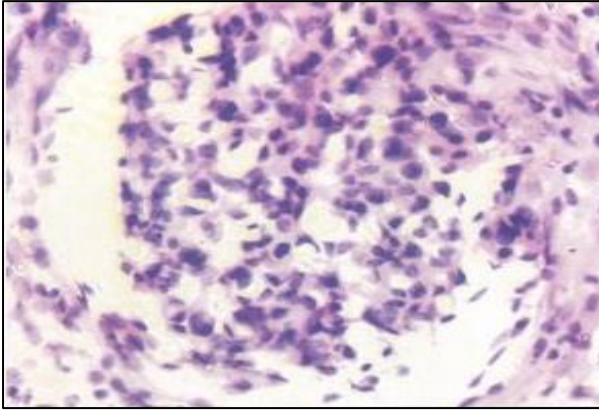


Figure 3(A): Myeloma nephropathy showing plasma cell infiltration (H&E 40X).

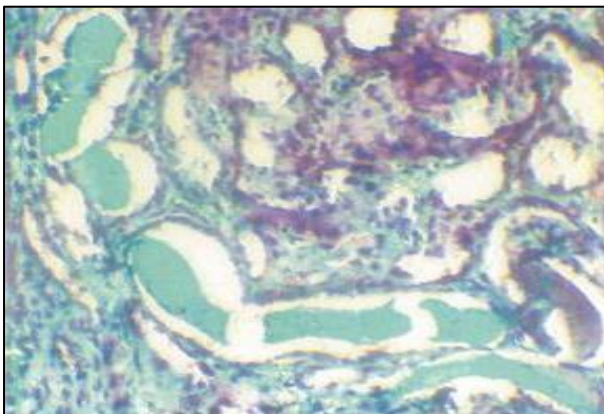


Figure 3(B): Myeloma cast showing green colour in masson trichrome stain (40X).

DISCUSSION

Glomerulonephritis constitutes a major health issue on the health services in developing countries like India. Long term complications are common in these diseases. Early diagnosis and treatment can prevent the morbidity in patients.

The age of patients in this study range from 9 years to 57 years, which is in league with the study by Simon P et al, whose study showed the age range of 10 years to 80 years.⁹ In this study, slight female predominance was noted with male to female ratio being 0.933:1. This is in concordance with the study done by Okpechi I et al, who found the ratio to be 0.824:1.¹⁰

In the present study, primary glomerular lesions constituted 79.31% of the renal diseases which was in

concordance with the study by Alwahaibi et al.¹¹ Diffuse proliferative glomerulonephritis was the most common primary glomerular lesion noted which is in league with study done by Lt Col GU Deshpande et al.¹²

Renal biopsy has contributed greatly to a rational classification of intrinsic renal diseases. In the present study, secondary glomerular lesions constituted 17.24% of the renal diseases which correlated with Howard et al, and Ivan Rychlík et al, and the most common secondary glomerular lesion was Lupus nephritis which is in concordance with the studies done by Ahmed Al Arrayed et al, Abdu N et al Alwahaibi NY et al, and Rychlík I et al.^{8,11,13} All the patients of lupus nephritis were females.

In the present study, tubulointerstitial nephritis cases constituted 3.45% which is in concordance with the study done by Malafrente P et al.¹⁴

It is useful to apply different stains because the information obtained is complementary. For first hand information for routine diagnostic evaluation, hematoxylin and eosin stain is appropriate. It provides the first information of the composition of the tissue, i.e., renal cortex, medulla, number of glomeruli, cellular infiltration, etc. To analyse the glomerular changes, PAS stain is most useful since it delineates in great detail the glomerular cells, mesangial matrix and potential expansion as well as potential modification of the composition of the matrix, changes of the glomerular basement membrane like thickening, irregularities, doubling, rupture and fibrinoid necrosis of the glomerular tuft. A further advantage of the PAS stain is alterations of the vessels particularly arterial hyalinosis and fibrinoid necrosis, are easy to detect. Immune deposits can best be visualized by protein stains such as the acid fuchsin-Orange G stain (SFOG). Often immune deposits can already be seen or suspected by light microscopy, but definite information requires specific stains or additional investigations, i.e. immunohistochemistry or electron microscopy.¹⁵

The main advantage of the silver stain is that it permits the detection of changes of the GBM, i.e. so-called reduplication or 'spikes' which develop as a result of overshooting glomerular production of basement membrane material encircling immunodeposits. In order to evaluate the extent of fibrosis in the glomerulus or tubular interstitium, fibrous tissue stains such as Trichrom, Sirius red or Ladewig stains are indispensable. For specific questions, additional staining techniques are available, for instance the Congo red stain for visualization of amyloidosis, or the Kossa stain to detect calcification.¹⁶

CONCLUSION

The epidemiology of renal diseases differs from developed countries to developing countries. Developing country like ours has shown that the incidence of post

infectious glomerulonephritis is still high compared to other glomerular lesions like membranous nephropathy and focal segmental glomerulosclerosis which is more common in developed countries. This can be attributed to the low socioeconomic status, prevalence of infections, lack of awareness regarding health care.

Use of special stains like Periodic acid Schiff and Jones's methanamine silver stains helped to identify the extent of glomerular basement membrane involvement and in typing/staging of MGN and MPGN that complemented the histomorphological findings. However, special stains in parallel with electron microscopy findings of location of immune complex deposits should be done for the confirmation of staging of MGN and typing of MPGN. This is helpful for the clinicians to plan a better therapeutic strategy in the nephrology patients.

Additional markers like kappa and lambda etc., could be applied in cases of myeloma kidney diseases to give a better diagnosis which includes predominant type of light chain deposition. Electron microscopy facility, when made available would complement the histomorphology and immunofluorescence findings.

Confirmation of IF findings with immunohistochemistry markers which could be stored for a longer period, might prove as another milestone in diagnosing renal diseases.

Funding: No funding sources

Conflict of interest: None declared

Ethical approval: The study was approved by the Institutional Ethics Committee

REFERENCES

1. Agarwal SK, Sethi S, Dinda AK. Basics of kidney biopsy: A nephrologist's perspective. *Indian J Nephrol.* 2013;23(4):243-52.
2. Alwall, N. Aspiration biopsy of the kidney, including report of a case of amyloidosis diagnosed in 1944 and investigated at autopsy. *Acta Med Scand.* 1952;143:430-5.
3. Iversen P, Brun C. Aspiration biopsy of the kidney. *Am J Med.* 1951;11:324-30.
4. Kark RM, Muehrcke RC. Biopsy of kidney in prone position. *Lancet.* 1954;266:1047-9.
5. Cameron S, Hicks J. The introduction of renal biopsy into nephrology from 1901 to 1961: a paradigm of the forming of nephrology by technology. *Am J Nephrol.* 1997;17(3-4):347-58.
6. Fuiano G, Mazza G, Comi N, Caglioti A, De Nicola L, Iodice C, et al. Current indications for renal biopsy: a questionnaire-based survey. *Am J Kidney Dis.* 2000;35(3):448-57.
7. Walker PD, Cavallo T, Bonsib SM. Practice guidelines for the renal biopsy. *Modern Pathol.* 2004;17(12):1555.
8. Hoffmann EO. High-resolution light microscopy for interpretation of renal biopsies. *Pediatr Nephrol.* 1995;9:763-9.
9. Simon P, Ramee MP, Boulahrouz R, Stanescu C, Charasse C, Seng aNG KI, et al. Epidemiologic data of primary glomerular diseases in western France. *Kidney Int.* 2004;66(3):905-8.
10. Okpechi I, Swanepoel C, Duffield M, Mahala B, Wearne N, Alagbe S, et al. Patterns of renal disease in Cape Town South Africa: a 10-year review of a single-centre renal biopsy database. *Nephrol Dialysis Transplant.* 2010;26(6):1853-61.
11. Alwahaibi NY, Alhabsi TA, Alrawahi SA. Pattern of glomerular diseases in Oman: A study based on light microscopy and immunofluorescence. *Saudi J Kidney Dis Transplant.* 2013;24(2):387.
12. Deshpande GU, Munjal R, Rai R. Spectrum of nephropathies with special reference to primary glomerulopathies. *Med J Armed Forces India.* 2000;56(2):125-9.
13. Rychlík I, Janc'ova' E, Tesar' VR, Kolský A, La'cha J, StejskalJ, et al. The Czech Registry of Renal Biopsies. Occurrence of Renal Diseases in The Years 1994-2000. *Nephrol Dial Transplant.* 2004;19:3040-9.
14. Malafrente P, Mastroianni-Kirsztajn G, Gustavo N. Nico B, 'Dio Roma' O J, Almerinda MR. et al. Paulista Registry of Glomerulonephritis: 5-Year Data Report. *Nephrol Dial Transplant.* 2006;21:3098-105.
15. Andreucci VE, Fuiano G, Stanziale P, Andreucci M. Role of renal biopsy in the diagnosis and prognosis of acute renal failure. *Kidney Int.* 1998 (Suppl 1);66:S91-5.
16. Amann K. New parameters in kidney biopsy diagnostic-morphometry. *Kidney Blood Pressure Res.* 2000;23(3-5):181.

Cite this article as: Venkatesh V, Malaichamy V. Role of special stains as a useful complementary tool in the diagnosis of renal diseases: a case series study. *Int J Res Med Sci* 2019;7:1539-45.