

Original Research Article

Interobserver reliability on landmark-guided sacroiliac joint injection among 5th year residency in Orthopedic and Traumatology Department Faculty of Medicine Brawijaya University Malang, Indonesia

Gladys Adipranoto^{1*}, Andhika Yudistira²

¹Department of Orthopedic and Traumatology, ²Department of Spine, Brawijaya University, Saiful Anwar General Hospital Malang, East Java, Indonesia

Received: 25 March 2019

Accepted: 03 May 2019

*Correspondence:

Dr. Gladys Adipranoto,

E-mail: g.adipranoto@gmail.com

Copyright: © the author(s), publisher and licensee Medip Academy. This is an open-access article distributed under the terms of the Creative Commons Attribution Non-Commercial License, which permits unrestricted non-commercial use, distribution, and reproduction in any medium, provided the original work is properly cited.

ABSTRACT

Background: The most common misdiagnosed low backpain is result from the sacroiliac joint. There are a lot of methods we can use to treat it such as steroid injection. This method can be done by using landmark-guided technique or image-guided. Unfortunately, not all hospital in this country has the same facility to do image-guided technique using fluoroscopy to do the injection. Therefore, landmark-guided technique still could be used for the treatment of choice.

Methods: In this research, authors did injection on sacroiliac joint of 7 preserved cadavers, on both sacroiliac joint, injection were done by 2 operators, which both are 5th- year residents of Orthopedic and Traumatology Department using 2 coloring markers, therefore each of operator got 14 injection spots. Operator 1 uses methyl red, and operator 2 uses methylene blue. The success of the injection evaluated visually. If operator 1 achieved the injection, the sacroiliac joint would be bright red coloured. If operator 2 achieved the injection, the sacroiliac joint would be blue coloured. If both operator achieved the injection on the same joint, the mixture of both will be dark green coloured.

Results: The result shown the success of both operator in doing injection for the sacroiliac joint is 9 joints (32.14%). There were 5 joints (17.86%) done by operator 1, and 4 joints (14.28%) done by operator 2. Operator 1 failed on 9 (32.14%) joints and operator 2 failed on 10 (35.72%) . The data was statistically analysed using Fisher Exact Test, result in p value 0.500 (p >0.05).

Conclusions: In conclusion there is no significantly different the success of the injection between operator 1 and 2. The failure of the injection on sacroiliac joint could be affected by many factors such as injection technique, and anatomy variations of the sample.

Keywords: Cadaveric sacroiliac study, Injections in orthopedic, Intracuticular injections, Landmark-guided injections, Sacroiliac injections, Sacroiliac joint, Sacroiliac

INTRODUCTION

Back pain is the most common problem presenting in 95% of world population for at least once in a lifetime.¹⁻³ Backpain caused by multifactorial, for instance

degenerative disc disease, facet arthropathy, and physical overload.² Mostly the exact pathology cannot be easily diagnosed, sacroiliac is one of the site of it. Sacroiliac (SI)-caused back pain has the same prevalence as

radiculopathic back pain as 13-30%, of which the pain is usually felt in the lower back and or buttock.^{1,4}

Sacroiliac joint (SIJ) pain frequently misdiagnosed, disguised by other back pain sources. To diagnose it we need very detail anamnesis, physical examination especially thorough spine examination and SIJ by perform special test like distraction test, thigh trust, compression test, Patrick test, Gaenslen's maneuver dan Fortin finger test.^{4,5} However, in acute pain all those examination could not all be done, and we may need radiographic imaging such as USG, x-ray photo, CT-scan, MRI and nuclear bone scan. All of them can be used as a guidance to do injection method.¹⁻⁴ Injection aim to confirm the source of pain if it is come from SIJ or others. It is also can be used as therapeutic method to treat the pain.^{2,4,5}

Injection can be done by landmark-guided and image-guided (USG, fluoroscopy, CT-Guided dan MRI Guided) method.⁹ Based on previous study, to put the intraarticular injection precisely we need fluoroscopy guidance, there are 60 patients injected using landmark-guided method, 5 of that injection nearly went to the SIJ and there is no patient had the precise intraarticular one.^{1,5-7}

Landmark-guided method still frequently used; in contrast the precision is still questionable.⁸ The background is because many hospital in Indonesia have no facility to do image-guided method. For example, in our region Malang there are only 4 of 55 hospital have fluoroscopy.

Spinal injection is one of the competency in completing orthopedic degree, including facet block, and nerve root block. Based on that, our Orthopedic and Traumatology department trying to improve the ability of the graduates to do injections without image guide. Aim of this study is to know the reliability of the 5th residents on doing SIJ injection using landmark-guided method.

METHODS

This is an experimental study, using 7 prepared cadavers, provided by Forensic Medicine Department in Saiful Anwar General Hospital Malang (RSSA) on February 2018. They are all the population and sample for this study, each of them has 2 SIJ. Each of SIJ injected by 2 operators (operator 1 and 2). Each operator injected different marker.

Operator 1 injected methyl red, and operator 2 injected methylene blue. Injected site by operator 1 is red and operator 2 is blue. If both operator injected the same site, the combination of the marker is green.

Injection

- Cadaver preparation and positioning (prone)

- Tools preparation
- SIJ identification using landmark-guided method, and marking using surgical marking pen (gentian violet), identify PSIS, and midsacral line, point of injection is marked "x" (Figure 1).^{9,10}

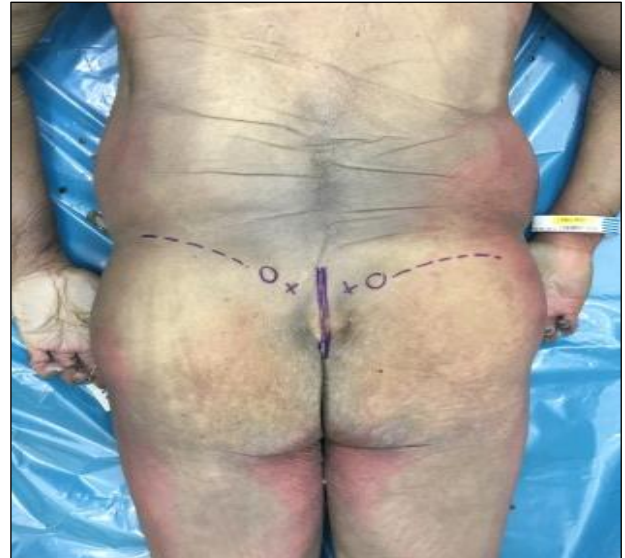

Figure 1: Injection landmark.

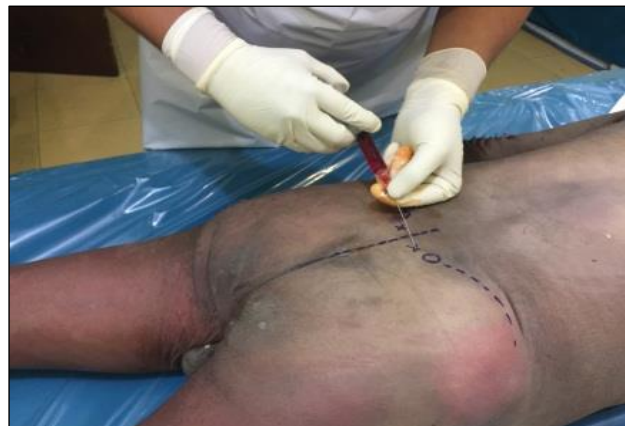

Figure 2: Operator 1.

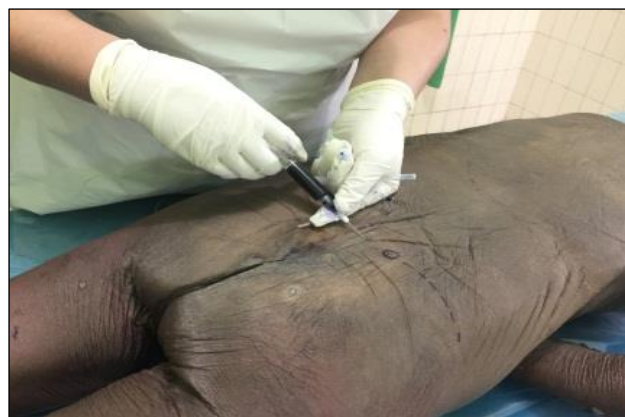

Figure 3: Operator 2.

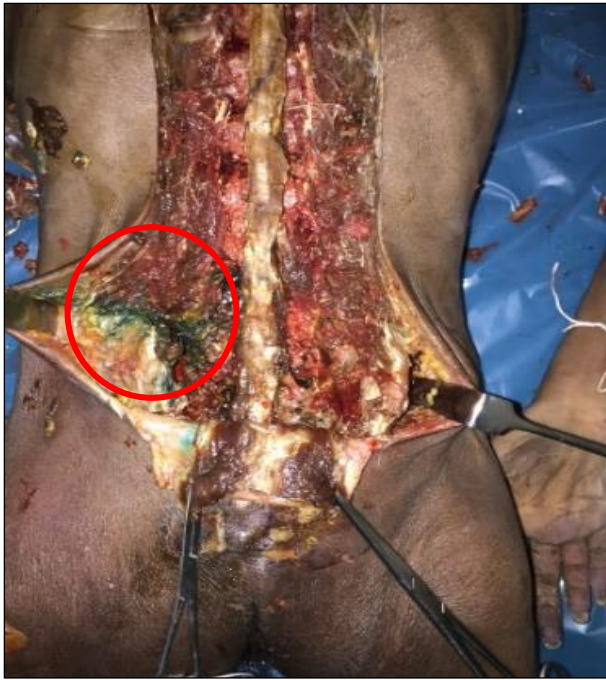

Figure 4: Example of the successful injection through the SIJ.

- Injection by each operator, on each SIJ of 7 cadavers (14 injections each operator) using spinocan-braun 20G, through the “x” mark, 45 degree anterolateral (Figure 2, 3 and 4).^{9,10}
- Dissection of the site and open the SIJ, identify the marker.

RESULTS

Collected data was processed using SPSS 24, with chi-square test (Table 1).

Table 1: Cross Table 2x2 Injection Result.

Operator	Injection Result		Total	P value
	Successful	Failed		
Operator 1	5 (17.86%)	9 (32.14%)	14 (50%)	0.500
Operator 2	4 (14.28%)	10 (35.72%)	14 (50%)	
Total	9 (32.14%)	19 (67.86%)	28 (100%)	

Table 1 shows the result of both operator on doing injection is 9 (32.14%) points of SIJ injection. 5 (17.86%) points by operator 1 and 4 (14.28%) points by operator 2.

Operator 1 failed on 9 (32.14%) points of SIJ and operator 2 is 10 points (35.72%). The result was analysed using Fisher Exact test, the p value is 0.500 ($p > 0.05$), conclude that the result of SIJ injection was not significantly different between both operators.

DISCUSSION

To evaluate the result of SIJ injections, the injection area is divided into 4 zones as seen in figure. Zone 1 is intrarticular successful injection to the SIJ, zone 2 is periarticular (failed), zone 3 is lateral to the SIJ (failed) and zone 4 medial to the SIJ (failed) (Figure 5).

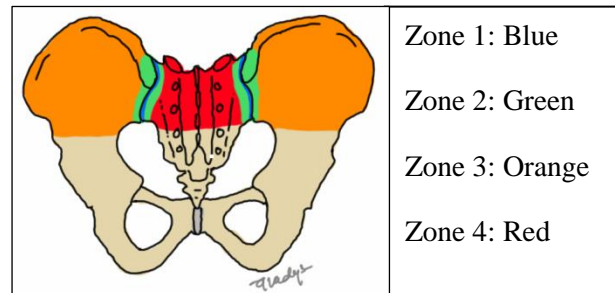


Figure 5: Zone of Injection.

The result shows, operator 1 success on 5 points (zone 1) and failed on 9 points (all on zone 3). Operator 2 success on 4 points and failed on 10 points (all on zone 3) (Table 2).

Table 2: Zone of Injection Result.

Operator	Zone 1	Zone 2	Zone 3	Zone 4
1	5 points	-	9 points	-
2	4 points	-	10 points	-

Theoretically, injections to SIJ could be done by two method, by landmark guide or image guide (USG, fluoroscopy, CT-Guided dan MRI Guided). A study shows that its necessary to use image-guide to put the injection precisely through the intraarticular.^{5,6} From 60 patients injected using landmark guide method, only 5 patients got an injection particularly, and none of the entire result that was successful through SIJ. In conclusion, technique for intraarticular SIJ injection using landmark guide is relatively difficult to make. It is subjectively dependent to the skill of the operator and anatomical variation of the patient.

In this study, the operators are residents of Orthopedic and Traumatology in their 5th year which done their rotation in spine section 1-2 times per semester, which is a month of each and experienced 0-2 case of SIJ injection per month. These made the exposure to the SIJ case is very minimal.

The limitation of this study is the minimal sample source and not homogen because the distribution of sample age, gender and et cetera is very high in variety.

CONCLUSION

The result of this study was the result of injection between two operators has no significant difference. The

success of the injection is multifactorial such as injection technique, anatomical variant of the sample.

Funding: No funding sources

Conflict of interest: None declared

Ethical approval: The study was approved by the Institutional Ethics Committee

REFERENCES

1. Cohen SP. Sacroiliac joint pain: a comprehensive review of anatomy, diagnosis, and treatment. *Anesth Analg*. 2005;101(5):1440-53.
2. Herkowitz HN, Garfin SR, Eismont FJ, Bell GR, Balderston RA. Rothman Simeone The Spine. Targeting Pain Generators. 6th Ed. Elsevier Saunders; Philadelphia. 2011:260-265.
3. Kennedy DJ, Engel A, Kreiner DS, Nampiaparampil D, Duszynski B, MacVicar J. Fluoroscopically guided diagnostic and therapeutic intra-articular sacroiliac joint injections: a systematic review. *Pain Med*. 2015;16(8):1500-18.
4. Garfin SR, Eismont FJ, Bell GR, Fischgrund JS, Bono CM. Rothman Simeone and Herkowitz's The Spine. Sacroiliac Joint Pain Pathophysiology & Diagnosis. 7th Ed. Elsevier Saunders: Philadelphia; 2011:397-402.
5. Boos N, Aebi M. Spinal disorders: fundamentals of diagnosis and treatment. 1st Ed. Springer: Berlin. 2008:253,280-2.
6. Kothari G, Sinha A. Pocket Handbook of Spinal Injections. Demos Medical Publishing: USA. 2014:17-20.
7. Tur SB. Sacroiliac joint injections in patients with sacroiliitis. *Turkish J Rheumatol*. 2012;27(3):149-51.
8. Rupert MP, Lee M, Manchikanti L, Datta S, Cohen SP. Evaluation of sacroiliac joint interventions: a systematic appraisal of the literature. *Pain Physician*. 2009;12(2):399-418.
9. Saunders S, Longworth S. Injection Technique in Musculoskeletal Medicine: A Practical Manual for Clinicians in Primary and Secondary Care. 4th Ed. Elsevier: Churchill, Livingstone; 2012:5-23,232-233.
10. Waldman, Steven D. Atlas of Pain Management Injection Technique. 4th Ed. Elsevier: St. Louis, Missouri; 2017:429-432.

Cite this article as: Adipranoto G, Yudistira A. Interobserver reliability on landmark-guided sacroiliac joint injection among 5th year residency in Orthopedic and Traumatology Department faculty of Medicine Brawijaya University Malang, Indonesia. *Int J Res Med Sci* 2019;7:2246-9.