

## Research Article

# Cracking the diagnostic puzzle of tumours of adrenal cortex: a histopathological study

Venugopal Madabhushi\*, Padmavathi Devi Chaganti, Ramya Katta,  
Nageswararao Kakumanu

Department of Pathology, Guntur Medical College, Guntur, Andhra Pradesh, India

**Received:** 13 February 2016

**Accepted:** 10 March 2016

**\*Correspondence:**

Dr. Venugopal Madabhushi,

E-mail: [drmvgopal@yahoo.com](mailto:drmvgopal@yahoo.com)

**Copyright:** © the author(s), publisher and licensee Medip Academy. This is an open-access article distributed under the terms of the Creative Commons Attribution Non-Commercial License, which permits unrestricted non-commercial use, distribution, and reproduction in any medium, provided the original work is properly cited.

### ABSTRACT

**Background:** Primary neoplasms arising in both adrenal cortex and adrenal medulla are rare tumors. Adrenal cortical tumours may be functional or non-functional. They may be found incidentally at the time of autopsy. In many cases adrenal lesions are identified during a radiologic investigation conducted for indications other than an evaluation for adrenal disease. Adrenocortical tumours can be categorized into adenomas and carcinomas, but the distinction becomes difficult in many cases. Several parameters have been applied to establish malignancy in these tumours. Histopathology is still the gold standard in diagnosis of adrenal tumours. This is a retrospective study and was to study the incidence of tumours of adrenal cortex and to assess the role of histopathological criteria and utility of immunohistochemistry in the diagnosis.

**Methods:** Adrenal cortical tumors reported from August, 2008 to August, 2015 in the Department of Pathology, Guntur Medical College, Andhra Pradesh, India are taken for the study. Clinical data including age, sex and symptoms at presentation, are retrieved from the archives. The resected specimens received from Government General Hospital, Guntur, Andhra Pradesh, India are routinely processed and multiple sections stained with Haematoxylin & Eosin are examined. Modified Weiss criteria are applied for all adrenal cortical tumors in the study. Immunohistochemistry is done in relevant cases for confirmation of diagnosis.

**Results:** The observations in the study including clinical presentation, gross and histological features are tabulated.

**Conclusions:** The study highlights the crucial role of histopathological parameters, especially Weiss criteria in identifying malignancy in tumours of adrenal cortex and importance of immunohistochemistry in differential diagnosis.

**Keywords:** Adrenal cortical tumours, Adenoma, Adrenal cortical carcinoma, Weiss criteria, Immunohistochemistry

### INTRODUCTION

The tumours of adrenal cortex may be detected incidentally at autopsy or following radiologic investigations for other reasons. They can be identified clinically because of hormonal dysfunction or a mass effect. Tumours of adrenal cortex tumours can be categorized into adenomas and carcinomas basing on histopathological evaluation, but the distinction becomes difficult in many cases. An accurate diagnosis is

important as the prognosis and therapeutic management for adrenal cortical carcinoma (ACC) and benign tumours vary a lot. However, it is difficult in some cases to distinguish malignant from benign cortical tumours accurately basing on clinical characteristics or histological criteria. Several clinical and histopathologic parameters have been applied by different authors to delineate malignancy in these tumours. Immunohistochemistry is crucial in differentiation of cortical tumours from medullary tumours and

differentiation of adrenal tumours from extraadrenal tumours i.e. metastatic carcinomas or primary carcinomas of kidney or liver or malignant melanoma.

## METHODS

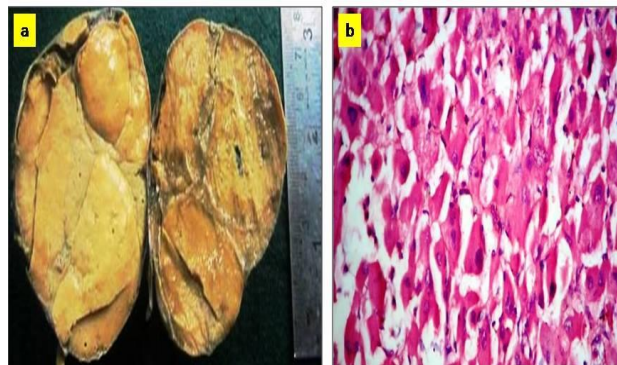
A retrospective study of five cases of adrenal cortical tumours reported during the last five years in the Department of Pathology, Guntur Medical College, Andhra Pradesh, India was carried out. The size and weight of postoperative specimens, received from Government General Hospital Guntur, were recorded. External and serial cut surfaces and tumour capsule were carefully assessed. Paraffin embedded tissue blocks and Haematoxylin & Eosin (H&E) sections were retrieved from the archives in the Department of Pathology and reviewed. Sections of 4 micron thickness were used for routine H&E staining as well as immunohistochemical study.

The adrenal cortical tumours in the study were categorized according to the WHO classification.<sup>1</sup> on the basis of morphological study. Weiss criteria were applied for all the cases.<sup>2</sup> A panel of IHC markers including Inhibin, vimentin, and chromogranin was used for confirmation of diagnoses.

## RESULTS

Of the 10,246 postoperative surgical specimens received during the period of study, ten cases were reported as adrenal tumours with an incidence of 9.76 in 10,000 cases. Of these ten cases, five were diagnosed as cortical

tumours and five as medullary tumours. Female preponderance was observed in the cortical tumours, with women accounting for three cases (60%) while the remaining two cases were seen in men (40%). The tumours were evaluated by gross and microscopic study with application of modified Weiss criteria.



**Figure 1: Oncocytic adenoma; (a) Gross cut surface - capsulated, nodular tumour; (b) Microscopy - oncocytic cells.**

Oncocytic adenoma was the histological diagnosis in one case (Case 1) that occurred in a female patient aged 35yrs. The weight of tumour was 30g and its largest dimension was 5cm (Table 1). Cut surface showed a capsulated, grey brown tumour with nodular configuration (Figure 1a). Microscopy showed proliferation of exclusively oncocytes with granular eosinophilic cytoplasm. But there was no evidence of nuclear atypia or mitotic activity or necrosis (Figure 1b).

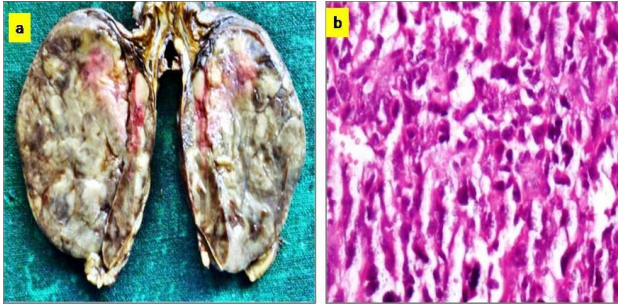
**Table 1: Clinical and gross features of tumors of adrenal cortex.**

Features	Case 1: F 35 year	Case 2: M 35 year	Case 3: F 65 year	Case 4: F 2 year	Case 5: F 22 year
Clinical presentation	abdominal mass	abdominal mass & loss of weight	abdominal mass	precocious puberty clitomegaly	virilization & Cushing syndrome
Tumour size	5x4x2.5cm	13x10x7cm	13x7x4cm	8x7x5cm	12x6x6cm
Tumour weight	30g	500g	314g	120g	310g
Capsule	capsulated	partly capsulated ragged margins	capsulated	capsulated	partly capsulated ragged margins
Cut surface	nodular, grey white & brown	variegated, friable	nodular, grey white/ brown	nodular, grey white/ brown	variegated, , friable
Haemorrhage	absent	present	present	present	present
Necrosis	absent	present	present	present	present

The remaining four cases (Cases no. 2-5) in the study were diagnosed as adrenocortical carcinoma. The age of patients in these cases ranged from 2 years to 65 years, with a sex predilection towards female. The largest diameter of these lesions ranged from 8 cm to 13 cm with an average of 11.62 cm sizes and weights ranged from 120 gm to 500 gm with an average of 288.5g (Table 1).

Gross examination of these four cases showed partly capsulated nodular grey white to grey brown tumour with ragged areas (Figure 2a). Microscopy showed diffuse distribution of tumour cells with eosinophilic cytoplasm and pleomorphic nuclei (Figure 2b). Modified Weiss criteria were applied and basing on the total score obtained, all four cases were diagnosed as adrenocortical

carcinoma (Table 2). High nuclear grade was observed in all the cases (Figure 3a). Necrosis was evident in all four cases of ACC (Figure 3b). Capsular invasion was seen in three cases (Figure 3c). Immunohistochemical study of all cases of ACC showed positivity for vimentin (Figure 4a) inhibin and (Figure 4b) and negativity for chromogranin (Figure 4c).

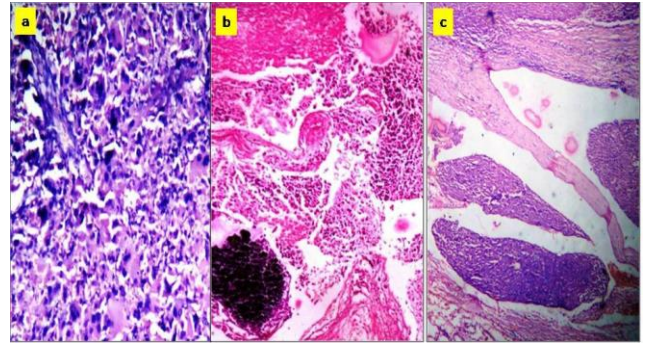


**Figure 2: Adrenocortical carcinoma; (a) Gross cut surface - poorly capsulated tumour with areas of haemorrhage; (b) Microscopy - sheets of cells with pleomorphic nuclei.**

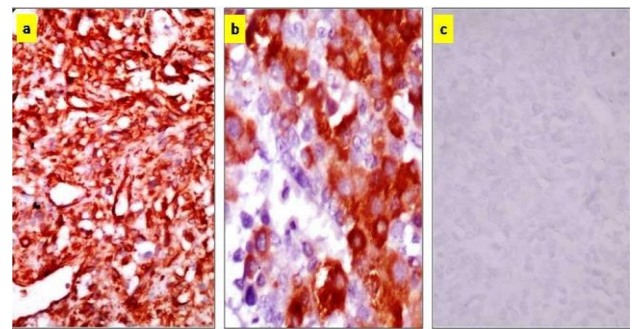
**Table 2: Analysis of Weiss criteria in tumors of adrenal cortex.**

Weiss criteria	Case 1 F 35 y	Case 2 M35 y	Case 3 F 65 y	Case 4 F 2 y	Case 5 F 27 y
Nuclear grade : grade III and IV <sup>3</sup>	1	1	1	1	1
Mitotic rate: >5/50 HPF (40x)	0	1	1	1	1
Atypical mitotic figures	0	0	0	0	1
Cytoplasm: <or equal to 25% clear or vacuolated cells	0	1	0	1	1
Diffuse architecture: >1/3 of tumour with solid sheets of cells	1	0	0	1	1
Confluent necrosis	0	1	1	1	1
Venous invasion	0	0	1	0	0
Sinusoid invasion	0	0	0	0	0
Capsular invasion	0	0	1	1	1
Total score	2	4	5	6	7
Histological diagnosis	AO	ACC	ACC	ACC	ACC

AO: Oncocytic adenoma; y: year; ACC: Adrenal cortical carcinoma.



**Figure 3: Adrenocortical carcinoma - histological features H&E; (a)Nuclear pleomorphism and prominent mitotic activity 40x; (b) Necrosis and calcification 40x; (c) Capsular invasion 10x.**



**Figure 4: Adrenocortical carcinoma - IHC study; (a) Vimentin positivity; (b) Inhibin positivity; (c) Chromogranin negativity.**

**DISCUSSION**

*Clinical presentation of cortical tumours*

Adrenal cortical tumours may be functional or non-functional, but they usually present with cushing syndrome, osteoporosis, diabetes mellitus, hypertension or gonadal dysfunction. Non-functional tumours may be discovered incidentally or as mass lesions or metastatic deposits. Tumours larger than 5-6 cm manifest flank pain or fever due to compression or necrosis. In women virilisation may be the presenting feature due to androgen secretion. Occasionally malignant cortical tumours may induce gynecomastia in men and menorrhagia in women. Three cases of cortical tumours in our study presented as abdominal masses (Case 1-3). One case manifested precocious puberty in a child (Case 4) while virilisation was the clinical presentation in a woman (Case 5).

*Adenoma versus carcinoma*

Tumours of adrenal cortex are potentially malignant and distinction between benign and malignant neoplasms is of crucial importance in planning management protocol. However, histopathological diagnosis of malignancy in cortical tumours poses many challenges to the pathologist. Multiple diagnostic criteria have been

proposed by different workers to discern malignancy in these lesions. A combination of clinical and histopathological parameters were used by Hough et al to distinguish cortical adenoma from carcinoma.<sup>4</sup> Weiss proposed a system for identifying malignancy in cortical tumours based on nine distinct histopathological criteria.<sup>2</sup>

1. Nuclear grade: Grade III and IV based on Furhman criteria.<sup>3</sup>
2. Mitotic rate: >5/50 HPF (x 40objective) by counting 10 random HPF in the area of the greatest numbers of mitotic figures on five slides with greatest number of mitoses.
3. Atypical mitotic figures.
4. Cytoplasm: presence of less than equal to 25% clear or vacuolated cells resembling normal zona fasciculata.
5. Diffuse architecture: If greater than one third of the tumour shows pattern less sheets of cells.
6. Necrosis: confluent necrosis of nest of cells.
7. Venous invasion
8. Sinusoid invasion
9. Invasion of tumour capsule: extension of nests or cords of cells into or through the capsule with stromal reaction.

Each Weiss criterion is scored '0' when absent and '1' when present. Adrenocortical tumours are graded from 0 to 9 basing on total Weiss score. The tumours with three or less criteria are classified as adenomas and those with four or more of these criteria are classified as carcinomas. Van Slooten, et al formulated a histopathologic index basing on seven histopathological parameters to distinguish benign from malignant tumours.<sup>5</sup> The threshold for malignancy was lowered in 1989 and the presence of three or more Weiss criteria was considered sufficient to predict malignancy in cortical tumours.<sup>6</sup> Aubert S proposed a simplified system of Weiss criteria and observed that three or more of the nine criteria indicate carcinoma, whereas two or less would suggest an adenoma.<sup>7</sup> Consistent histological features in various systems include the mitotic rate and the presence of vascular or capsular invasion.

In order to assess oncocytic tumours, Biscegha, et al revised the Weiss system and proposed major and minor criteria to define the terms adrenal oncocytic carcinoma (AOC), adrenal oncocytic neoplasm of unknown malignant potential (AONUMP), and Adrenal oncocytoma (AO).<sup>8</sup> If the oncocytic tumour shows one or more major criteria of 1) a mitotic figure of more than 5 mitoses per 50 high-power fields, 2) any atypical mitosis, or 3) any venous invasion), it is reported as AOC. If one or more minor criteria of 1) large size >10 cm and/or >200 g, 2) confluent necrosis, or 3) capsular invasion or 4) sinusoidal invasion), it is categorized as AONUMP. If none of these features is present, the tumour is diagnosed as AO. In our case (Case 1), none of these criteria were present and so this tumour was reported as oncocytic adenoma.

In the process of establishing adrenocortical malignancy, challenges are encountered in differentiating adrenocortical carcinoma from (1) adrenocortical adenoma (2) renal cell carcinoma; and (3) adrenomedullary tumours. One of the most crucial aspects of diagnosis of cortical tumours is distinguishing adenoma from carcinoma.

Differentiating between adenoma and an early stage adrenocortical carcinoma is extremely difficult basing on histopathological features alone in the absence of capsular or angioinvasion or metastasis. Cortical adenomas usually tend to be smaller, more homogeneous, and lacking hemorrhage and necrosis. Surgical resection is generally considered to be curative for lesions less than 50 gm.<sup>9</sup> However, H.S. Tan suggested that adrenal adenomas measuring >4cm in diameter should be followed up with periodic imaging and hormonal evaluation.<sup>10</sup>

Adrenal cortical carcinoma (ACC) is a rare but aggressive endocrine malignancy accounting for 0.2% of all cancers.<sup>11</sup> It shows bimodal age distribution with first peak in childhood and a second higher peak in the fourth and fifth decades of life.<sup>12</sup>

**Table 3: Histological criteria for malignancy in adrenal cortical tumors.**

Criteria	Weiss system <sup>2</sup>	Aubert's modification <sup>7</sup>
High Nuclear grade : grade III or IV <sup>4</sup>	1	-
Mitotic rate: greater than 5/50 HPF (x 40objective)	1	X2
Atypical mitotic figures	1	1
Cytoplasm: presence of less or equal to 25% clear/vacuolated cells	1	X2
Diffuse architecture >one third of tumour shows pattern less sheets of cells	1	-
Confluent necrosis	1	1
Venous invasion	1	-
Sinusoid invasion	1	-
Invasion of tumour capsule: extension of nests or cords of cells into or through the capsule with stromal reaction.	1	1
Interpretation of total score	Original <3 adenoma >4 carcinoma modified >3 carcinoma	<2 adenoma >3 carcinoma

In the study of Weiss, none of the 24 tumours with two or less of the criteria metastasized or recurred, whereas all but one of the 19 tumours with four or more of the criteria did.<sup>2</sup> The efficacy of this approach was evaluated by independent observers.<sup>7,13</sup> The scheme introduced by Aubert, et al is a statistically modified system based on the most reliable criteria, wherein some of the Weiss criteria are weighted i.e. the score of 1 has to be multiplied by the weighting factor.<sup>7,14</sup> A score of three or more in both systems, i.e. revised Weiss system and Aubert's modified scheme indicates malignant potential (Table 3). Increased mitotic activity with atypical forms and venous invasion have predictive value for recurrence or metastasis.<sup>2,5,15,16</sup> Spindling of the tumour cells also is considered to be highly suggestive of malignancy.<sup>17</sup>

However, these schemes may be difficult to apply in case of adrenocortical tumors occurring in childhood, oncocytic variants and tumours with myxoid features.<sup>8,18,19</sup> Wienke JA proposed an alternative scheme for adrenocortical tumours in paediatric age group.<sup>18</sup> The presence of four or more criteria of tumour weight >400g, tumour size >10.5cm, extension of tumour into periadrenal soft tissue/adjacent organs, invasion into vena cava, venous invasion, capsular invasion, presence of tumour necrosis, >15mitoses/20HPF, and presence of atypical mitotic figures is associated with malignancy.<sup>18</sup>

In the present study, modified Weiss criteria were applied to identify malignancy in the cortical tumours. Four out of five cortical tumours in our study (Cases 2, 3, 4 5) fulfilled three or more modified criteria of malignancy and were diagnosed as ACC. Of these four cases, two tumours (Cases 4 and 5) exhibited six or more criteria. Apart from high nuclear grade which was present in all the four cases, high mitotic rate of >5/50 HPF, eosinophilic tumour cell cytoplasm, necrosis and capsular invasion were the other most frequent criteria seen in our cases. These findings are in accordance with the observation of RV Lloyd who felt that tumour size, necrosis, mitotic activity with atypical mitoses, invasive growth and high nuclear grade are the most useful criteria to separate carcinoma from adenoma.<sup>19</sup>

Immunohistochemical study is imperative in differentiating ACC from adrenal medullary tumours and renal cell carcinoma (RCC) and hepatocellular carcinoma (HCC). Positivity for alfa inhibin and Melan A antibody is sensitive though not specific for ACC.<sup>20,21</sup> Positivity for inhibin is shared by adrenal cortical tumours as well as steroid producing tumours of ovary. Adrenal cortical tumours may show neuroendocrine differentiation and thereby exhibit positivity for synaptophysin and NSE. But in contrast to pheochromocytoma, adrenal cortical tumours are typically negative for chromogranin A and hence this marker is considered the most reliable marker for distinguishing ACC from adrenal medullary tumours.<sup>12</sup> ACC is negative or weakly positive for cytokeratin and negative for epithelial membrane antigen

(EMA) and Carcino embryonic antigen (CEA). But epithelial metastatic deposits to adrenal gland usually show intense cytokeratin immunostaining and positivity for CEA and EMA whereas ACC are negative for these markers.

In our study, all the four cases of adrenocortical carcinomas were positive for inhibin & vimentin. Our results are similar to those obtained by Wick, et al who suggested that vimentin can be used to distinguish between renal cell carcinoma and adrenocortical carcinoma in doubtful cases.<sup>22</sup> Chromogranin was negative in our cases thereby excluding medullary tumours. These observations are in accordance with those of Manoj Jain, et al.<sup>23</sup>

## CONCLUSION

Primary neoplasms arising in adrenal cortex are very rare. It is important to distinguish malignant tumours from benign counterparts to plan appropriate management. Histopathology is still the gold standard for diagnosis of adrenal tumours and our findings are in agreement with the view that methodical application of modified Weiss criteria is crucial in identifying adrenocortical malignancy in correlation with clinical and imaging techniques. Immunohistochemistry is of great value, especially in distinguishing between cortical and medullary tumours and differentiating adrenocortical carcinoma from renal cell carcinoma.

*Funding: No funding sources*

*Conflict of interest: None declared*

*Ethical approval: The study was approved by the Institutional Ethics Committee*

## REFERENCES

1. De Lellis RA, Lloyd RV, Heitz PU. World Health Organization Classification of Tumors. Pathology and Genetics of Tumors of Endocrine Organs. IARC Press: Lyon, France. 2004;137-146.
2. Weiss LM. Comparative histologic study of 43 metastasizing and nonmetastasizing adrenocortical tumors. *Am J Surg Pathol.* 1984;8:163-9.
3. Fuhrman SA, Lasky LC, Limas C. Prognostic significance of morphologic parameters in renal cell carcinoma. *Am J Surg Pathol.* 1982;6:655-63.
4. Hough AJ, Hollifield JW, Page DL. Prognostic factors in adrenal cortical tumors. A mathematical analysis of clinical and morphologic data. *Am J Clin Pathol.* 1979;72:390-9.
5. Van Slooten H, Schaberg A, Smeenk D, Moolenaar AJ. Morphologic characteristics of benign and malignant adrenocortical tumors. *Cancer.* 1985;55:766-73.
6. Weiss LM, Medeiros LJ, Vickery AL. Pathologic features of prognostic significance in adrenocortical carcinoma. *Am J Surg Pathol.* 1989;13:202-6.

7. Aubert S, Wacrenier A, Leroy X, Devos P, Carnaille B, Proye C, et al. Weiss system revisited: a clinicopathologic and immunohistochemical study of 49 adrenocortical tumors. *Am J Surg Pathol.* 2002;26:1612-9.
8. Biscegha M, Ludovico O, Di Mattia A. Adrenal oncocytic tumors: report of 10 cases and review of the literature. *Int J Surg Pathol.* 2004;12:231-43.
9. Gandour MJ, Grizzle WE: A small adrenocortical carcinoma with aggressive behavior. An evaluation of criteria for malignancy. *Arch Pathol Lab Med.* 1986;110:1076-9.
10. HS Tan, AC Thai, ME Nga, JJ Mukherjee. Development of Ipsilateral Adrenocortical Carcinoma Sixteen Years after Resection of an Adrenal Tumour Causing Cushing's Syndrome. *Ann Acad Med Singapore.* 2005;34:271-4.
11. Volante M, Bollito E, Sperone P, Tavaglione V, Daffara F, Porpiglia F, et al: Clinicopathological study of a series of 92 adrenocortical carcinomas: from a proposal of simplified diagnostic algorithm to prognostic stratification. *Histopathology.* 2009;55:535-43.
12. De Lellis RA, Lloyd RV, Heitz PU. World Health Organization Classification of Tumors. Pathology and Genetics of Tumors of Endocrine Organs. IARC Press: Lyon, France. 2004;140-3.
13. Stojadinovic A, Brennan MF, Hoos A, Omeroglu A, Leung DHY, Dudas ME, et al: Adrenocortical adenoma and carcinoma: histopathological and molecular comparative analysis. *Mod Pathol.* 2003;16:742-51.
14. Mufaddal TM, Johnson SJ. Standards and datasets for reporting cancers Cancer dataset for the histological reporting of adrenal cortical carcinoma and pheochromocytoma. PSU 170112 1 V5 Final. 2012: G109:7-9.
15. Evans HL, Vassilopoulou-Sellin R: Adrenal cortical neoplasms. A study of 56 cases. *Am J Clin Pathol.* 1996;105:76-86.
16. Sasano H, Suzuki T, Moriya T: Discerning malignancy in resected adrenocortical neoplasms. *Endocr Pathol.* 2002;12:397-406.
17. Kay S: Hyperplasia and neoplasia of the adrenal gland. *Pathol Annu.* 1976;11:103-39.
18. Wieneke JA, Thompson LD, Heffess CS. Adrenal cortical neoplasm in the pediatric population: a clinicopathologic and immunophenotypic analysis of 83 patients. *Am J Surg Pathol.* 2003;27:867-81.
19. Ricardo V. Lloyd Adrenal cortical tumors, pheochromocytomas and paragangliomas *Modern Pathology.* 2011;24:S58-S65.
20. LM Munro. A Kennedy and AM McNicol. The expression of inhibin/activin subunits in the human adrenal cortex and its tumours. *J Endocrinol.* 1999;161:341-67.
21. Busam KJ, Iversen K, Coplan KA, Old LJ, Stockert E, Chen YT, et al: Immunoreactivity for A103, an antibody to melan-A (Mart-1), in adrenocortical and other steroid tumors. *Am J Surg Pathol.* 1998;22:57-63.
22. Wick MR, Cherwitz DL, McGlennen RC, Dehner LP. Adrenocortical carcinoma. An immunohistochemical comparison with renal cell carcinoma *Am J Pathol.* 1986;122(2):343-52.
23. Jain M, Kapoor S, Mishra A, Gupta S, Agarwal A. Weiss criteria in large adrenocortical tumors: a validation study. *Indian J Pathol Micobiol.* 2010;53:222-6.

**Cite this article as:** Madabhushi V, Chaganti PD, Katta R, Kakumanu N. Cracking the diagnostic puzzle of tumours of adrenal cortex: a histopathological study. *Int J Res Med Sci* 2016;4:1242-7.