

Original Research Article

Neovascularization: topical effects of *streptococcus thermophilus* and low level laser therapy in treatment of diabetic wound in rats

Devi Kumari^{1*}, Hina Khan¹, Asad R. Jiskani², Muhammad Rafique¹, Muhammad Asif³,
Vijay Kumar⁴, Syed Maqsood²

¹Department of Anatomy, Al-Tibri Medical College and Hospital, Karachi, Sindh, Pakistan

²Department of Community Medicine, Al-Tibri Medical College and Hospital, Karachi, Sindh, Pakistan

³Principal, Isra Institute of Rehabilitation Sciences. Karachi, Sindh, Pakistan

⁴Department of ENT, Civil Hospital, Dow Institute of Health Sciences. Karachi, Sindh, Pakistan.

Received: 14 June 2019

Revised: 15 July 2019

Accepted: 20 July 2019

*Correspondence:

Dr. Devi Kumari,

E-mail: devijaykhatr@gmail.com

Copyright: © the author(s), publisher and licensee Medip Academy. This is an open-access article distributed under the terms of the Creative Commons Attribution Non-Commercial License, which permits unrestricted non-commercial use, distribution, and reproduction in any medium, provided the original work is properly cited.

ABSTRACT

Background: Diabetic wound is a major socioeconomic debilitating problem in this society. Various treatment options are available but still it requires better treatment option. In diabetes mellitus the oxygenation to the tissues is reduced. In this study effects of low level laser therapy were compared with topical application of *Streptococcus thermophilus* on diabetic wounds that induces formation of new blood vessel and free radical scavenging system, a comparative study to get better treatment option for diabetic wounds.

Methods: 18 male rats were selected and divided randomly into three groups. Diabetes was induced in all the rats by using the Alloxan monohydrate at a dose of 120mg/kg of the body weight. Group A was treated with normal saline, group B was treated with low level laser therapy and group C was treated with *Streptococcus thermophilus* topically. Skin tissues were collected on day three and seven, slides were prepared for microscopic examination to observe the new blood vessels formation.

Results: Mean number of new blood vessel formation was observed in group B compared with group A and C. Significant vasculogenesis was seen in group B when treated with Low level laser therapy.

Conclusions: In the group of low level laser therapy new blood vessel formation was seen with better wound healing. It means LLLT provides better oxygenation to the tissues by generation of new blood vessels compared with *Streptococcus thermophilus* and normal saline.

Keywords: Blood vessels, Diabetic Wound, Low level laser therapy (LLLT), *Streptococcus thermophilus*

INTRODUCTION

The prevalence rate of diabetic complications like peripheral vascular disease is 5.4%, diabetic retinopathy is 15.9%, neuropathy is 48.8% and nephropathy is 31%. 4% of diabetic patients are suffering from diabetic wound that is in Pakistan around 1.08 million persons affected by diabetic wound.¹ Chronic non-healing wounds are

major issues in this society and its increasing burden also affects the socioeconomic status of population.² From starting till the end, the role of neovascularization is very important in wound healing process.³ Many conditions like venous insufficiency, arteriosclerotic diseases or diabetes can affect the process of neovascularization resulting in impaired wound healing or chronic wound.⁴ Diabetes mellitus is designated by abnormally raised

blood sugar owing to inadequate insulin secretion or function and resistance to insulin. When the diabetes mellitus is not treated for long time this affects the different parts of body especially eyes, kidneys, blood vessels.⁵ In diabetes the activity of new blood vessel formation is diminished and it is one of the reasons of delayed wound healing in diabetics.⁶ LLLT has been used since many years for wound healing but still questioned in its effectiveness.⁷

Wavelength, energy, power and its duration are the different parameters of Low level laser therapy. According to the different conditions the multiple exposures of laser therapy, its frequency and duration is settled. There are many laser systems available like He-Ne, AlGaAs etc.⁸ LLLT is a non-invasive therapy and gives good results in wound healing. It has no influence on temperature of body, so that it doesn't hinder the healing process but helps in tissue repair and ultimately relieves pain. It also increases new blood vessels formation hence enhances wound healing. In addition to this it also promotes the production of collagen and fibroblasts.⁹ Treatment of wound in diabetic rats at 633nm laser at 10j/cm² showed good results.¹⁰

Due to increase use of antibiotics the people become more resistant towards those antibiotics. According to the WHO the threat of antibiotic resistance raised globally and it is necessary to choose selective therapy which is cost effective and use of those antibiotics which minimize the drug toxicity. Limiting the unnecessary use of antibiotics can improve the resistance.¹¹

Probiotics can be categorized in different forms like foods and also in the form of dietary supplements and pharmaceuticals.¹² *Streptococcus*, *lactobacillus* and *leuconostoc* are lactic acid producing bacteria and these are chiefly found in fermented product of foods. Not only bacteria but also fermented foods comprised of yeast and fungi species.¹³

It acts as an anti-inflammatory agent and helps to improve inflammatory conditions. *Streptococcus thermophilus* reduce the production of reactive oxygen species and function as antioxidant. Due to reduction in the production of reactive oxygen species *Streptococcus thermophilus* prevent the tissue from its damaging effects.¹⁴

METHODS

Wistar albino rats bought from animal house of Al-Tibri Medical College and Hospital, Karachi. All selected rats were male, fed with libitum diet water and placed in normal room temperature.

This study was held in accordance with the guidelines on animal care and with the approval of the Ethical Committee of Isra University Karachi Campus.

Diabetic rats model

Diabetes was induced in all rats by single dose of intraperitoneal injection of Alloxan monohydrate (Sigma, Germany). All rats were kept on fasting for 24 hours and Alloxan 120mg/kg was diluted in chilled normal saline was injected in all rats. After 72 hours the RBS was checked to confirm the diabetes. More than 200mg/dl of RBS was taken as diabetic criteria.¹⁵

Animal design and treatment

Total 18 albino rats were randomly divided into three groups. Group A was treated with normal saline topically. Group B was treated with *Streptococcus thermophilus* topically. The dose of probiotics used in this study was 10¹⁰ to 10¹¹ CFU/ml bacteria.

In the microbiology department the *Streptococcus thermophilus* strains were isolated from yogurt and authenticated from the PCSIR Karachi. Third group was Group C treated with low level laser therapy at a dose of 10J/cm² for 30 seconds. Laser machine (THOR DDII laser device) was taken from the Isra institute of Rehabilitation Sciences, Karachi.

Creation of wound and microscopic examination

Rats were anesthetized by ethanol, dorsal surface of rats were cleaned and shaved. Wound was created by using surgical blade at a size of 2.5×2.5 cm. Then rats were placed in their separate labelled cages. The treatment was started after 24 hours of creation of wound in all three groups. All rats were treated topically once daily. After 3 days of treatment the scab and granulation tissue was checked and its full thickness sample was collected by scalper knife and fixed in 10% formalin solution.

It was dehydrated in ascending order of alcohol and cleared by xylene solution. It was embedded by paraffin wax and was cut down into 5 μm sections by rotatory microtome and sections were fixed on albumenized glass slides after Haematoxylin and eosin (H and E) staining.

After preparing the slides on day three and seven, formation of new blood vessels were observed and counted under microscope at the magnification of x400. Blood vessels were counted by the help of reticule, for that 5 boxes were selected and blood vessels were identified and counted in the field area of 0.81 cm².

Statistical analysis

For Statistical Analysis software statistical package for social sciences (SPSS) version 23.0 was used. To compare the multiple groups ANOVA used which was followed by Post-hoc Tukey test for multiple comparisons. The values were expressed in mean±sd. p≤0.05 considered to be Statistical significance.

RESULTS

Mean RBS value of all rats was checked by glucometer on every third day after injection of Alloxan monohydrate

for consecutive 15 days. To check the diabetic status of rats RBS was checked on 3rd and 7th day of experiment as shown in table 1.

Table 1: Showing mean value of RBS for 15 days at three days of interval in group A, B and C also showing value of RBS on 3rd and 7th day of experiment.

No: of Days	Group A	Group B	Group C
Day (3)	290±19.690	350±18.680	285±19.680
Day (6)	300.75±20.07	320.75±19.08	280.75±14.08
Day (9)	345±19.08	329±13.09	320±14.09
Day (12)	319±33.0	329±12.9	295±13.76
Day (15)	290±13.9	295±16.7	370±25.7
Day 3 rd of treatment	350±17.690	295±13.68	370±17.6
Day 7 th of treatment	321.75±19.07	370.75±13.05	288.75±18.04

Comparison new blood vessel formation in Group A with B

Number of blood vessels under (x400) were observed and mean±SD of group A(1) was 2.6625±0.63682, A(2) 4.1875±0.24749. In B(1) was 10.5125±0.20310, B(2) 13.9375±0.27223. A statistically significant difference was observed with p value of A(1) vs B(1) (p=0.03), A(2) vs B(2) (p=0.03). Results showed significant increase in no: of new blood vessel formation in Group B in comparison with group A as shown in figure 1 and figure 2 and 3.

On day 3 the p value between group A vs B was 0.03, group A vs C was 0.01, group B vs C was 0.03. On day 7 the p value between group A vs B was 0.03, group A vs C was 0.02, group B vs C was 0.02. p value <0.05 considered as significant.

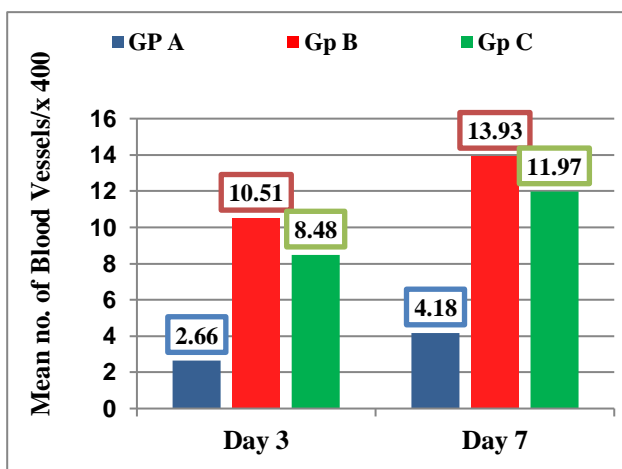


Figure 1: Bar chart showing comparison of number of blood vessels between A, B and C Groups on 3rd and 7th day of treatment.

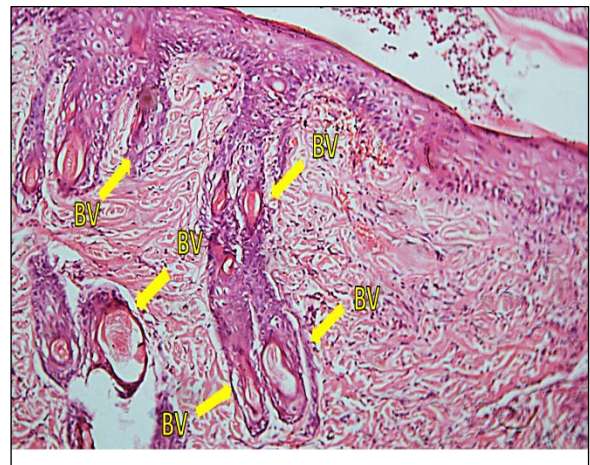

Figure 2: Bar chart showing comparison of number of blood vessels between A, B and C Groups on 3rd and 7th day of treatment.

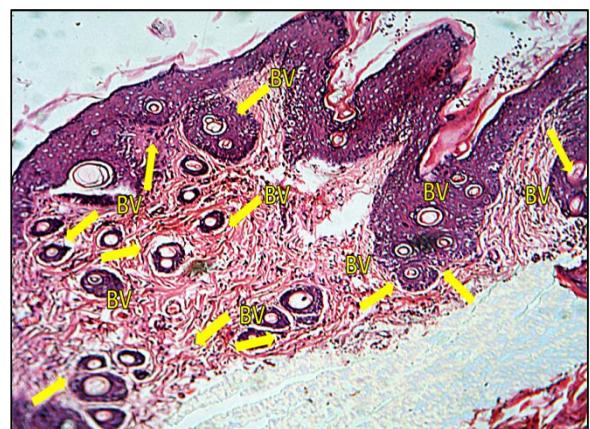

Figure 3: Bar chart showing comparison of number of blood vessels between A, B and C Groups on 3rd and 7th day of treatment.

Comparison new blood vessel formation in Group A with C

Number of blood vessels under (x400) were observed and mean±SD of group A(1) was 2.6625±0.63682, A(2) 4.1875±0.24749. In C(1) was 8.4875±0.19594, C(2) 11.9750±0.31053. A statistically significant difference was observed with p value of A(1) vs C(1) (p=0.01), A(2) vs C(2) (p=0.02). Results showed significant increase in no: of new blood vessel formation in Group C in comparison with group A as shown in figure 1 and figure 2 and 4.

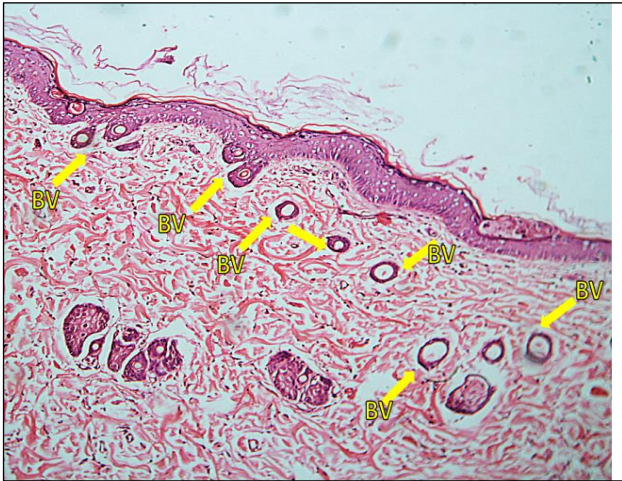

Figure 4: Skin tissue (H&E staining) showing decrease number of blood vessels in group C (Streptococcus Thermophilus) (BV-Blood Vessels).

Comparison new blood vessel formation in Group B with C

Number of blood vessels under (x400) were observed and mean±SD of group B(1) was 10.5125±0.20310, B(2) 13.9375±0.27223. In C(1) was 8.4875±0.19594, C(2) 11.9750±0.31053. A statistically significant difference was observed with p value of B(1) vs C(1) (p=0.03), B(2) vs C(2) (p=0.02). Results showed significant increase in no: of new blood vessel formation in Group B in comparison with group C as shown in figure 1 and figure 3 and 4.

DISCUSSION

In diabetes mellitus the wound healing is slow because of multiple factors which hinder the healing process for example, in diabetes the vascular supply is compromised and for wound healing good vascular supply is required. Also, high blood sugar causes disruption in cellular growth. One of the recent studies showed that LLLT has beneficial effects in healing diabetic foot ulcers in humans. Similar results were observed that LLLT showed better healing in diabetic rats as well.¹⁶

Angiogenesis is very important for good healing process because it provides good vascular supply, oxygenation and

nutrients to the growing tissue. One recent study described that LLLT prevents endothelial dysfunction produced by inflammatory mediators and increase the availability of new endothelial cells which helps in increase the formation of new blood vessels. In present study it was noticed that after treated with LLLT the tissue was more vascular with more blood vessels formation.¹⁷

In accordance with Xu et al., in 2018 LLLT supplies better oxygenation to the tissues by enhancing the release of oxygen from oxy-hemoglobin and increase the healing process. He also explained that by applying the low laser provides better results in burn injury and hair growth.¹⁸ According to the present study it was noticed that LLLT treated group showed formation of new blood vessel with good vascular supply to healing tissue when compared with *Streptococcus thermophilus* and normal saline treated group.

One of the recent studies shows that *Streptococcus thermophilus* provides protection against oxidative stress caused by peroxidases in the intestinal mucosa of humans. In comparison with the present study it was observed that *Streptococcus thermophilus* when applied topically on diabetic wound provides beneficial effects in diabetic rats. In diabetics the oxidative stress is high as compared to normal individuals. *Streptococcus thermophilus* reduces the oxidative stress and enhances the healing process.¹⁹ Another study, which used probiotics for healing of gastric ulcers showed increased neovascularization by enhancing the up-regulation of vascular endothelial growth factors.²⁰

LLLT enhances the cell proliferation by inducing the synthesis of collagen fibers. According to the Martignago, 2015 showed that LLLT induces the gene which regulates the synthesis of collagen and also it induces the vascular endothelial growth factor which regulates the formation of blood vessels. In present study similar events occur in diabetic wound when treated with laser therapy inducing more blood vessels and more collagen formation compared with normal saline treated rats.²¹

CONCLUSION

In this study it was concluded that topical treatment of Low level laser therapy showed significant increase in number of blood vessels and showed better healing effects than *Streptococcus thermophilus* and normal saline.

ACKNOWLEDGEMENTS

I want to thank my Prof. Dr. Muhammad Rafique for their support, guidance and supervision in every step of research and Dr. Hina Khan for her supervision in my research work. Thanks to Prof. Dr. Muhammad Asif for his contribution in providing the laser machine from their resources. I would like to thank Dr. Vijay Kumar in critical Appraisal and Dr. Asad Raza Jiiskani and Prof. Dr. Syed Maqsood for their support in data analysis. I want to thanks for my Technical team members, who gave their technical support Mr.

Younus and Mr. Sohail and my institute who gave me full support in my whole research work.

Funding: No funding sources

Conflict of interest: None declared

Ethical approval: The study was approved by the Institutional Ethics Committee

REFERENCES

- Basit A, Fawwad A, Siddiqui SA, Baqa K. Current management strategies to target the increasing incidence of diabetes within Pakistan. *Diab, Metab Syndr Obes: Targ Ther.* 2019;12:85.
- Augustin M, Brocatti LK, Rustenbach SJ, Schäufer I, Herberger K. Cost-of illness of leg ulcers in the community. *Int Wound J.* 2014;11(3):283-292.
- King A, Balaji S, Keswani SG, Crombleholme TM. The role of stem cells in wound angiogenesis. *Adv Wound Care (New Rochelle).* 2014;3(10):614-25.
- Davis FM, Kimball A, Boniakowski A, Gallagher K. Dysfunctional Wound Healing in Diabetic Foot Ulcers: New Crossroads. *J Cur Diab Reports.* 2018;18(2):1-8.
- Diagnosis and Classification of Diabetes Mellitus. American Diabetes Association. *Diabetes care.* 2013;36(1):67-74.
- Seo E, Lim JS, Jun JB, Choi W, Hong IS, Jun HS. Exendin-4 in combination with adipose-derived stem cells promotes angiogenesis and improves diabetic wound healing. *J Transl Med.* 2017;15(35):1145-4.
- Rocha Júnior AM, Vieira BJ, Andrade LC, Aarestrup FM. Effects of low-level laser therapy on the progress of wound healing in humans: the contribution of in vitro and in vivo experimental studies. *J Vasc Bras.* 2007 Sep;6(3):257-65.
- Calin MA, Coman T, Calin MR. The effect of low level laser therapy on surgical wound healing. *Romanian Reports Physics.* 2010;62(3):617-27.
- Dungel P, Hartinger J, Chaudary S, Slezak P, Hofmann A, Hausner T, et al. Low level light therapy by LED of different wavelength induces angiogenesis and improves ischemic wound healing. *Lasers Surg Med.* 2014 Dec;46(10):773-80.
- Beckmann KH, Meyer-Hamme G, Schröder S. Low level laser therapy for the treatment of diabetic foot ulcers: a critical survey. *Evidence-Based Complement Altern Med.* 2014:1-9.
- Brauer R, Ruigómez A, Downey G, Bate A, Garcia Rodriguez LA, Huerta C, et al. Prevalence of antibiotic use: a comparison across various European health care data sources. *Pharmacoepidemiol Drug Safety.* 2016 Mar;25:11-20.
- Sanders ME, Merenstein D, Merrifield CA, Hutkins R. Probiotics for human use. *J Nutrition Bulletin.* 2018;43(3):212-25.
- Slashinski MJ, McCurdy SA, Achenbaum LS, Whitney SN, McGuire AL. Snake oil, quack medicine, and industrially cultured organisms: Biovalue and the commercialization of human microbiome research. *BMC Med Ethics.* 2012;13(28):1-8.
- Li S, Shah NP. Characterization, Anti-Inflammatory and Antiproliferative Activities of Natural and Sulfonated Exo-Polysaccharides from *Streptococcus thermophilus* ASCC 1275. *J Food Sci.* 2016 May;81(5):M1167-76.
- Hamzah RU, Lawal AR, Madaki FM, Erukainure OL. Methanolic extract of *Celosia argentea* var. *crista* leaves modulates glucose homeostasis and abates oxidative hepatic injury in diabetic rats. *Compar Clin Pathol.* 2018 Jul 1;27(4):1065-1071.
- Kajagar BM, Godhi AS, Pandit A, Khatri S. Efficacy of low level laser therapy on wound healing in patients with chronic diabetic foot ulcers- a randomised control trial. *Ind J Surg.* 2012;74(5):359-63.
- Chu YH, Chen SY, Hsieh YL, Teng YH, Cheng YJ. Low-level laser therapy prevents endothelial cells from TNF- α /cycloheximide-induced apoptosis. *Lasers Med Sci.* 2018;33(2):279-86.
- Xu Y, Lin Y, Gao S, Shen J. Study on mechanism of release oxygen by photo-excited hemoglobin in low-level laser therapy. *Lasers Medical Sci.* 2018;33(1):135-9.
- Wang Y, Li H, Li T, He H, Du X, Zhang X, et al. Cytoprotective effect of *Streptococcus thermophilus* against oxidative stress mediated by a novel peroxidase (EfeB). *J Dairy Sci.* 2018;101(8):6955-63.
- Dharmani P, De Simone C, Chadee K. The probiotic mixture VSL# 3 accelerates gastric ulcer healing by stimulating vascular endothelial growth factor. *PLoS One.* 2013 Mar 6;8(3):e58671.
- Martignago CC, Oliveira RF, Pires-Oliveira DA, Oliveira PD, Soares CP, Monzani PS, et al. Effect of low-level laser therapy on the gene expression of collagen and vascular endothelial growth factor in a culture of fibroblast cells in mice. *Lasers Medical Sci.* 2015;30(1):203-8.

Cite this article as: Kumari D, Khan H, Jiskani AR, Rafique M, Asif M, Kumar V, et al. Neovascularization: topical effects of *streptococcus thermophilus* and low level laser therapy in treatment of diabetic wound in rats. *Int J Res Med Sci* 2019;7:3357-61.