

## Case Report

# Next generation sequencing in early diagnosis of pneumocystis jirovecii pneumonia after chemotherapy: a case report

Donghua Zheng<sup>1</sup>, Kai Chen<sup>2</sup>, Fang Xiao<sup>1</sup>, Na Liu<sup>1\*</sup>

<sup>1</sup>Department of Critical Care Medicine, <sup>2</sup>Department of Oncology, The First Affiliated Hospital, Sun Yat-sen University, Guangzhou, Guangdong, China

**Received:** 22 June 2019

**Revised:** 21 July 2019

**Accepted:** 30 July 2019

### \*Correspondence:

Dr. Na Liu,

E-mail: liunana001@163.com

**Copyright:** © the author(s), publisher and licensee Medip Academy. This is an open-access article distributed under the terms of the Creative Commons Attribution Non-Commercial License, which permits unrestricted non-commercial use, distribution, and reproduction in any medium, provided the original work is properly cited.

### ABSTRACT

The incidence of Pneumocystis pneumonia is increasing in immunosuppressive patients. How to diagnose and treat Pneumocystis pneumonia in the early stage has become an important issue for clinicians. The development of Next-generation Sequencing (NGS) provides technical support for the diagnosis of Pneumocystis pneumonia. Case report: A 14-year-old male patient was diagnosed with T lymphoblastoma and treated with chemotherapy. After chemotherapy, the patient developed bone marrow suppression and was complicated with severe pneumonia. He was given endotracheal intubation and ventilator assisted respiration. Samples of patients' alveolar lavage fluid were obtained, and Next-generation Sequencing (NGS) was used for diagnosis, confirming the pathogen as Pneumocystis jirovecii, which was treated by TMP/SMX. The patient's condition gradually improved, and was finally removed from ventilator and endotracheal tube. Pneumocystis jirovecii is a common opportunistic pathogen in immunosuppressive patients, and Next-generation Sequencing (NGS) can be used for rapid diagnosis of Pneumocystis pneumonia, thus improving the clinical therapeutic effect.

**Keywords:** Acute respiratory distress syndrome, Early diagnosis, Next-generation Sequencing, Patient in critical conditions, Pneumocystis jirovecii

## INTRODUCTION

Pneumocystis pneumonia (PCP) is caused by Pneumocystis jirovecii (Pj), a parasite in human's lung which spreads among human through respiratory tract secretions. In case of host immune suppression, Pj would multiply in alveoli, thickening the breathing membrane and causing interstitial pneumonia as a result of pulmonary ventilation dysfunction.<sup>1</sup> Common clinical manifestations include low fever, cough and progressive dyspnea, none of which is specific. PCP is still fatal to patients with immunodeficiency or organ transplantation, making its diagnosis crucial in clinical practices.<sup>2</sup>

Next-generation Sequencing (NGS) is developing rapidly at present, and commercial instruments and reagents have already been put into clinical practice, especially in the diagnosis of specific pathogens.<sup>3</sup> NGS can generally confirm pathogens within 48 hours after obtaining specimens, not only shortening the time for diagnosis but also featuring greater accuracy in the diagnosis of special viruses, pneumocystis, chlamydia and mycoplasma.<sup>4</sup>

Currently, there have been some reports on the diagnosis of AIDS-related pneumocystis pneumoniae by NGS, but there are few reports on the diagnosis of pneumonia after tumor chemotherapy.<sup>5</sup> In this paper, authors reported a case of severe pneumonia, who was admitted into ICU

after lymphoma chemotherapy. NGS rapidly diagnosed pneumocystis pneumoniae, rescuing the patient.

**CASE REPORT**

**History**

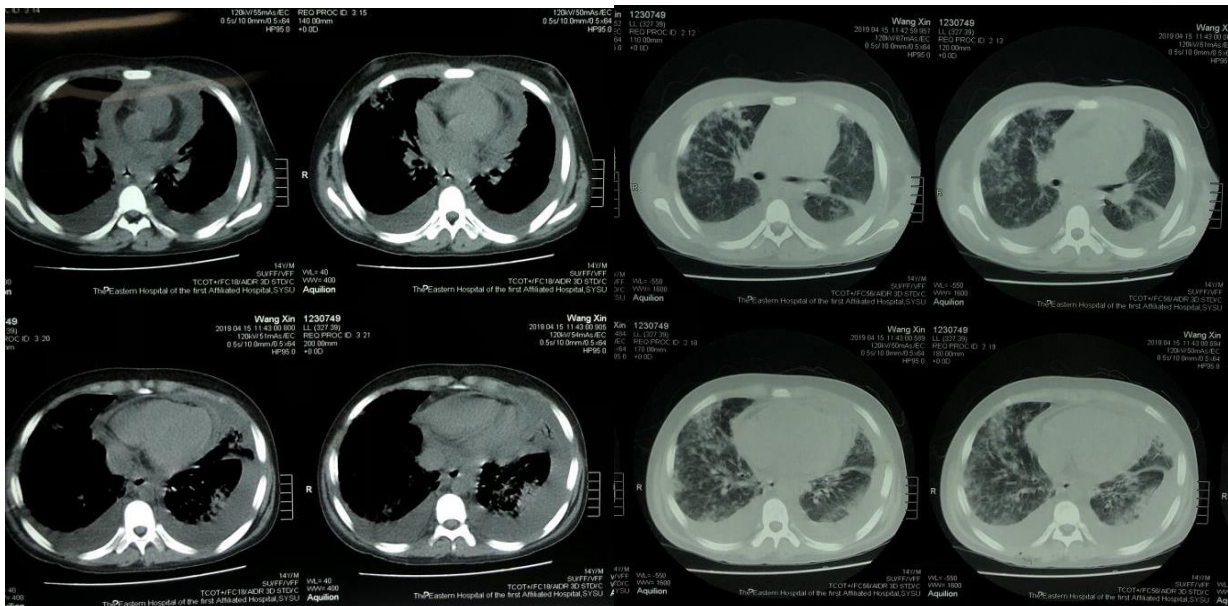
The patient is 14 years old, male, and was admitted into the Department of Oncology of the First Affiliated Hospital of Sun Yat-sen University on April 15, 2019 because of "T lymphoblastoma chemotherapy dyspnea with fever for 1 day".

After being given anti-infection treatment, the patient showed increases in dyspnea and decreases in blood oxygen saturation with an oxygenation index of only 98.

Considering the possibility of acute respiratory distress syndrome (ARDS), Authors transferred him to ICU.<sup>6</sup>

**Physical Examination**

The patient was in a conscious state and short of breath, with a respiratory rate of 45 beats/min, blood oxygen saturation fluctuating between 80% and 93%, heart rate between 128 and 145 beats/min, blood pressure 101/48mmHg and moist rales found in both lungs. The abdomen was soft without obvious tenderness or rebound tenderness. Limb activity was normal. On the day of admission to ICU, CT image showed a large amount of inflammation exudation in both lungs with interstitial pneumonia changes, left pleural effusion as well as pericardial effusion, as shown in Figure 1.



**Figure 1: Chest CT when admitted to ICU.**

**Table 1: Pathogen Test under NGS.**

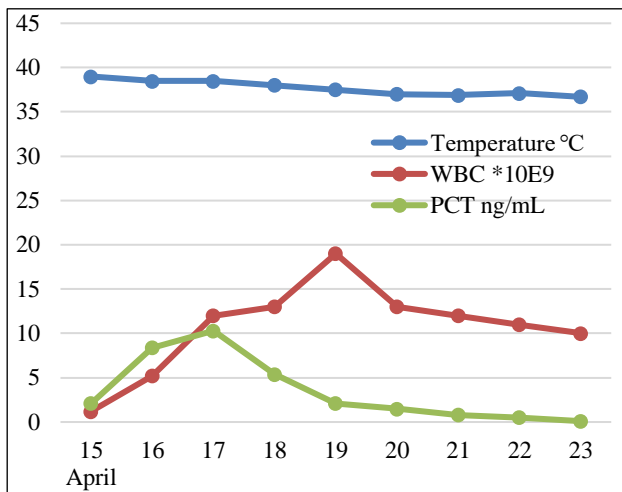
| List of Fungi                      |                    |                        |                        |            |                      |
|------------------------------------|--------------------|------------------------|------------------------|------------|----------------------|
| Generic Name                       | Relative Abundance | Sequence Number Tested | Specific Name          | Confidence | Sequence Number Test |
| Pneumocystis                       | 98.56%             | 107                    | Pneumocystis jirovecii | 99%        | 107                  |
| List of Bacteria                   |                    |                        |                        |            |                      |
| Undetected                         |                    |                        |                        |            |                      |
| List of Virus                      |                    |                        |                        |            |                      |
| DNA Virus                          |                    | RNA Virus              |                        |            |                      |
| Undetected                         |                    |                        |                        |            |                      |
| List of Parasites                  |                    |                        |                        |            |                      |
| Undetected                         |                    |                        |                        |            |                      |
| List of Mycobacterium Tuberculosis |                    |                        |                        |            |                      |
| Undetected                         |                    |                        |                        |            |                      |
| List of Mycoplasma/Chlamydia       |                    |                        |                        |            |                      |
| Undetected                         |                    |                        |                        |            |                      |

**Table 2: Other indicators during Treatment.**

| Date (April)      | 15  | 16  | 17   | 18   | 19   | 20  | 21   | 22   |
|-------------------|-----|-----|------|------|------|-----|------|------|
| Oxygenation Index | 98  | 90  | 158  | 169  | 243  | 260 | 280  | 276  |
| Cr (umol/L)       | 42  | 38  | 56   | 55   | 44   | 55  | 47   | 53   |
| Tbil (umol/L)     | 9.1 | 9.2 | 12.9 | 13.7 | 13.9 | 8.8 | 15.4 | 10.7 |
| ALT(U/L)          | 20  | 25  | 32   | 31   | 29   | 33  | 25   | 32   |
| ALB(g/L)          | 24  | 26  | 29   | 30   | 35   | 34  | 37   | 40   |
| PLT(10E/L)        | 109 | 123 | 130  | 221  | 207  | 326 | 482  | 600  |
| HB(g/L)           | 84  | 85  | 78   | 78   | 85   | 80  | 104  | 116  |

### Treatment

After admission to ICU, meropenem, linezolid and carbaphane were given for anti-infection treatment. At the same time, endotracheal intubation, ventilator assisted respiration, phlegm reduction, backslapping and sputum aspiration, fiber bronchoscope sputum aspiration, alveolar lavage, nutritional support, WBC increase and other treatments were performed. On April 15, NGS of alveolar lavage fluid was delivered to detect pathogens. The result of pathogenic NGS on April 17 suggested that the detected sequence number of pneumocystis Hermogenes was 107, which had important diagnostic significance (Table 1), and TMP/SMX anti-infection treatment was immediately given.<sup>7</sup>



**Figure 2: Infection indicator trends during treatment.**

After these treatments, authors established the infection trend of the patient as shown in Figure 2 along with other related indicators in Table 2. Chest CT examination was conducted on April 22 (Figure 3), indicating significant absorption and decrease of double pneumonia compared with before. Left pleural effusion and pericardial effusion were partially absorbed and decreased, while the right pleural effusion was basically absorbed. On April 22, endotracheal intubation was removed, and atomization inhalation and sputum reduction were given (Figure 4). On April 24, the patient's condition was stable and was

transferred back to the Oncology Department for further treatment. He was discharged after 5 days of Oncology treatment.

### DISCUSSION

*Pneumocystis jirovecii* infects the host, resulting in colonization without external symptoms or existing infections with obvious symptoms. In most cases, Pj is cleared by the host, and in a few cases, the host develops PCP and die.<sup>8</sup> *Pneumocystis* are widely colonized in the lungs of mammals such as humans, mice, cats, dogs, rabbits, pigs and horses, and have relatively strict host species specificity. *Pneumocystis Carinii* (Pc) only infects rats, while Pj targets specifically humans.<sup>14</sup> The mortality rate of PCP varies among different populations. In AIDS groups, due to the wide application of antiviral therapy and anti-PCP preventive drugs, the mortality rate of PCP has significantly decreased to 10%-20%.<sup>9</sup> Due to the increase of organ transplantation, anti-tumor necrosis factor and other immunosuppressive drugs, the incidence of PCP in patients with hematologic diseases, tumors and rheumatoid arthritis has an increasing trend every year. Therefore, non-HIV PCP has received increasing attention from clinicians.<sup>10</sup>

PCP in non-HIV/AIDS patients is often accompanied by fever, dry cough and dyspnea, with a very high fatality rate. In HIV/AIDS patients, PCP is often insidious, and prodrome can last for 3 to 8 weeks. Symptoms include dry cough, low fever, loss of appetite, lethargy, shortness of breath, and cyanosis, usually without abnormality in lung auscultation. Acute dyspnea with chest pain is often associated with pneumothorax. There are patients who experienced disease progression within 3 to 7 days. The disease is typically characterized by signs that are often disproportionate to severity. In physical examination, different degrees of respiratory difficulties are found in addition to immune suppression and a variety of skin manifestations, such as infectious soft warts, skin erysias, Kaposi sarcoma (KS), etc. Patients with a history of HIV, regardless of the presence of respiratory and thoracic symptoms, should be highly suspected of infection and undergo X-ray and serological examination.<sup>11</sup> It is difficult to diagnose PCP clinically, especially when authors have not confirmed if the patient has been

infected with HIV. HIV test should be conducted immediately to confirm the diagnosis when needed.<sup>12</sup> Therefore, PCP is often the forerunner of HIV infection, and a large number of HIV patients are diagnosed because of PCP treatment.

X-ray shows no significant symptoms at the early stage, but as the disease progresses, diffuse interstitial infiltration of the pulmonary hilum could be seen, and PCP could progress within 2 to 3 days, showing significant cystic vacuoles, interstitial infiltration, small nodules, mediastinal lymph node enlargement, and even tubercul-like exudation of the pulmonary apex. Serum lactate dehydrogenase (LDH), C-reactive protein, (1-3)  $\beta$ -D glucan, S-adenosine methionine and other indicators can also be used as PCP reference indicators, but the diagnostic specificity and sensitivity need to be improved. In future researches, the search for better serum prognostic indicators and the combination of these serum indicators with imaging, PCR, biopsy would have significant values for the diagnosis and prognosis of PCP.<sup>13</sup>

When this patient was admitted to ICU, the pathogen was not clear and there was no clear target for anti-infection. The results of conventional microbial culture can only be obtained 3 to 7 days later. In addition, Pj may not be successfully cultivated in conventional culture dishes, which means the positive rate is low (30%-40%). In this case, it is likely to delay treatment. Conventional diagnostic methods have defects such as low sensitivity, inefficiency, inaccuracy and incomplete information, and often fail to identify clinically unknown or rare pathogens.<sup>15</sup> Therefore, a rapid, accurate and economical method is urgently needed to simultaneously identify various clinical pathogens.

Next-generation Sequencing Technology (NGS), also known as Second-generation Sequencing Technology, has been quite mature now after rapid development over the past decade. Thus, pathogens can be identified directly by sequencing without cultivation and grouping before detection, featuring fast detection, high accuracy and wide coverage. It is an efficient tool and increasingly applied in clinical practices.<sup>16</sup> Next-generation Sequencing Technology mainly involves connection with genomic DNA fragments for sequencing via a universal connector, followed by application of different methods to generate tens of millions of single molecular cloning PCR array. And then a large scale of primer hybrid extension and enzyme reaction is triggered, which could take place in hundreds of thousands or even millions of sequences simultaneously, while signals produced by each step after the reaction could be detected, allowing computer analysis for the complete DNA sequences.<sup>17</sup> In addition, it can also perform unbiased analysis of plasma free DNA in the blood of patients with sepsis combined with bloodstream infection, which has proved useful for the diagnosis of bloodstream infection. Authors took alveolar lavage fluid under fiberoptic bronchoscope as samples, which could be diagnosed rapidly within 48 hours under NGS technology. Therefore, patients who

received TMP/SMX timely recovered from infections significantly after targeted anti-infection treatment (Figure 2). This case highlights the advantages of NGS in diagnosing specific pathogens.

Out of 13 cases of pneumocystis identified by NGS. For patients confirmed with pneumocystis pneumonia by clinical evaluation, there were only 4 positive Wright - Giemsa staining out of 8 cases of alveolar lavage fluid specimens, and only 1 positive sputum out of 13 patients under microscopic examination.<sup>18</sup> The researchers argued that compared with conventional methods, the positive rate of NGS in the diagnosis of PCP is more accurate. And they proposed that three patients, in particular, who couldn't afford or reject bronchoscopy, were diagnosed with PCP by pneumocystis carinii sequencing readings in the peripheral blood samples. It indicates the feasibility of NGS as a non-invasive tool for diagnosis of PCP in the future.

Therefore, authors summarize the advantages of NGS as follows.<sup>19</sup> 1. Early and rapid identification of pathogens. The technology can sequence millions or even billions of DNA molecules at a time, and the detection covers thousands of pathogenic microorganisms. The result is usually obtained in 2-3 days along with genus information of suspected pathogenic microorganisms. 2. Detection of special pathogens to make up for traditional detection techniques. In the case of patients with unknown etiological diagnosis or highly suspected infection of special pathogens, it is difficult to detect pathogens by conventional testing methods. In this situation, NGS could lend a hand. If possible, samples of blood can be collected with infected sites for testing. The presence of nucleic acid of the same pathogen by NGS indicates a high diagnostic significance. 3. High sensitivity. NGA allows direct extraction of total DNA fragments in the sample for testing without the help of specific primer as well as identification of nucleic acid category through bioinformatics analysis. In addition, it can also obtain sequence number, coverage of pathogens through quantitative analysis so as to identify common and rare clinical infectious strain or mutant strains, avoiding ignorance as much as possible.

However, NGS also has disadvantages:<sup>20</sup> 1. It is difficult to effectively monitor drug-resistant genes. As can be seen from the report in Table 1, there are no reports of pathogen resistance, creating difficulties in choosing drugs. 2. It is difficult to effectively distinguish pathogenic bacteria from background bacteria. Despite the high sensitivity of NGS, it is still difficult to effectively distinguish contamination bacteria, colonization bacteria or real pathogenic microorganisms.<sup>21</sup> NGS produces a list of pathogens, which may present multiple positive results at the same time. It could be a challenge for clinicians to determine the real pathogens based on sequencing results alone. Therefore, the test results need interdisciplinary and comprehensive interpretation.

NGS is still developing and maturing, and it is believed that it would contribute to the improvement of clinical diagnosis in the near future

## CONCLUSION

*Pneumocystis jirovecii* is a common opportunistic pathogen in immunosuppressive patients. Next-generation Sequencing (NGS) is an effective tool for the rapid diagnosis of *Pneumocystis jirovecii* for TMP/SMX treatment against severe pneumonia caused by *Pneumocystis jirovecii*.

## ACKNOWLEDGEMENTS

The researchers would like to thank the physicians in the Department of Oncology and Critical Medicine for their help in the process of collecting and saving the data.

*Funding: No funding sources*

*Conflict of interest: None declared*

*Ethical approval: Not Required*

## REFERENCES

1. Morris A, Norris KA. Colonization by *Pneumocystis jirovecii* and its role in disease. *Clin Microbiol Rev.* 2012 Apr;25(2):297-317.
2. Duboucher C, Boggia R, Morel G, Capron M, Pierce RJ, Dei-Cas E, et al. *Pneumocystis pneumonia*: immunosuppression, *Pneumocystis jirovecii*, and the third man. *Nat Rev Microbiol.* 2007 Dec;5(12):967.
3. Goodwin S, McPherson JD, McCombie WR. Coming of age: ten years of next-generation sequencing technologies. *Nat Rev Genet.* 2016 May 17;17(6):333-51.
4. Deurenberg RH, Bathoorn E, Chlebowicz MA, Couto N, Ferdous M, García-Cobos S, et al. Application of next generation sequencing in clinical microbiology and infection prevention. *J Biotechnol.* 2017 Feb 10;243:16-24.
5. Cawcutt K, De Moraes AG, Lee SJ, Park JG, Schears GJ, Nemerbut ME. The use of ECMO in HIV/AIDS with *Pneumocystis jirovecii* Pneumonia: a case report and review of the literature. *ASAIO J.* 2014 Sep-Oct;60(5):606-8.
6. Papazian L, Calfee CS, Chiumello D, Luyt CE, Meyer NJ, Sekiguchi H, et al. Diagnostic workup for ARDS patients. *Intensive care medicine.* 2016 May 1;42(5):674-85.
7. Catherinot E, Lanternier F, Bougnoux ME, Lecuit M, Couderc LJ, Lortholary O. *Pneumocystis jirovecii* Pneumonia. *Infect Dis Clin North Am.* 2010 Mar;24(1):107-38.
8. Herrag M, Elfassy Fihry MT, Alaoui Yazidi A. *Pneumocystis jirovecii*: what does this mean? *Rev Pneumol Clin.* 2010 Dec;66(6):342-6.
9. De Castro N, Scemla A, Gallien S. *Pneumocystis jirovecii* pneumonia in HIV-infected patients. *Rev Mal Respir.* 2012 Jun;29(6):793-802.
10. Rouyer M, Stoclin A, Blanc FX. *Pneumocystis pneumonia* in HIV-negative adults. *Rev Mal Respir.* 2015 Dec;32(10):985-90.
11. White PL, Backx M, Barnes RA. Diagnosis and management of *Pneumocystis jirovecii* infection. *Expert Rev Anti Infect Ther.* 2017 May;15(5):435-447.
12. Tasaka S, Tokuda H. Recent advances in the diagnosis of *Pneumocystis jirovecii* pneumonia in HIV-infected adults. *Expert Opin Med Diagn.* 2013 Jan;7(1):85-97.
13. Song Y, Ren Y, Wang X, Li R. Recent Advances in the Diagnosis of *Pneumocystis Pneumonia*. *Med Mycol J.* 2016;57(4):E111-6.
14. Chabé M, Durand-Joly I, Dei-Cas E. Transmission of *Pneumocystis* infection in humans. *Med Sci (Paris).* 2012 Jun-Jul;28(6-7):599-604.
15. Reid AB, Chen SC, Worth LJ. *Pneumocystis jirovecii* pneumonia in non-HIV-infected patients: new risks and diagnostic tools. *Curr Opin Infect Dis.* 2011 Dec;24(6):534-44.
16. Capobianchi MR, Giombini E, Rozera G. Next-generation sequencing technology in clinical virology. *Clin Microbiol Infect.* 2013 Jan;19(1):15-22.
17. Deurenberg RH, Bathoorn E, Chlebowicz MA, Couto N, Ferdous M, García-Cobos S, et al. Application of next generation sequencing in clinical microbiology and infection prevention. *J Biotechnol.* 2017 Feb 10;243:16-24.
18. Yi Zhang, Jing-Wen Ai, Peng Cui, Zhang WH, Wu HL, Ye MZ. A cluster of cases of *Pneumocystis pneumonia* identified by shotgun metagenomics approach. *J Infect.* 2019 Feb;78(2):158-69.
19. Lecuit M, Eloit M. The diagnosis of infectious diseases by whole genome next generation sequencing: a new era is opening. *Front Cell Infect Microbiol.* 2014 Mar 6;4:25.
20. Lefterova MI, Suarez CJ, Banaei N, Pinsky BA. Next-Generation Sequencing for Infectious Disease Diagnosis and Management: A Report of the Association for Molecular Pathol. *J Mol Diagn.* 2015 Nov;17(6):623-34.
21. Rinker DC, Pitts RJ, Zwiebel LJ. Disease vectors in the era of next generation sequencing. *Genome Biol.* 2016 May 6;17(1):95.

**Cite this article as:** Zheng D, Chen K, Xiao F, Liu N. Next generation sequencing in early diagnosis of *Pneumocystis jirovecii* pneumonia after chemotherapy: a case report. *Int J Res Med Sci* 2019;7:3561-5.