

## Case Report

# Pure trapezio-metacarpal dislocation - a rare injury

Abdul Qayyum Khan<sup>1\*</sup>, Gul Ar Navi Khan<sup>2</sup>, Zafar Ahmad Khan<sup>1</sup>

<sup>1</sup>Department of Orthopaedic Surgery, <sup>2</sup>Department of Physiology, J.N. Medical College, A.M.U., Aligarh, India

**Received:** 09 February 2016

**Revised:** 09 February 2016

**Accepted:** 07 March 2016

**\*Correspondence:**

Dr. Abdul Qayyum Khan,

E-mail: drabdulqayyum@rediffmail.com

**Copyright:** © the author(s), publisher and licensee Medip Academy. This is an open-access article distributed under the terms of the Creative Commons Attribution Non-Commercial License, which permits unrestricted non-commercial use, distribution, and reproduction in any medium, provided the original work is properly cited.

### ABSTRACT

Isolated trapezio-metacarpal dislocation is a rare condition, generally occurs due to fall on outstretched hand. These injuries are sometimes missed in polytrauma patients or sometimes neglected as in underdeveloped world. Various treatment modalities are used, including conservative and surgical options; however no gold standard approach exists for this rare injury. This case report aims to report outcome of a trapezio-metacarpal (TM) dislocation of a patient who was treated conservatively with excellent functional outcome.

**Keywords:** Dislocation, Trapezio-metacarpal, Thumb

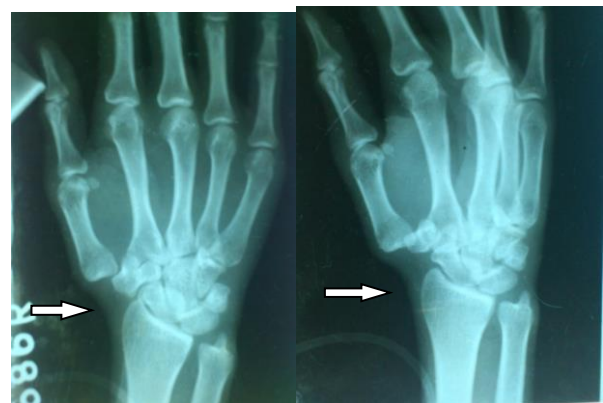
### INTRODUCTION

Pure trapezio-metacarpal dislocation is a rare hand injury.<sup>1</sup> Epidemiologically, it accounts for less than 1% of all hand traumas. The lesion is usually due to an axial force transmitted through partially flexed thumb, forcing the joint to deflect dorsally. Dislocation occurs in dorsal direction due to volar part of the ligament being thicker and stronger. Optimal treatment strategy for traumatic Trapezio-metacarpal dislocation remains controversial.<sup>2</sup> Closed reduction and cast, open or closed reduction with temporary K-wire fixation, and dorsal capsule and ligament reconstruction have been used to stabilize the joint. However few cases have been reported in the literature.

### CASE REPORT

A 23 years old male presented to emergency department, one hour after sustaining injury to his right thumb, when he fell down from his motorcycle. He fell down on the outstretched hand. Patient felt excruciating pain in the thumb and he was unable to move his right thumb. On examination deformity, fullness and tenderness was present at anatomical snuffbox. Instability was present at

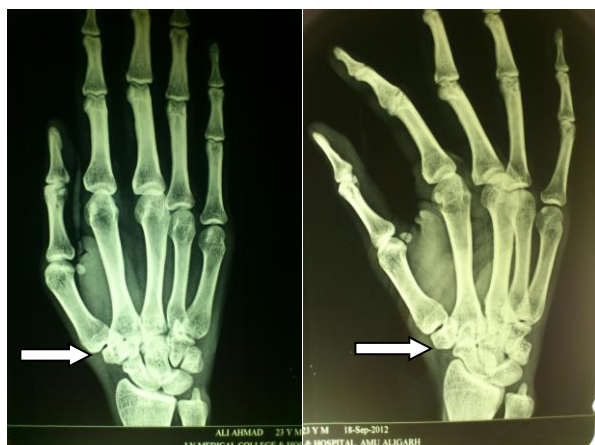1<sup>st</sup> carpo-metacarpal joint. For this X-ray right hand anteroposterior and oblique views were done. This shows trapazio-metacarpal dislocation right hand (Figure 1).



**Figure 1: Anteroposterior and oblique view of right hand showing carpo-metacarpal dislocation of right thumb.**

Patient was managed with closed reduction (Figure 2) and thumb spica cast immobilization for 4 weeks

followed by physiotherapy. Patient gained full range of motion of thumb at the final follow-up after 6 months.



**Figure 2: Anteroposterior and oblique view of right hand after closed reduction, showing perfect reduction of 1<sup>st</sup> carpo-metacarpal joint.**

## DISCUSSION

Pure thumb carpometacarpal (trapezometacarpal) dislocation is the rare form of injury at thumb Carpometacarpal joint.<sup>1</sup> There are only 39 cases published in English literature from 1983-2008.<sup>2</sup> Common forms of dislocation at this joint are Bennett fracture dislocation (thumb carpo-metacarpal dislocation + oblique intraarticular # base of 1<sup>st</sup> metacarpal) or Rolando fracture dislocation (thumb carpo-metacarpal dislocation + comminuted intraarticular # base of 1<sup>st</sup> metacarpal).<sup>3</sup>

Most thumb CMC dislocations are dorsal and are thought to occur through axial loading of a partially flexed thumb. Motorcyclists may be prone to sustaining this injury and this injury can be missed on initial evaluation. The dislocation will often be reduced before being seen by the surgeon. Clinical diagnosis is then based on identifying the residual instability. Differentiating complete from incomplete ligament rupture is essential, as initial operative treatment is appropriate only for complete disruptions.<sup>3</sup>

Treatment options include a closed reduction or open reduction, with or without K-wire fixation, and thumb spica cast immobilization.<sup>2,4,5</sup>

Closed reduction should be done under adequate analgesia with longitudinal traction, abduction, and extension of the thumb. Place direct pressure on the base of the thumb metacarpal base, displacing it distally, volarly, and ulnarly. Post reduction radiographs should be done to confirm the reduction.<sup>4</sup>

Immobilization to be maintained in a thumb spica cast with the thumb held in abduction and extension and pressure placed on the dorsoradial aspect of the metacarpal base. If on radiograph, the sign of persistent subluxation persists, then percutaneous transarticular K-wire fixation should be done. The wires and cast to be removed at 6 weeks and physiotherapy to be started.

Despite successful reduction of acute dislocations of the thumb CMC joint, instability and redislocation are common, and early ligament reconstruction may be necessary.<sup>2,4</sup> It is important to monitor the patient radiographically after K-wire removal at frequent intervals until it is certain that stability has been achieved.<sup>3,4,5</sup>

*Funding: No funding sources*

*Conflict of interest: None declared*

*Ethical approval: Not required*

## REFERENCES

1. Bosmans B, Verhofstad MHJ, Gosens T. Traumatic thumb carpometacarpal joint dislocations. *J Hand Surg.* 2008;33A:438-41.
2. Fotiadis E, Svarnas T, Lyrtzis C, Papadopoulos A, Akritopoulos P, Chalidis B. Isolated thumb carpometacarpal joint dislocation: a case report and review of the literature. *J Orthop Surg Res.* 2010;5:16.
3. Robert BW, James HD, Court-Brown, Charles M. *Tornetta Rockwood And Green's Fractures In Adults*, 7th Edition 2010;765-770.
4. Chapman, Michael W, *Chapman's Orthopaedic Surgery*, 3rd Edition 2001;1298-1300.
5. Shah J, Patel M. Dislocation of the Carpometacarpal Joint of the Thumb. A Report of Four Cases. *Clin Orthop.* 1983;175:166-9.

**Cite this article as:** Khan AQ, Khan GAN, Khan ZA. Pure trapezio-metacarpal dislocation - a rare injury. *Int J Res Med Sci* 2016;4:1290-1.