

## Case Report

# Reverse-flow anterolateral thigh flap for knee soft-tissue reconstruction: case report

**Banegas-Ruiz R.<sup>1</sup>, Gómez-Mendoza Francisco Fabián<sup>2</sup>, Baca-Domínguez Carlos Rubén<sup>3</sup>, Campos-Angulo Gerardo<sup>3</sup>, Luis Jesús Alejo-Fuentes<sup>4</sup>, Luis Fernando Alejo-Fuentes<sup>5</sup>, Porras-Méndez Christian<sup>6</sup>, Valderrama-Treviño AI<sup>7</sup>, Juan Pablo Espinosa-Torres<sup>8</sup>, Germán E. Mendoza-Barrera<sup>9</sup>, Escalera-Moreno Rafael<sup>10</sup>, Yañez-Roa Berenice<sup>10</sup>, Ramírez-Guerrero Mariana<sup>10</sup>, Baltazar Barrera Mera<sup>11\*</sup>**

<sup>1</sup>Department of Traumatology, Rehabilitation Hospital, Luis Guillermo Ibarra Ibarra, CDMX, Mexico

<sup>2</sup>Department of Hand Surgery, Central Military Hospital, CDMX, Mexico

<sup>3</sup>Department of Hand Surgery and Microsurgery, Rehabilitation Hospital. Luis Guillermo Ibarra Ibarra, CDMX, Mexico

<sup>4</sup>Department of Hand Surgery, Hospital Angeles Centro Médico del Potosí, SLP, Mexico

<sup>5</sup>Student, ISSSTE, SLP, Mexico

<sup>6</sup>Department of General Surgery, High Specialty Hospital, Veracruz

<sup>7</sup>Laboratory of experimental immunotherapy and tissue engineering, Faculty of Medicine, UNAM, CDMX, Mexico

<sup>8</sup>Department of Pediatric Plastic and Reconstructive Surgery, HGCMN La Raza, IMSS, CDMX, Mexico

<sup>9</sup>Department of General Surgery, Creighton University Medical Center, Omaha, Nebraska, USA

<sup>10</sup>Physician, Faculty of Medicine, UNAM, CDMX, Mexico

<sup>11</sup>Department of Physiology, Faculty of Medicine, UNAM, CDMX, Mexico

**Received:** 18 July 2019

**Accepted:** 11 September 2019

### \*Correspondence:

Dr. Baltazar Barrera Mera,

E-mail: [baltazar.barrera.mera@gmail.com](mailto:baltazar.barrera.mera@gmail.com)

**Copyright:** © the author(s), publisher and licensee Medip Academy. This is an open-access article distributed under the terms of the Creative Commons Attribution Non-Commercial License, which permits unrestricted non-commercial use, distribution, and reproduction in any medium, provided the original work is properly cited.

## ABSTRACT

The reconstruction of the injured tissue around the knee is a complex procedure for the plastic and orthopaedic surgeon. The objective is to provide an acceptable function and aesthetic result. Successful wound management includes meticulous debridement, planning and proper execution of the surgical procedure. An 11-year-old male patient with a right patellar fracture using an anterolateral thigh flap with reverse flow to cover the skin defect. For such purposes, the reverse flow anterolateral flap is an effective, trustworthy and well-documented option. The correct obtaining and implantation of the flap reduces the morbidity of the donor site, offers options in size and design, an adequate length of the pedicle and the possible combination with the fascia lata in case it is required. The versatility of the reverse flow anterolateral flap makes it a possible therapeutic alternative in reconstructive surgery since it is aesthetic and functional for the reconstruction of tissue near the knee joint.

**Keywords:** Anterolateral thigh flap, Knee soft-tissue reconstruction, Knee trauma, Patellar fracture, Reverse flow ALT flap, Reconstructive surgery

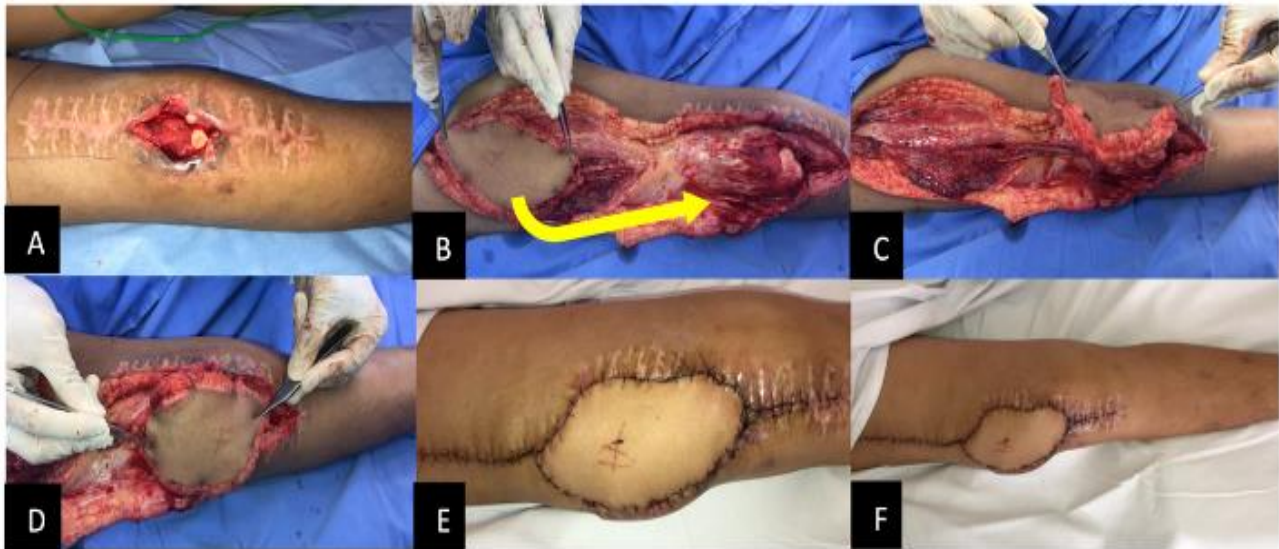
## INTRODUCTION

The reverse flow anterolateral flap has been used for the reconstruction of soft tissues around the knee, in the

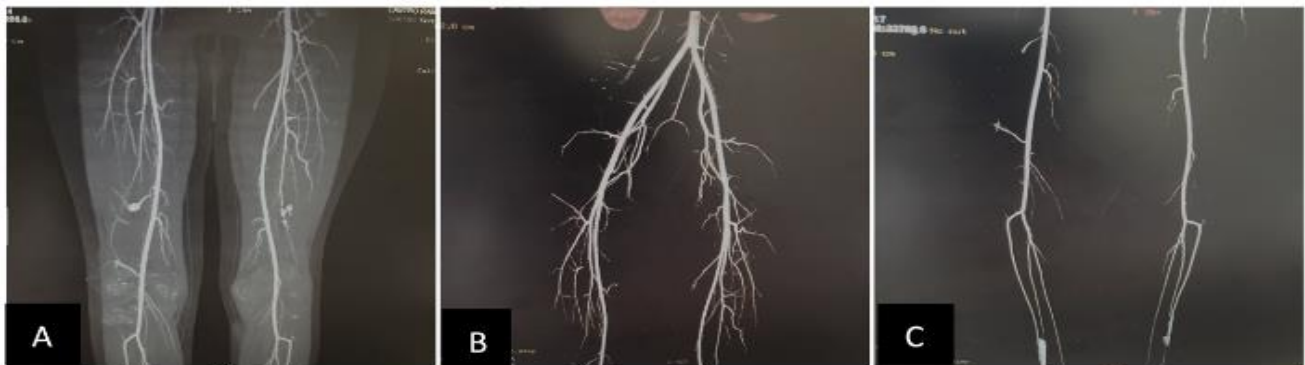reconstructive surgery of injuries in the lower extremities since it was first described by Zhang in 1990.<sup>1-6</sup> It offers advantages such as an adequate length of the pedicle, flexibility in the design and size of the flap, possible combination with fascia lata and lower donor site morbidity. Among its disadvantages is the risk of vascular congestion due to inverse blood flow, the resistance of the venous valves, and the presence of anatomical variants that impede the correct irrigation of the flap.<sup>6</sup>

### CASE REPORT

An 11-year-old male patient with a right patellar fracture, treated with cerclage with wire, evolved to bone infection that ended in septic arthritis. This was treated with washouts with wound VAC and then placement of an anterior lateral thigh flap to cover the skin defect with reverse flow (Figure 1).



**Figure 1: Reverse-flow anterolateral thigh flap. (A). Skin defect in the knee. (B). Reverse-flow anterolateral thigh flap for reconstruction of the soft tissues of the knee. (C). Translational axis of the flap to the cutaneous defect. (D). Transfer of the angiosome to the cutaneous defect. (E). Final result. (F). Panoramic view of the flap.**



**Figure 2: Angiotomography. (A). Angiotomography with coronal plane reconstruction where there is an increase in the density and heterogeneity of the soft tissues adjacent to the knee joint. Vascular structures with path and gauge in normality. There are images that could suggest vascular curls in the middle third of both superficial femoral arteries. (B and C). Traditional reconstruction in coronal plane with vascular structures in normal trajectory and caliber, without filling defects, with adequate repletion.**

### DISCUSSION

The objective of the reconstruction of the injured tissue around the knee is to provide a good aesthetic appearance and preserve its function. There are several alternatives, including local cutaneous flaps, fasciocutaneous flaps,

muscle flaps or free flaps. Due to its effectiveness and experience reported in the literature, an appropriate option is to perform an reverse flow anterolateral thigh flap.<sup>7</sup>

It is essential to obtain a well-vascularized tissue to ensure adequate healing of the wound and to avoid post-

surgical complications. Figure 2. The blood supply of the flap depends basically on the descending branch of the lateral femoral circumflex artery, which runs caudally through the medial edge of the vastus lateralis muscle or, sometimes, over the vastus intermedius muscle until reaching the knee.

The artery is accompanied by two concomitant veins and the motor nerve of the vastus lateralis muscle. By lifting the flap, the surgeon can visualize the possible existing anatomical variants, such as hypoplasia of the descending branch of the femoral circumflex artery or the absence of flap perforators. A requirement for success of the procedure is an intact vascular connection between the descending branch of the lateral femoral circumflex artery and the superior lateral genicular artery. However, it is possible to use the femoral rectus artery as an alternative.<sup>8</sup>

The absence of perforators of the antero lateral flap occurs in 0.89% to 11.2% of the cases, an alternative to this clinical scenario is to make a flap of the fascia lata or an anteromedial flap.<sup>9,10</sup>

## CONCLUSION

The versatility of the reverse flow antero lateral flap makes it a possible therapeutic alternative in reconstructive surgery since it is aesthetic and functional for the reconstruction of the tissue near the knee. However, it has critical points in its implementation, such as knowledge of local anatomy and the inclusion of the neurovascular package in the dissection.

## ACKNOWLEDGEMENTS

Authors would like to thank Dr. Eric Salvador Juárez Duarte, Radiologist, Hospital Star Médica Centro. CDMX. Mexico.

*Funding: No funding sources*

*Conflict of interest: None declared*

*Ethical approval: Not required*

## REFERENCES

1. Pan SC, Yu JC, Shieh SJ, Lee JW, Huang BM, Chiu HY. Distally based anterolateral thigh flap: an anatomic and clinical study. *Plastic Reconst Surg.* 2004 Dec 1;114(7):1768-75.

2. Lin RY, Chien WH. Experiences in harvesting type II distally based anterolateral thigh flaps. *Plast Reconstr Surg.* 2006;118:282-4.
3. Gravvanis A, Britto JA. Venous augmentation of distally based pedicled ALT flap to reconstruct the tibial tuberosity in a severely injured leg. *Ann Plast Surg.* 2009;62:290-2.
4. Lin CH, Hsu CC, Lin CH, Chen YC, Wei FC. Antegrade venous drainage in a reverse-flow anterolateral thigh flap. *Plastic Reconst Surg.* 2009 Nov 1;124(5):273e-4e.
5. Demirseren ME, Efendioglu K, Demiralp CO, Kilicarslan K, Akkaya H. Clinical experience with a reverse-flow anterolateral thigh perforator flap for the reconstruction of soft-tissue defects of the knee and proximal lower leg. *J Plast Reconst Aes Surg.* 2011 Dec 1;64(12):1613-20.
6. Il-Kug K, Tae-Gon K, Jun-Ho L, Yong-Ha K, Ki-Rin P. The Clinical Course of Reverse-flow Anterolateral Thigh Flap: Need to Prepare for Venous Congestion and Salvage Operation. *APS.* 2012;39(3):262-4.
7. Demirseren ME, Efendioglu K, Demiralp CO, Kilicarslan K, Akkaya H. Clinical experience with a reverse-flow anterolateral thigh perforator flap for the reconstruction of soft-tissue defects of the knee and proximal lower leg. *JPRAS.* 2011;64:1613-20.
8. Li S, Liu Y, Zang M, Yu S, Guo W, Yang R. Rectus femoris branch: An alternative blood supply for a distally based anterolateral thigh flap. *J Plast Reconst Aes Surg.* 2018 Feb 1;71(2):232-8.
9. Namgoong S, Yoon YD, Yoo KH, Han SK, Kim WK, Dhong ES. Alternative choices for anterolateral thigh flaps lacking suitable perforators: a systematic review. *J Reconstr Microsurg.* 2018 Sep;34(07):465-71.
10. Ishida LH, Munhoz AM, Montag E, Alves HR, Saito FL, Nakamoto HA, et al. Tensor fasciae latae perforator flap: minimizing donor-site morbidity in the treatment of trochanteric pressure sores. *Plastic Reconst Surg.* 2005 Oct 1;116(5):1346-52.

**Cite this article as:** Banegas-Ruiz R, Gómez-Mendoza FF, Baca-Domínguez CR, Campos-Angulo G, Alejo-Fuentes LJ, Alejo-Fuentes LF, et al. Reverse-flow anterolateral thigh flap for knee soft-tissue reconstruction: case report. *Int J Res Med Sci* 2019;7:3914-6.