

Case Report

Giant dentigerous cyst of maxillary sinus associated with impacted maxillary canine

P. P. G. Krisna Bayu Pramana Rimbawan*, I. Putu Gede Windhu Saputra,
Ratna Rayeni Natasha Rooseno

Division of Plastic Reconstructive and Aesthetic Surgery, Mangusada Badung Hospital, Bali, Indonesia

Received: 05 August 2019

Revised: 20 August 2019

Accepted: 28 August 2019

*Correspondence:

Dr. P.P.G. Krisna Bayu Pramana Rimbawan,

E-mail: krisnabayupramana@gmail.com

Copyright: © the author(s), publisher and licensee Medip Academy. This is an open-access article distributed under the terms of the Creative Commons Attribution Non-Commercial License, which permits unrestricted non-commercial use, distribution, and reproduction in any medium, provided the original work is properly cited.

ABSTRACT

Dentigerous cyst is a cyst that encapsulates enamel of the unerupted tooth, thus causing the tooth become unable to complete the eruption process. This cyst is defined as a developmental cyst as it generally occurs in first until the third decades of life. Dentigerous cyst commonly affect the mandibular area of the teeth. This article describes the case of a young patient with dentigerous cyst which affect maxillary canine. A 6-year-old girl was admitted to Plastic Reconstructive and Aesthetic Surgery Clinic at Mangusada Hospital Bali with facial asymmetry on her right cheek, noticed since the past one week. She got some medicines from the general physician, but there was no improvement. From the CT scan, we found a solitary mass on the size of 3 x 3.2 x 3.6 cm on the right maxillary area. Enucleation was done and the Caldwell-Luc approach was performed under general anesthesia. The cyst revealed to have an ectopic maxillary canine inside. The cyst and ectopic tooth were extracted from the pathological site and the incisional specimens were sent for histopathological examination. The result revealed a cyst lined by non-keratinized stratified squamous epithelium without any malignancy. She had antibiotics therapy post-surgery, and her symptoms were resolved within a week. In one month follow up, there was no sign of recurrence.

Keywords: Giant dentigerous cyst, Maxillary sinus, Maxillary canine

INTRODUCTION

Dentigerous cyst is the most frequent type of developmental odontogenic cyst and encompasses for about 16.2% to 37.5% incidence of epithelium-lined cysts in the maxilla.¹ Dentigerous cyst is a benign odontogenic lesion that results from accumulation of fluid between the enamel crown and enamel epithelium. It develops around the crown of an unerupted tooth by expansion of follicle when fluid collect or a space occurs between the reduced enamel of an impacted tooth and enamel epithelium.² The most commonly affected teeth are the mandibular third molars, followed by the maxillary third molars, the maxillary canines, and rarely the maxillary right central incisor, that caused by tendency of these teeth with

impaction. This cyst occurs in a wide range of age with a peak frequency in the first to third decades of life and have slight male predominance.^{2,3}

Dentigerous cyst is often found on routine radiographic examination and usually asymptomatic unless there is acute inflammatory exacerbation. It's found when a tooth or teeth are missing, failed to erupt, tilted out of their alignment, or sometimes while there was purulent discharge coming out from that site. The clinical manifestations, such as slowly enlarging swelling, teeth displacement, teeth mobility and sensitivity may be present if the cyst is large.^{2,4} Pain and pus accumulation can be found when there is secondary infection,

especially by the bacteria. Extensive lesion can also make facial asymmetry.

Radiographically, dentigerous cyst is usually characterized as a well-defined radiolucency surrounding the crown of unerupted teeth and often has sclerotic borders. Dentigerous cyst exists and suspected when the space between tooth crown and dental follicular is greater than 5 mm. Giant cyst can be defined if the size of cyst reaches more than 2 cm in diameter.⁴ Preview from histological examination composed of thin connective tissues lined by non-keratinized stratified squamous epithelium of myxoid tissues, odontogenic remnants and rarely sebaceous cells.^{5,6} Dentigerous cyst is commonly present solitary. Bilateral or multiple cysts are usually associated with syndromes, such as mucopolysaccharidosis, basal cell nevus syndrome, or cleidocranial dysplasia.⁷ It must be noted that radiological and histological finding, confirm the diagnosis of dentigerous cyst.

The treatment and approach that indicated for this cyst depends on the size and location of the lesion. If left untreated, dentigerous cyst may cause some complications include permanent bony deformity or pathologic bone fracture, loss of essential permanent dentition, impaction of the teeth, and over a period of time can progress to become ameloblastoma, squamous cell carcinoma or muco-epidermoid carcinoma from the epithelial lining of the cyst.⁴ Therefore, early recognition of this cyst plays a vital role, then the appropriate modality can be done to prevent and decrease the morbidity and complications. This report presents a case of dentigerous cyst on a girl, associated with maxillary canine and treated by enucleation via Caldwell-Luc approach.

CASE REPORT

A 6-year-old girl was admitted to Plastic Reconstructive and Aesthetic Surgery Clinic at Mangusada Badung Hospital Bali with facial asymmetry on her right cheek since the past one week. The facial asymmetry was first noticed by her mother (Figure 1). She had no history of chronic rhinosinusitis or recurrent orodental infection and gum bleeding previously.

One week ago, she got low impact trauma where her face hit the doorknob, without any bleeding or sign of fracture. She had been treated by general physician with analgesic and antibiotic, but there was no improvement and her mother noticed the facial asymmetry got worse especially on the right cheek. The patient had no systemic and congenital disease. History of cachexia or weight loss was denied by her mother.

Clinical examination revealed that patient was generally healthy. On local examination (right cheek), there was a palpable mass on right maxilla. The mass was painless on palpation. The patient had normal functioning on cranial

nerves V and VII. Intraoral examination revealed that all permanent teeth were present except the right maxillary canine. Her right maxillary incisor was also got discoloration becoming black (Figure 2).

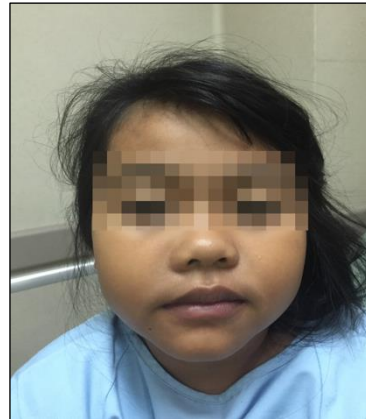

Figure 1: Anterior view of the patient. Noted the facial asymmetry over the right cheek.

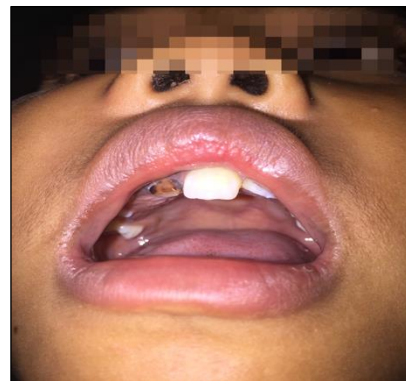

Figure 2: Intraoral view of the patient showing swollen cheek, absence of right maxillary canine and discoloration of the right maxillary incisor.

Routine hematological investigation was done and there was no significant abnormality. On imaging examination, Computed Tomography (CT) scan revealed from 3D reconstruction view there was a massive lesion on right maxillary (Figure 3A). Axial plane CT Scan revealed a well-circumscribed hypodense lesion measuring approximately 3 x 3.2 x 3.6 cm on maxillary sinus with tooth appearance inside it (Figure 3B). Panoramic radiograph then performed to evaluate the involvement of unerupted teeth. The result showed unilocular radiolucent lesion involving the ectopic maxillary canine in the maxillary sinus. (Figure 4). Based on findings above, it was preliminary diagnosed as dentigerous cyst with differential diagnosis as radicular cyst.

Considering the factors such as age, site of lesion, as well as regenerative capacity of the musculo-periosteal tissue in growing child, it was planned to treat the cyst with surgical enucleation via Caldwell-Luc approach on the next visit. After performed preoperative serological and

imaging evaluations, surgical enucleation was done under general anesthesia and broad-spectrum antibiotic. Vasoconstrictor was injected to minimize bleeding and control hemostasis. Intraoral incision and buccal tissue dissection was placed along the anterior border of right maxillary sinus. Upon making osteotomy in maxillary bone, large amount of yellow-colored purulent fluids were expressed.

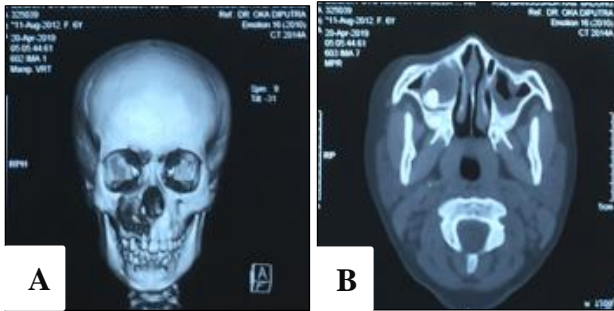


Figure 3: Pre-operative CT scan of the patient. (A) 3D reconstruction showed massive lesion on right maxilla. (B) Axial plane showed a well-circumscribed hypodense lesion measuring 3 x 3.2 x 3.6 cm on maxillary sinus with tooth inside.

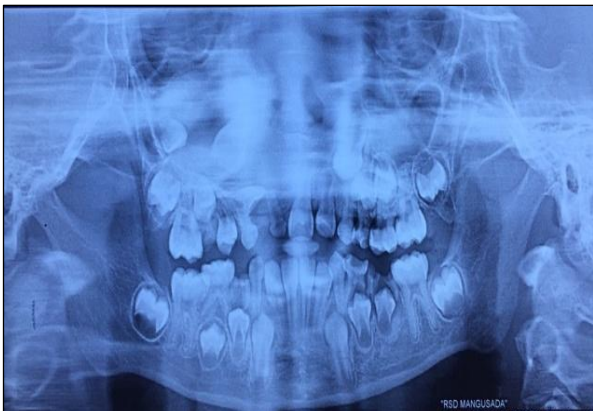

Figure 4: Panoramic radiograph showing unilocular radiolucent involving ectopic maxillary canine.

Drainage was allowed and cyst sac were removed by enucleation technique. The floating canine and surrounding affected tissues were also extracted (Figure 5).

Some parts of the lesion, such as cyst wall, maxillary bone and canine were collected for histopathological evaluation (Figure 6).

After removing the sinus content, then maxillary sinus cavity was irrigated and hemostasis was achieved by using absorbable gelatin sponge. Primary closure was done after injected broad spectrum antibiotic. The periosteum was intact with its bony lesion surrounding the surgical window that had been made.

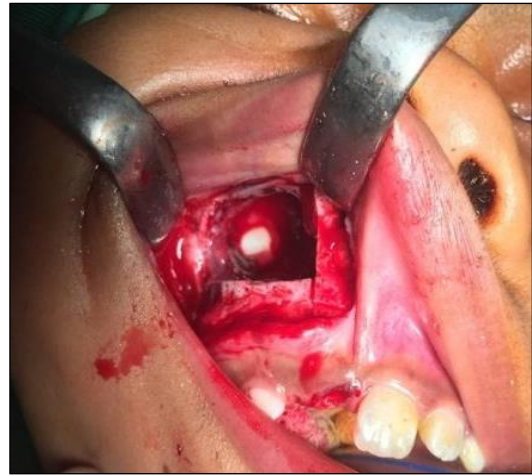


Figure 5: Ectopic right maxillary canine in the roof of right maxillary sinus was seen via Caldwell-Luc approach.

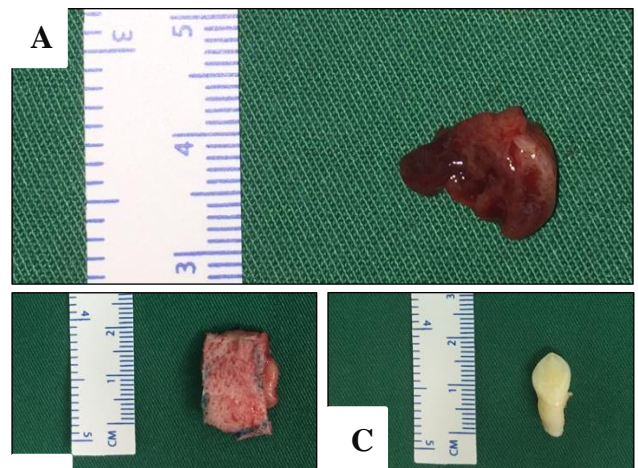

Figure 6: Specimens collected from the cyst for histopathological evaluation. (A) Cyst wall. (B) Maxillary bone. (C) Maxillary canine.

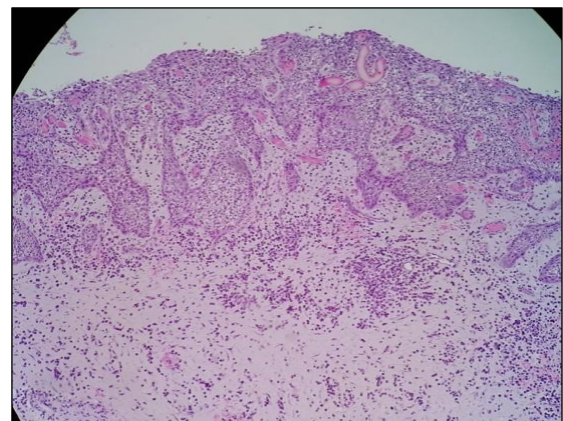


Figure 7: Histopathological examination revealed a cyst lined by non-keratinized stratified squamous epithelium.

Patient was sent to the ward after 2 hours observation post-operation. There was no complication during and after surgery. The patient was discharged from hospital on third day after surgery and got a week course of antibiotic and analgesic. Seven days after surgery, the patient was followed up as outpatient.

The symptoms were relief. The patient also brought the result of histopathological examination and revealed a cyst lined by non-keratinized stratified squamous epithelium without any malignancy (Figure 8).

DISCUSSION

Dentigerous cyst is considered as developmental cyst by nature, and rarely causing pain unless causing problem in nearby structure. Our patient is a 6-year-old girl, which had complaint of facial asymmetry without any significant inflammatory sign and no history of infection before. This condition is matched by our literature which stated the dentigerous cyst is usually asymptomatic, but it can be symptomatic when the size growing bigger than 2 cm. Dentigerous cyst usually affect mandible tooth, but 16.2% to 37.5% cases can be manifested as maxillary cyst.^{8,9}

From the intraoral examination, we found that her right maxillary canine was not erupted yet. Even though the 1st incisivus looks decayed, the other tooth seems develop normal. Dentigerous cyst itself usually affect the mandibular tooth, commonly permanent third molar. Some of the cases also report dentigerous cyst in the maxillary molar or maxillary canine.^{8,10}

The radiological and clinical examination are essential for dentigerous cyst diagnosis. In this case we already done CT scan to examine it radiologically. We found a well-circumscribed hypodense lesion measuring approximately 3 x 3.2 x 3.6 cm on maxillary sinus with tooth appearance inside. From pathophysiologic view, dentigerous cysts developed originally from the tooth follicle, the cyst usually envelope the enamel but leaving the other tooth structure outside.¹¹ This unerupted teeth then will be seen on radiological examination.

The management of dentigerous cyst is to remove the pathological cyst, and if possible, preserve the tooth eruption. There are several treatments which usually used to manage the patient, such as enucleation and marsupialization. For this patient, authors performed the enucleation procedure via Caldwell-Luc approach. The enucleation procedure is stated to reduce the possibility of recurrence of the cyst compared to marsupialisation.¹¹ This approach also allows us to get favorable pathological samples. Marsupialisation is better to preserve the teeth eruption, but the pathological defect is still in situ. This condition can provoke recurrence of the cyst.^{9,11}

The Caldwell-Luc surgery have been widely performed more than 100 years ago, primarily performed to obtain access for maxillary antrum by creating opening through canine fossa via a sublabial approach.⁷ The pathological result shows a cyst lined by non-keratinized stratified squamous epithelium without any malignancy. This finding is matched with the properties of the dentigerous cyst, which composed of thin connective tissues lined by non-keratinized stratified squamous epithelium of myxoid tissues, odontogenic remnants and rarely sebaceous cells. This cyst also defined as solitary cyst.^{9,11}

CONCLUSION

Dentigerous cyst is an odontogenic lesion that can make facial asymmetry especially while it takes place at the maxillary sinus. If the cyst left untreated, it can become bigger in size and make complications; include pathologic bone fracture, impaction of the teeth and causing other structure disorder such as diplopia. The treatment generally done by surgery. Enucleation or marsupialisation can be choosed, considering the patient condition. The antibiotics can be given in infected case based on bacterial culture swab. This is important for medical professionals to be aware and know the clinical manifestation and diagnostic modality, then the accurate diagnosis and therapy can be done to prevent complications and recurrence of the disease.

Funding: No funding sources

Conflict of interest: None declared

Ethical approval: Not Required

REFERENCES

1. Teixeira RG, Moraes P, Jodas CR. Decompression of a maxillary dentigerous cyst. *Porto Alegre* 2011;59(2):299-303.
2. Ikeshima A, Tamura Y. Differential diagnosis between dentigerous cyst and benign tumor with an embedded tooth. *J Oral Sci.* 2002;44(1):13-7.
3. AlSheddi MA. Odontogenic cysts a clinicopathological study. *Saudi Med J.* 2012;33(3):304-8.
4. Bharath KP, Revathy V, Poornima S. Dentigerous cyst in an uncommon site: a rare entity. *J Indian Soc of Pedodontics and Preventive Dentistry* 2011;29(6):99-103.
5. Taysi M, Ozden C, Cankaya B. Conservative approach to a large dentigerous cyst in an 11-year-old patient. *J Istanbul Univ Fac Dent.* 2016;50(3):51-6.
6. Fujii R, Kawakami M, Hyomoto M, Ishida J, Kirita T. Panoramic findings for predicting eruption of mandibular premolars associated with dentigerous cyst after marsupialization. *J Oral Maxillofac Surg.* 2008;66(2):272-6.
7. Amin ZA, Amran M, Khairudin A. Removal of extensive maxillary dentigerous cyst via a Caldwell-

- luc procedure. *J Archives of Orofacial Sciences.* 2008;3(2):48-51.
8. Moussa S, Sokhn S, Nasseh I. Unusual Behavior of the Mandibular Canal Associated to a Dentigerous Cyst. *J Dental Health, Oral Disorders and Therapy.* 2015;2(2):42.
 9. I Sasmita, L Epsilawati, F Pramanik. Prevalence of the Dentigerous Cyst in Indonesian people using Panoramic Radiograph. *J Int Dental and Medical Research.* 2017;10(1):108-10.
 10. Simamora R, Karasutisna T, Kasim A. Kista dentigerous pada ramus mandibula kanan (Laporan Kasus). *J Dentistry Indonesia.* 2003;10(3):816-20.
 11. Deana NF, Alves N. Cone Beam CT in Diagnosis and Surgical Planning of Dentigerous Cyst. *Case Rep Dent.* 2017;2017:7956041.

Cite this article as: Rimbawan PPGKBP, Saputra IPGW, Roosseno RRN. Giant dentigerous cyst of maxillary sinus associated with impacted maxillary canine. *Int J Res Med Sci* 2019;7:3901-5.