

## Case report

# Takotsubo cardiomyopathy complicating a twin pregnancy at partum

B.V. Nagabhushana Rao<sup>1\*</sup>, A. Rekha<sup>2</sup>, A. Sankar Narayan<sup>2</sup>, A. Manjusha<sup>3</sup>

<sup>1</sup>Department of Medicine, <sup>2</sup>Department of Cardiology, <sup>3</sup>Department of Critical care, Queens NRI Hospital, Visakhapatnam, Andhra Pradesh, India

**Received:** 18 August 2019

**Accepted:** 27 September 2019

**\*Correspondence:**

Dr. B.V. Nagabhushana Rao,

E-mail: bhavnavnrao@me.com

**Copyright:** © the author(s), publisher and licensee Medip Academy. This is an open-access article distributed under the terms of the Creative Commons Attribution Non-Commercial License, which permits unrestricted non-commercial use, distribution, and reproduction in any medium, provided the original work is properly cited.

### ABSTRACT

Takotsubo cardiomyopathy is a rare syndrome characterized by acute left ventricular dysfunction with regional left ventricular ballooning, mimicking myocardial infarction. This condition is often described in post-menopausal women. Authors present a case in an elderly primi with twin gestation immediately after Cesarean surgery. We discussed her presentation, investigations, diagnosis, management and outcome. 35 year female, a primi with twin pregnancy developed chest pain and shortness of breath immediately after Cesarean surgery. Her Electrocardiograph was abnormal, and Echocardiogram demonstrated abnormal apical ballooning of the left ventricle and severe dysfunction. Cardiac enzymes were elevated and chest skiagram showed pulmonary edema. She was managed in the intensive care unit with oxygen supplementation, diuretics and inotropes. She made an excellent recovery with normalization of left ventricular ejection fraction within 8 days. During the six months follow up, she was asymptomatic and left ventricular function remained normal.

**Keywords:** Cardiomyopathy, Echocardiogram, Myocardial infraction

### INTRODUCTION

Takotsubo cardiomyopathy is a syndrome presenting as transient regional systolic dysfunction of the left ventricular myocardium in the absence of significant contributory coronary artery disease and mimicking ST elevation myocardial infarction. It is also known as apical ballooning syndrome, broken heart syndrome and stress cardiomyopathy.<sup>1</sup>

There will be a mismatch of epicardial coronary artery perfused area and left ventricular dilated area in those patients having prior coronary artery disease. Dilated left ventricular wall resembles a Takotsubo, used to trap octopus in Japan. Postulated pathogenesis includes catecholamine excess, coronary artery spasm, microvascular dysfunction and dynamic mid cavity obstruction.<sup>2</sup> Women are more affected than men and in their sixth decade. Stress cardiomyopathy may account for one to two percent of patients presenting as ST

elevation myocardial infarction.<sup>3</sup> Though exact numbers are not known, in one prospective study of patients admitted to intensive care units with non-cardiac illness, 28 percent had transient apical ballooning.<sup>4</sup>

Stress cardiomyopathy is often precipitated by intense emotional or physical stress. Diagnosis of stress cardiomyopathy is made in the presence of transient regional wall motion abnormalities of the left ventricle, new electrocardiographic abnormalities, modest elevation of troponin levels and in the absence of angiographic evidence of obstructive coronary artery disease, myocarditis or pheochromocytoma.<sup>5</sup>

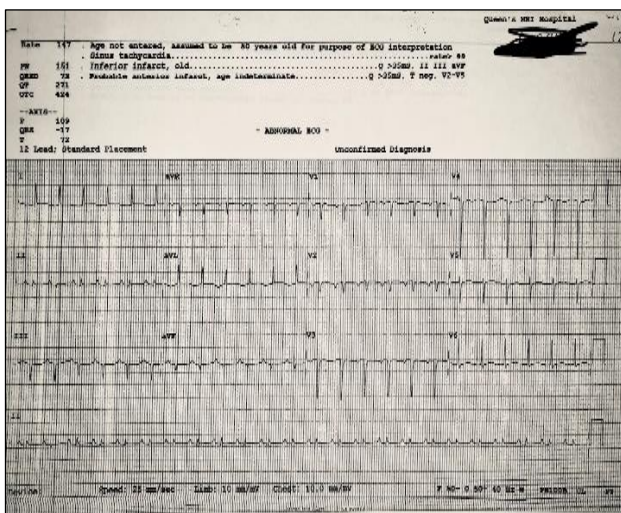
### CASE REPORT

Thirty five year old female patient was admitted to hospital intensive care at 1 PM on 14-08-2018. She underwent Lower Segment Cesarean Section (LSCS) at an obstetric hospital at 9.30 AM on the same day and delivered healthy

twin babies. She had been under follow up at the same hospital for hypertension complicating pregnancy and was on Labetalol 100 mg three times a day.

During prepartum follow up she never complained of breathlessness, fatigue or chest pain. Her blood pressure was under good control with the medication. Preoperative electrocardiogram (ECG) and echocardiogram (ECHO) were normal as well as other laboratory investigations.

The patient was a slightly anxious before being taken to the operation theatre, otherwise appeared healthy. Immediately after LSCS she developed shortness of breath and central chest pain. She was tachypnoeic and tachycardic. She was hypoxic and blood pressure rose up to 180/110 mmhg. ECG was abnormal. (Figure 1).



**Figure 1: ECG.**

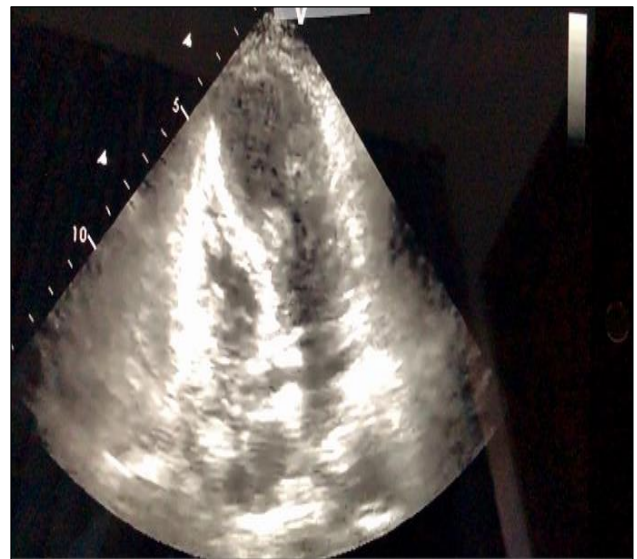Immediately she was shifted to the intensive care unit (ICU). Her pulse rate was 140 per minute, respiratory rate 35 per minute and oxygen saturation 84 % on room air. Bedside ECHO revealed left ventricular dysfunction and regional wall motion abnormalities in the apical region with ballooning. (Figure 2).

Noninvasive ventilation with supplemental oxygen was initiated. She was treated with intravenous frusemide 40mg 8th hourly and dobutamine 2.5 micrograms/kg/min infusion. In addition, she was also given ramipril 2.5 mg twice a day and carvedilol 12.5 mg twice a day. She made an excellent recovery.

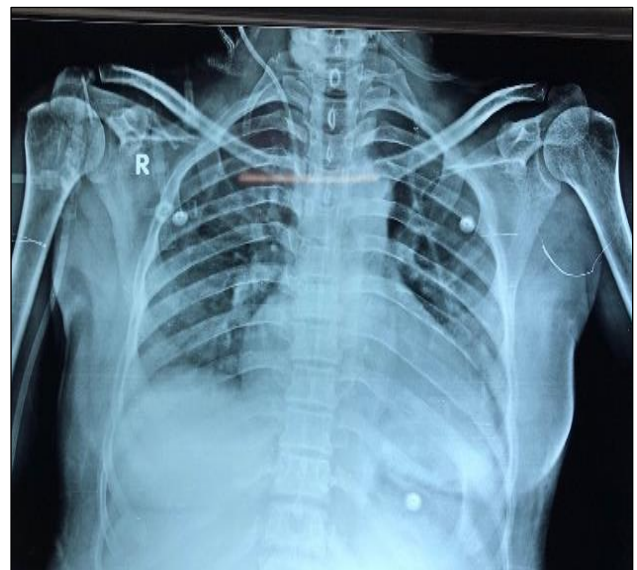**Investigations**

Hemoglobin: 12.3 grams, Total White blood cells: 15,000,  
 Erythrocyte sedimentation rate: 8 / hour  
 Serum electrolytes, Calcium, Phosphorus, Magnesium,  
 Liver function tests, Renal function tests: Normal  
 CPK MB: 9.4 ng/ ml (0.0 - 4.3 ng/ ml)  
 Troponin I: 6.0 ng/ ml (0.0 - 4.0ng/ ml)

Myoglobin: >500 ng/ ml (0.0 - 107 ng/ ml)  
 proBNP: 2200 pg/ml (0.0 - 100 pg/ml)  
 D-dimer: 1130 ng/ ml (0.0 - 400 ng/ ml)  
 Chest X-ray: Cardiomegaly with patchy opacification upper, mid and lower zones bilaterally suggestive of pulmonary edema (Figure 3).  
 ECG: Sinus tachycardia, ventricular rate:147 per minute, q wave in L2, L3,V1,V2,V3,V4,  
 ECHO: Apical ballooning, with left ventricular dysfunction, dilated inferior vena cava  
 Coronary angiogram: Normal epicardial vessels  
 Left ventricular ejection fraction:  
 14-08-18 : 31%, 16-08-18 :40%, 18-08-18 : 53%, 22-08-18:65%



**Figure 2: Echocardiography showing apical ballooning.**



**Figure 3: Chest X-ray PA view cardiac enlargement and pulmonary oedema.**

### **Differential diagnosis**

Acute coronary syndrome with or without ST elevation, Myocarditis, Vasospastic angina, Cocaine related acute coronary syndromes, Pheochromocytoma and focal reversible myocardial dysfunction associated with acute brain injury.

### **Outcome and follow up**

She made a good recovery and ejection fraction was normalized within 8 days. She was followed up fortnightly for a period of 6 months and her cardiac function was normal during follow up.

### **DISCUSSION**

Takotsubo cardiomyopathy, is a transient regional dysfunction of left ventricle often precipitated by stress. We described such a condition occurring in the immediate post caesarean surgery for an elderly primi with twin gestation. Twin pregnancy at the age of 35 is a stressful condition. In addition, she had been suffering from hypertension.<sup>6</sup> Twin babies were delivered by cesarean section which perpetuates stress and contributes to emotional and physical stress. The etiology of Takotsubo cardiomyopathy is not fully established but physical and emotional stress is one of the precipitating factors.<sup>7</sup> Our patient presented with chest pain and shortness of breath immediately after surgery. In a review of literature published in the journal of obstetrics and gynecology it was found that dominant symptoms were chest pain 44% and shortness of breath (28%). Among 16 cases described most women (81%) had cesarean delivery and symptoms appeared during surgery in 38%.<sup>8</sup> Our patient had an abnormal ECG and pulmonary edema at the time of presentation. Cardiac enzymes were elevated, and ECHO demonstrated apical ballooning. In a review it was found that 81.6% of stress cardiomyopathy patients presented with ST elevation, 63.4% presented with T wave abnormalities, 31.3 % had abnormal Q waves, other changes included QT prolongation and nonspecific abnormalities.<sup>9</sup> One case of 32 year female who presented with ventricular fibrillation and cardiac arrest was reported in The European journal of echocardiography.<sup>10</sup> Though relatively a self-limiting disease, fatal cardiac arrhythmia has to be kept in mind while managing Takotsubo cardiomyopathy. In our patient cardiac enzymes were elevated, albeit less than pro BNP. Cardiac enzymes were marginally elevated in contrast to pro BNP suggesting less myonecrosis.<sup>11</sup> Echocardiography is the major investigation, easily available and noninvasive. Our patient had regional wall abnormalities in the apical region with ballooning, pathognomonic of Takotsubo cardiomyopathy. The systolic ballooning can involve apical region (81.7%), mid ventricular region (14.6%), basal region (2.2%) and focal area (1.5%).<sup>12</sup> Rarely, it can present as global left ventricular dysfunction.<sup>13</sup> Cardiovascular magnetic resonance (CMR) may help in establishing a diagnosis. Late gadolinium enhancement on CMR may be useful to differentiate Takotsubo cardiomyopathy from Myocarditis.<sup>14</sup> Although limited data is available, Positron

emission tomography (PET) could become an important tool in confirming the diagnosis of stress cardiomyopathy. PET scans demonstrate an “inverse flow metabolism mismatch”, a discrepancy between normal perfusion and reduced glucose utilization in dysfunctional regions.<sup>15</sup> Coronary angiography is usually normal or have insignificant coronary artery disease. Some high risk patients may harbor obstructive coronary artery disease, albeit not in anatomical relation with ballooned segment. Suspicion of stress cardiomyopathy is not a sufficient reason to withhold definite treatment strategies like thrombolysis

Management of stress cardiomyopathy is usually supportive. Resolution of symptoms is usually rapid with alleviation of emotional or physical stress. Those patients who develop acute complications like shock and heart failure require intensive care management. Management of shock depends on whether the patient has or hasn't left ventricular outflow tract (LVOT) obstruction.<sup>16</sup> Those with hypotension without pulmonary congestion may benefit from cautious fluid resuscitation. Patients with severe LV systolic dysfunction may require inotropic agent. Those with persistent hypotension in spite of adequate fluid resuscitation and inotropes threatening end organ damage may benefit from vasopressor agents. But care must be taken to avoid inotropes and vasopressors in patients with significant LVOT. These agents may worsen the obstruction. Such patients may benefit from beta blockers and judicious preload increase if there's no pulmonary congestion. Phenylephrine a pure alpha agonist may reduce the gradient by increasing after load. Vasoconstrictive effects of phenylephrine may precipitate coronary vasospasm in those who are susceptible. Patients with or without LVOT and severe hypotension and not responding to medical management may require Intra-aortic balloon pump. Acute heart failure management is as per standard recommendations, including oxygen, assisted ventilation when required, intravenous diuretics and vasodilator therapy. Vasodilator therapy and fluid depletion should be avoided in patients with LVOT. Patients with severe LV dysfunction require anticoagulation to prevent thromboembolism, especially so in peri-partum patients with hypercoagulable state. This patients ejection fraction normalized within 8 days consistent with earlier reports.<sup>17</sup> In Hospital mortality is 2%, in hospital complication is 19% and recurrence rate is 5%.<sup>18</sup>

### **CONCLUSION**

Takotsubo cardiomyopathy is a stress related condition. Pregnancy is stressful condition. Twin pregnancy in an elderly primi is an additional stress factor. Physicians and Obstetricians treating such pregnant women should consider stress cardiomyopathy in differential diagnosis if they develop chest pain and shortness of breath with abnormal ECG, ECHO and elevated cardiac enzymes. It's a relatively self-limiting disease but can cause all the in hospital complications of acute myocardial infarction warranting a multidisciplinary approach. Relapse can



occur though rare, hence periodic follow up will be of additional value.

*Funding: No funding sources*

*Conflict of interest: None declared*

*Ethical approval: Not required*

## REFERENCES

1. Bybee KA, Kara T, Prasad A, Lerman A, Barsness GW, Wright RS, Rihal CS. Systematic review: transient left ventricular apical ballooning: a syndrome that mimics ST-segment elevation myocardial infarction. *Ann Int Med.* 2004;141(11):858-65.
2. Wittstein IS, Thiemann DR, Lima JA, Baughman KL, Schulman SP, Gerstenblith G, Wu KC, Rade JJ, Bivalacqua TJ, Champion HC. Neurohumoral features of myocardial stunning due to sudden emotional stress. *N Eng J Med.* 2005;352(6):539-48.
3. Gianni M, Dentali F, Grandi AM, Sumner G, Hiralal R, Lonn E. Apical ballooning syndrome or takotsubo cardiomyopathy: a systematic review. *Eur Heart J.* 2006;27(13):1523-9.
4. Prasad A, Dangas G, Srinivasan M, Yu J, Gersh BJ, Mehran R, et al. Incidence and angiographic characteristics of patients With apical ballooning syndrome (takotsubo/stress cardiomyopathy) in the HORIZONS-AMI trial: An analysis from a multicenter, international study of ST-elevation myocardial infarction. *Catheterizat Cardiovasc Intervent.* 2014;83(3):343-8.
5. Dec GW. Recognition of the apical ballooning syndrome in the United States. 2005;111:388-90.
6. Lochhead K. Managing the unknown: creating an obstetric care plan for a patient with a history of Takotsubo cardiomyopathy. *Eur J Obstet Gynecol a Reprod Biol.* 2016;206:e55.
7. Tsuchihashi K, Ueshima K, Uchida T, Oh-mura N, Kimura K, Owa M, et al. Transient left ventricular apical ballooning without coronary artery stenosis: a novel heart syndrome mimicking acute myocardial infarction. *J Am Coll Cardiol.* 2001;38(1):11-8.
8. Minatoguchi M, Itakura A, Takagi E, Nishibayashi M, Kikuchi M, Ishihara O. Takotsubo cardiomyopathy after cesarean: A case report and published work review of pregnancy-related cases. *J Obstet Gynaecol Res.* 2014;40(6):1534-9.
9. Templin C, Ghadri JR, Diekmann J, Napp LC, Bataiosu DR, Jaguszewski M, et al. Clinical features and outcomes of Takotsubo (stress) cardiomyopathy. *N Eng J Med.* 2015;373(10):929-38.
10. D'Amato N, Colonna P, Brindicci P, Campagna MG, Petrillo C, Cafarelli A, et al. Tako-Tsubo syndrome in a pregnant woman. *European J Echocardiography.* 2008;9(5):700-3.
11. Madhavan M, Borlaug BA, Lerman A, Rihal CS, Prasad A. Stress hormone and circulating biomarker profile of apical ballooning syndrome (Takotsubo cardiomyopathy): insights into the clinical significance of B-type natriuretic peptide and troponin levels. *Heart.* 2009;95(17):1436-41.
12. Kurowski V, Kaiser A, von Hof K, Killermann DP, Mayer B, Hartmann F, et al. Apical and midventricular transient left ventricular dysfunction syndrome (tako-tsubo cardiomyopathy) frequency, mechanisms, and prognosis. *Chest.* 2007;132(3):809-16.
13. Win CM, Pathak A, Guglin M. Not Takotsubo: A Different Form of Stress-Induced Cardiomyopathy-A Case Series. *Congestive Heart Failure.* 2011;17(1):38-41.
14. Eitel I, von Knobelsdorff-Brenkenhoff F, Bernhardt P, Carbone I. Clinical characteristics and cardiovascular magnetic resonance findings in stress (takotsubo) cardiomyopathy. *JAMA.* 2011;306(3):277-86.
15. Testa M, Feola M. Usefulness of myocardial positron emission tomography/nuclear imaging in Takotsubo cardiomyopathy. *World J Radiol.* 2014;6(7):502.
16. De Backer O, Debonnaire P, Gevaert S, Missault L, Gheeraert P, Muyldermans L. Prevalence, associated factors and management implications of left ventricular outflow tract obstruction in takotsubo cardiomyopathy: a two-year, two-center experience. *BMC cardiovascular disorders.* 2014;14(1):147.
17. Sharkey SW, Lesser JR, Zenovich AG, Maron MS, Lindberg J, Longe TF, Maron BJ. Acute and reversible cardiomyopathy provoked by stress in women from the United States. *Circulation.* 2005;111(4):472-9.
18. Sharkey SW, Windenburg DC, Lesser JR, Maron MS, Hauser RG, Lesser JN, Haas TS, Hodges JS, Maron BJ. Natural history and expansive clinical profile of stress (tako-tsubo) cardiomyopathy. *J Am Coll Cardiol.* 2010;55(4):333-41.

**Cite this article as:** Rao NBV, Rekha A, Sankar Narayan A, Manjusha A. Takotsubo cardiomyopathy complicating a twin pregnancy at partum. *Int J Res Med Sci* 2019;7:4375-8.