

Case Report

Idiopathic multilocular thymic cyst-an incidental anterior mediastinal mass

Sowmya S.*, Anbarasu Mohanraj, Karthik Raman, Bharath Kumar Mohandoss

Department of Cardiothoracic and Vascular Surgery, Institute of Cardiovascular Diseases, The Madras Medical Mission, Chennai, Tamil Nadu, India

Received: 09 September 2019

Revised: 12 September

Accepted: 05 October 2019

*Correspondence:

Dr. Sowmya S,

E-mail: sowms.sri@gmail.com

Copyright: © the author(s), publisher and licensee Medip Academy. This is an open-access article distributed under the terms of the Creative Commons Attribution Non-Commercial License, which permits unrestricted non-commercial use, distribution, and reproduction in any medium, provided the original work is properly cited.

ABSTRACT

Acquired thymic cyst are multilocular and they occur de novo or in association with mediastinal neoplasm, systemic autoimmune diseases and trauma. Here, we report a case of acquired multilocular thymic cyst due to non-specific inflammatory etiology in a 42-year old gentleman and our approach to diagnosis and management of anterior mediastinal mass. With no specific clinical symptom, he was diagnosed with anterior mediastinal mass incidentally by imaging studies. Definitive diagnosis of multilocular thymic cyst was obtained by tissue diagnosis of the anterior mediastinal mass resected during the surgery.

Keywords: Anterior mediastinal mass, Teratoma, Thymic cyst, Video-assisted thoracoscopic surgery

INTRODUCTION

Thymic cyst is rare benign anomaly found in the neck and mediastinum. They arise from the remnants of the thyropharyngeal duct, a derivative of third pharyngeal pouch. They may be congenital or acquired. They are usually asymptomatic and represent 1-3% of all anterior mediastinal masses.¹

It is difficult to distinguish thymic cysts from solid neoplasm of the thymus by imaging studies, especially for protein-rich cysts.² Thymic neoplasia cannot be confidently differentiated from multilocular thymic cyst on computed tomography, hence these lesions must undergo resection and careful histopathological examination.

Early surgical resection of the cyst is advocated because complications such as rupture of the cyst, malignant transformation or compression of the surrounding organs in the mediastinum, can arise. Hence staged approach to anterior mediastinal mass is ideal for definitive diagnosis and management.

CASE REPORT

A 42-Year old hypertensive male presented with history of headache and difficulty in breathing of New York Heart Association class 2 for the past 4 months. He was evaluated for the same three months ago, and his physical examination and routine laboratory investigations were insignificant. His postero-anterior and lateral chest radiograph revealed a parahilar left sided opacity (Figure 1) and two-dimensional echocardiography showed a large cystic mass measuring 80x70 mm causing external compression over the main pulmonary artery and left pulmonary artery (Figure 2). Computed tomography of the chest showed large well-defined cyst measuring 65x68 mm in the anterior mediastinum with no evidence of solid components. He was advised for elective surgical removal of the anterior mediastinal mass. He reviewed with us for excision of the mass 3 months later with repeat computed tomography of the chest showing large extra pericardial cystic lesion with multiple septations compressing the main and left pulmonary artery measuring 65x70 mm (Figure 3). On admission he was hemodynamically stable with heart rate of 88/min and blood pressure of 130/80 mmHg. His tumor

markers AFP-2.19, beta HCG- <3.47, LDH- 187 was within normal limits. An elective coronary angiogram showed normal epicardial coronaries with good left ventricular function. Mass was excised by median sternotomy (Figure 4).

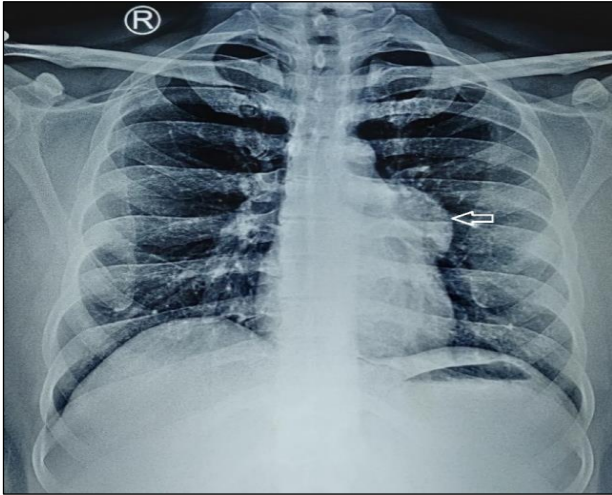


Figure 1: The chest radiograph showed a left sided parahilar opacity (arrow).

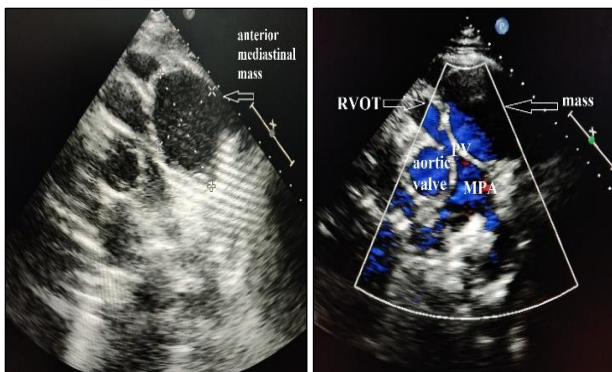


Figure 2: The 2D echocardiography showed anterior mediastinal mass compressing main pulmonary artery (MPA).

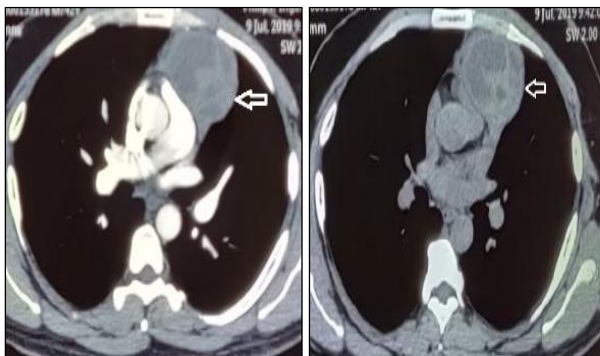

Figure 3: The chest computed tomography showed a large anterior mediastinal cystic mass lateralized to the left side likely to be cystic thymoma or a cystic teratoma (arrow).

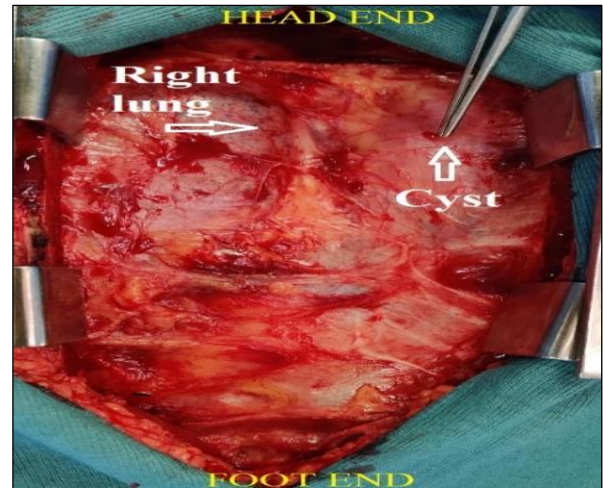


Figure 4: Intra operative picture showed a cystic mass in the anterior mediastinum.

Left pleura was opened for visualization of the entire mass. It was a well encapsulated mass, extra pericardial, thick walled, cystic in consistency (Figure 5).

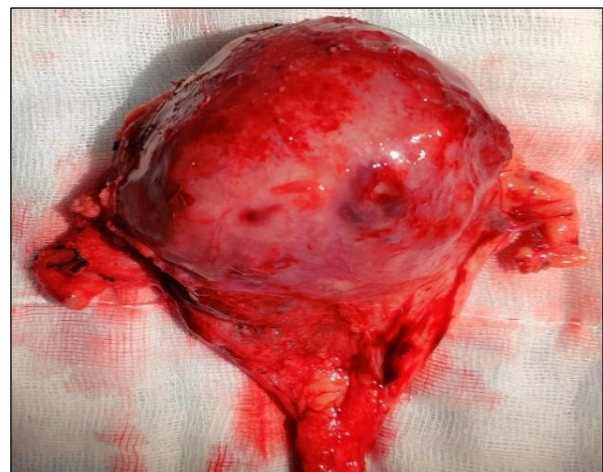

Figure 5: Excised anterior mediastinal mass.

Mass was excised with the entire mediastinal fat leaving pericardium intact and releasing adhesions to the left lung. Thorough warm saline wash was given, and hemostasis was achieved. Chest was closed in layers with a mediastinal drain tube. The specimen was sent for histopathological examination. Gross description of the mass was a single circumscribed cystic mass, externally covered by fibro fatty tissue and the cut specimen (Figure 6) revealed thick cyst wall with multiple septations and impacted hemorrhagic material. Microscopic description shows a fibro collagenous cyst wall with luminal blood clots and hemorrhage. Many cholesterol granulomas were seen with few multinucleated giant cells and foci of calcification. Cyst wall also showed thymic tissue with cuboidal epithelium and lymphocytic component. No atypia was noted (Figure 7). His postoperative period was uneventful, and he recovered well. He was discharged on

sixth postoperative day in a stable hemodynamic condition with scheduled outpatient follow ups.

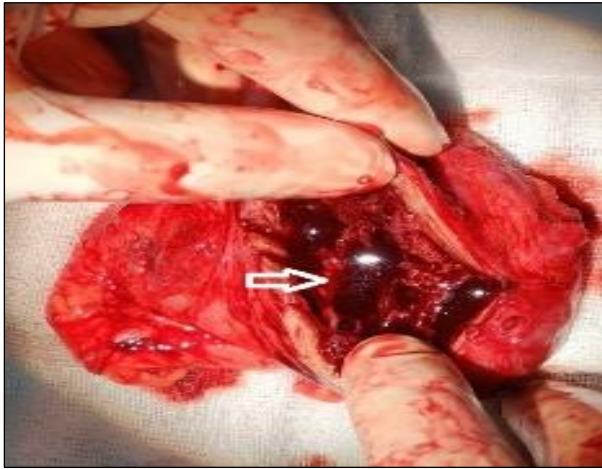


Figure 6: Cut section of the mass revealed a thick-walled cyst with multiple septations (arrow) and hemorrhagic fluid.

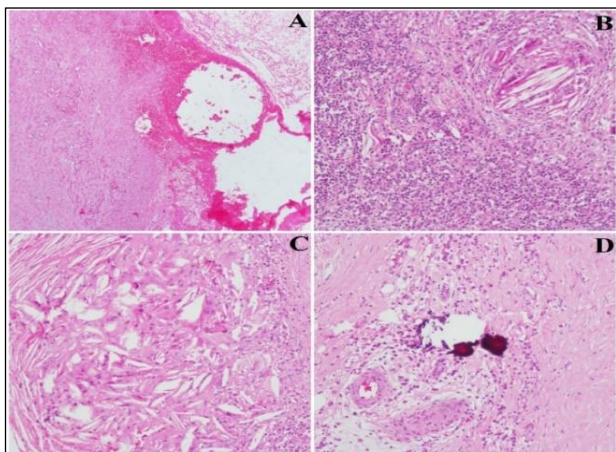


Figure 7: (A) Cyst wall with luminal haemorrhage; (B) Thymic tissue with cholesterol clefts; (C) Cholesterol granuloma; (D) Calcification within the cyst.

DISCUSSION

Thymic cysts are uncommon mediastinal lesions accounting for 3-5% of all mediastinal masses. They represent approximately 1-3% of anterior mediastinal masses.¹ They are usually asymptomatic and are detected incidentally on imaging. In case, a nonspecific headache with complaints of dyspnea on mild exertion and normal physical examination were inconclusive for a clinical diagnosis. Imaging by chest radiography revealed a diagnosis of left hilar lymphadenopathy or a mediastinal mass. Further imaging with computed tomography confirmed the diagnosis of anterior mediastinal heterogeneous well-defined solid cystic mass likely to be thymic cyst or teratoma. Intra operative diagnosis was hemorrhagic multilocular thymic cyst or a dermoid cyst.

Histopathological examination provided the definitive diagnosis in this case as the benign thymic cyst.

Multilocular thymic cysts are acquired lesions of the thymus and are most likely caused by an inflammatory process. In many cases, perhaps the most specific cause of inflammation is unknown.³ The chest X-ray can only be considered a screening examination. The chest CT is the most widely used imaging modality for mediastinal disease. For thymic cysts, the chest CT can describe the shape, contour, CT scan Hounsfield units, relationship to adjacent tissue, and the contrast-enhanced CT appearance. The typical imaging performance of the thymic cyst was oval in shape, and had a smooth contour, cystic density, homogeneous attenuation, and thin or imperceptible walls.⁴⁻⁶

Cystic teratoma cannot be confidently differentiated from multilocular thymic cyst because cystic teratoma commonly manifests as a unilocular or multilocular cystic mass and frequently calcifies. Identification of fat, cartilaginous, or tooth like calcification in the lesion suggests teratoma. Treatment of thymic cysts is based on surgical excision, which must be as complete as possible. In a study of 18 cases reported by Suster and Rosai, two patients presented a recurrence of the cyst due to an incomplete surgical excision.³

An increasing role of VATS has been established in excision of mediastinal cysts. It has the advantages of being minimally invasive, with better cosmetic and shorter hospital stay.⁷ Hung et al, operated 113 patients with anterior mediastinal mass using VATS. They had low conversion rate and complications.

Dense adhesions, relations to major vascular structures, communication of the cyst with tracheobronchial tree or esophagus, difficulty in controlling bleeding and failure to excise the mass into to add challenges to the procedure. VATS should be selected based upon experience, depth, location, size and relations of cyst.⁸ In this case, due to logistical difficulties and lesser expertise in VATS in our center, excision of the mass was performed by median sternotomy so as to guard against malignancy and for complete surgical removal and better visualization and also to release the adhesions with the left lung.

CONCLUSION

Mediastinal multilocular benign thymic cyst are rare and most likely result from inflammation. They are visualized as unilocular or multilocular cyst in computed tomography. Hence complete surgical excision with histopathological examination is essential for the definitive diagnosis and management.

Funding: No funding sources

Conflict of interest: None declared

Ethical approval: Not required

REFERENCES

1. Davis JW, Florendo FT. Symptomatic mediastinal thymic cysts. *Ann Thorac Surg.* 1988;46(6):693-4.
2. Vargas D, Suby-Long T, Restrepo CS. Cystic Lesions of the Mediastinum. *Semin Ultrasound CT MR.* 2016;37:212-2.
3. Suster S, Rosai J. Multilocular thymic cyst: an acquired reactive process. Study of 18 cases. *Am J Surg Pathol.* 1991;15(4):388-98.
4. Kent MS, Wang T, Gangadharan SP, Whyte RI. What is the prevalence of a nontherapeutic thymectomy? *Ann Thor Surg.* 2014;97(1):276-82.
5. Araki T, Sholl LM, Gerbaudo VH, Hatabu H, Nishino M. Intrathymic cyst: clinical and radiological features in surgically resected cases. *Clin Radiol.* 2014;69(7):732-8.
6. Jeung MY, Gasser B, Gangi A, Bogorin A, Charneau D, Wihlm JM. Imaging of cystic masses of the mediastinum. *Radiogr.* 2002;22(1):S79-93.
7. Martinod E, Pons F, Azorin J, Mouroux J, Dahan M, Faillon JM, et al. Thoracoscopic excision of mediastinal bronchogenic cysts: results in 20 cases. *Ann Thorac Surg.* 2000;69(5):1525-8.
8. Jung HS, Kim DK, Lee GD, Sim HJ, Choi SH, Kim HR, et al. Video-assisted thoracic surgery for bronchogenic cysts: is this the surgical approach of choice?. *Int Cardio Thorac Surg.* 2014;19(5):824-9.

Cite this article as: Sowmya S, Mohanraj A, Raman K, Mohandoss BK. Idiopathic multilocular thymic cyst-an incidental anterior mediastinal mass. *Int J Res Med Sci* 2019;7:4392-5.