

## Case Report

# Adult intestinal malrotation: a case report

Nyoman T. Pradiptha\*, Ketut Wiargitha

Department of Surgery, Medical Faculty of Udayana University, Sanglah Central General Hospital, Denpasar, Bali, Indonesia

**Received:** 16 September 2019

**Accepted:** 31 October 2019

**\*Correspondence:**

Dr. I. Nyoman Tri Pradiptha,  
E-mail: [pradiptha07@yahoo.com](mailto:pradiptha07@yahoo.com)

**Copyright:** © the author(s), publisher and licensee Medip Academy. This is an open-access article distributed under the terms of the Creative Commons Attribution Non-Commercial License, which permits unrestricted non-commercial use, distribution, and reproduction in any medium, provided the original work is properly cited.

### ABSTRACT

Midgut malrotation is an incomplete rotation of the intestine which occurs during foetal development and usually presents in the neonatal period. The bowel is not fixed adequately and is thus held by a precariously narrow-based mesentery. The incidence of malrotation has been estimated at 1 in 6000 live births, it is rare for malrotation to present in adulthood. Author report a 40-year-old man presented to emergency department with generalized abdominal pain. His symptoms began 2 days before admission. The patient really weak and his mental state was somnolence. His abdomen was slightly extended, and intestinal peristalsis was obscure. Abdominal X-rays revealed dilatation of gastric, coiled spring appearance without free air and step ladder pattern. The patient then underwent laparotomy exploration. Upon entering the abdomen, ileum was noted to completely mobilized and founded volvulus segment, a clockwise twisting three times, about 30 cm proximal from ICJ, and soon author released it. The ligament of Treitz misplaced, there was in the right lower quadrant, close by ICJ. Then about 110 cm segment of ileum necrotic, the rest of the small bowel was normal, author found internal hernia in the right lower quadrant and there was Ladd's band. Clinicians should be aware of this serious cause of abdominal pain. The diagnosis of malrotation in adulthood is often delayed. Complete resolution of acute obstruction or chronic abdominal pain is the result of a high index of suspicion for malrotation, appropriate diagnostic studies, and aggressive treatment.

**Keywords:** Generalized peritonitis, Intestinal malrotation, Midgut volvulus

### INTRODUCTION

Midgut malrotation is an anomaly of fetal intestinal rotation and fixation that usually presents within the first month of life. It is rare for malrotation to presenting adulthood.<sup>1</sup> Indeed, most adult patients are symptomatic and incidentally are discovered later in life at surgery for other conditions.<sup>2,3</sup>

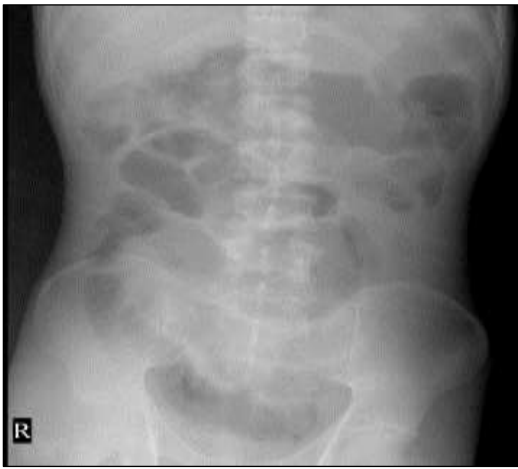
However, some adults may present acutely with bowel obstruction and intestinal ischemia due to midgut or caecal volvulus, or chronically with symptoms of intermittent bowel obstruction or vague abdominal complaints. Because presentation is nonspecific and the index of suspicion for malrotation progressively

decreases in the older population, the clinical diagnosis is usually not considered in the initial evaluation. Findings diagnostic of malrotation are described using several modalities such as barium studies, Computed Tomography (CT) scans and angiography.<sup>4</sup> Complete resolution of acute obstruction or chronic abdominal pain is the result of a high index of suspicion for malrotation, appropriate diagnostic studies, and aggressive definitive surgical treatment.

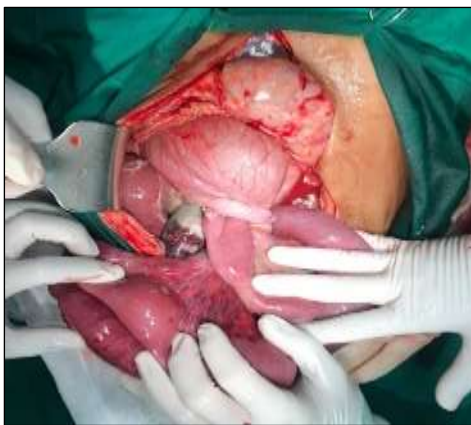Author present a case of malrotation in an adult who presented generalized abdominal pain, with mental state deterioration caused by septic condition and underwent emergency laparotomy.

## CASE REPORT

A Man, 40-year-old presented to emergency department with generalized abdominal pain. His symptom began 2 days prior admission and followed by deterioration mental status for 24 hours prior admission This pain recurred intermittently at the beginning, over by time, the recurrences were more persistent, not relieving by medicine. He vomited several times, two days before without relieve of nausea. His last bowel movement about three days. His history consisted of multiple similar episodes of postprandial abdominal pain and vomiting since her teenage years which remained unidentifiable as regards the cause. He had no other history of abdominal surgery. He was on no current medications.



**Figure 1: Abdominal X-rays revealed dilatation of gastric, coiled spring appearance without free air.**

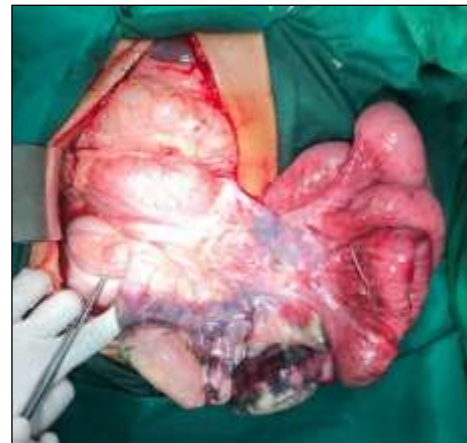

**Figure 2: Ileum was noted to completely mobilized and founded volvulus segment, a clockwise twisting three times, about 30 cm proximal from ICJ.**

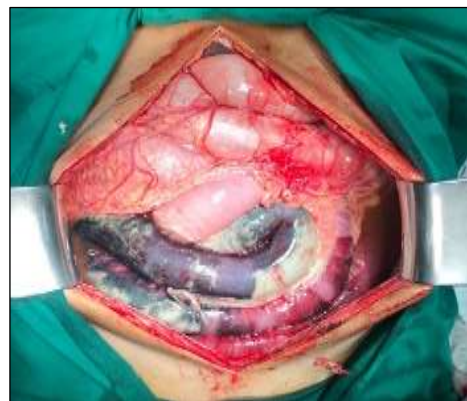Abdominal X-rays revealed dilatation of gastric, coiled spring appearance without free air on physical examination, the patient really weak and his mental state was somnolence, the patient's vital signs were pulse 108/min, blood pressure 100/70 mmHg, temperature 38.1 °C and respiratory rate 28/min. His abdomen was slightly

extended, and intestinal peristalsis was obscure. He exhibited peritoneal sign with intense guarding even on superficial palpation. His rectal examination was normal. White blood cell count increase with a sign of septic and blood gas analyze showed signs of metabolic acidosis. Abdominal X-rays (Figure 1) revealed dilatation of gastric, coiled spring appearance without free air and step ladder pattern. He was admitted and managed with nasogastric tube decompression and intravenous fluid hydration under continuous re-evaluation. Based on the sign of peritonitis and septic state, the patient was consented for exploratory laparotomy.

Upon entering the abdomen, ileum was noted to completely mobilized and founded volvulus segment, a clockwise twisting three times, about 30 cm proximal from ICJ, and soon author released it (Figure 2). The ligament of Treitz misplaced, there was in the right lower quadrant, close by ICJ, slightly extended and edematous (Figure 3). Then about 110 cm segment of ileum necrotic, the rest of the small bowel was normal, author found internal hernia in right lower quadrant and there was Ladd's band (Figure 4) (Figure 5).

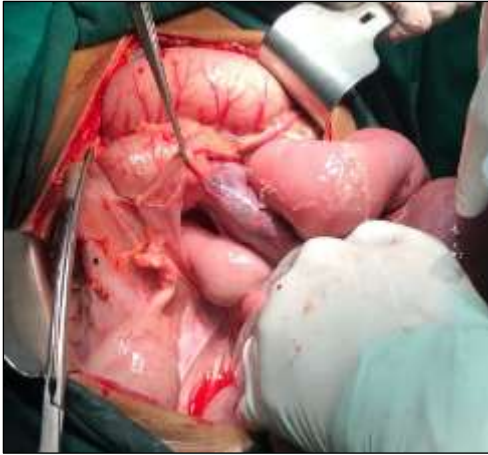

**Figure 3: The ligament of Treitz misplaced, there was in the right lower quadrant, close by ICJ, slightly extended and edematous.**



**Figure 4: About 110 cm segment of ileum necrotic, the rest of the small bowel was normal.**

During operation time, his hemodynamic unstable because of the septic state. That was forcing us to resect of necrotic part and performed double barrel ileostomy.



**Figure 5: We found internal hernia in right lower quadrant and there was a Ladd's band.**

Postoperative, the patient showed up improving the condition in an intensive care unit, and underwent closed ileostomy a week after surgery, and was discharged home on postoperative day 15. He has been in follow up in polyclinic, without any sign of recurrence.

## DISCUSSION

Midgut malrotation has been estimated to occur in approximately one in 500 live births.<sup>5</sup> Other epidemiology data showed intestinal malrotation is a congenital abnormality seen in up to 1: 6000 live births.<sup>6</sup> However, it is difficult to accurately ascertain the true incidence because this condition will go undetected during childhood in a substantial subset of patients. In adulthood, intestinal malrotation is estimated to occur in 0,2% to 0,5%.<sup>7,8</sup> A literature review by von Flue et al. cites 40 cases from 1923 to 1992.<sup>4</sup>

Intestinal malrotation can be broadly defined as any deviation from the normal 270 degrees counterclockwise rotation of the midgut. During fetal development, the midgut supplied by the superior mesenteric artery grows too rapidly to be accommodated in the peritoneal cavity. Prolapse into the umbilical cord occurs around the sixth week. Between the tenth and twelfth week, the midgut returns to the abdominal cavity, having undergone 270-degree counterclockwise rotation around the superior mesenteric artery. This rotation of intestinal development has been divided into 3 stages. Stage I occurs in weeks 5 to 10. It includes extrusion of the midgut into the extraembryonic cavity, a 90 counterclockwise rotation and return of the midgut into the fetal abdomen. Stage II occurs in week 11 and involves further counterclockwise rotation within the abdominal cavity completing a 270-degree rotation. The duodenum rotates caudal to the artery, and its C-loop traces this path. The transverse and

ascending colon demonstrate the path of rotation of the caecum cephalad to the artery. Stage III involves fusion and anchoring of the mesentery. The duodenum becomes fixed retroperitoneally in its third portion, emerging at the ligament of Treitz, and the cecum becomes fixed to the lateral abdominal wall by peritoneal bands. The take-off of the branches of the superior mesenteric artery elongates and becomes fixed along a line extending from its emergence from the aorta to the cecum in the right lower quadrant.<sup>9</sup>

Intestinal anomalies can be categorized by the stage of their occurrence. Stage I anomalies include omphaloceles caused by failure of the gut to return to the abdomen. Stage II anomalies include nonrotation, malrotation, reversed rotation, and preduodenal hernias. Stage III anomalies include an unattached duodenum, mobile cecum, and an unattached small bowel mesentery.<sup>9</sup>

If rotation is incomplete, the cecum remains in the epigastrium but the bands fixing the duodenum to the retroperitoneum and cecum continue to form. These bands (Ladd's bands), extending from the cecum to the lateral abdominal wall and crossing the duodenum, have the potential to cause obstruction.<sup>10</sup> The mesenteric take off remains confined to the epigastrium, resulting in a narrow pedicle suspending all the branches of the superior mesenteric artery and the entire midgut. A volvulus may occur around the mesentery, obstructing the jejunum and also cutting off the blood supply to the midgut. Intestinal obstruction and the potential for total vascular compromise of the midgut supervene unless the condition is corrected.

Not all patients with malrotation present with symptoms. Indeed, most adult patients are asymptomatic and incidentally discovered later either at surgery for other conditions or at autopsy.<sup>3</sup> Symptoms can arise from acute or chronic intestinal obstruction that may be caused by the presence of the Ladd's bands and/or a volvulus.

There is no typical set of symptoms that are described to this clinical syndrome. The location of the pain may vary from epigastric to the left upper abdominal quadrant and it may be described as either intermittent cramping or persistent aching pain. It most often occurs postprandially and may last several minutes to an hour. Some authors postulate that diarrhea and malabsorption may be caused by bowel lymphedema resulting from lymphatic obstruction by chronic volvulus and resulting in loss of proteins into the bowel lumen.<sup>11</sup>

The diagnosis of malrotation in adulthood is often delayed, because of the wider and more obscure constellation of clinical symptoms observed in adult patients, which leads clinicians and patients to attribute symptoms to the wrong diagnosis. All too often, such patients undergo numerous investigational tests and carry diagnostic labels such as irritable bowel syndrome, peptic ulcer diseases or psychogenic disorder.<sup>12,13</sup>

The diagnosis of intestinal malrotation can be made by radiographic studies.<sup>14</sup> Conventional radiography is neither sensitive nor specific for malrotation, although right-sided jejunal markings and the absence of a stool-filled colon in the right lower quadrant may be suggestive of this finding.<sup>15</sup>

The standard upper GI barium series remains accurate for detection (accuracy over 80%) and the rules familiar to pediatric radiology also apply for adults—that is, the duodenal-jejunal junction fails to cross the midline and lies below the level of the duodenal bulb.<sup>15</sup>

Contrast enema examination usually shows malposition of the right colon with the ileum entering the cecum from the right, but the cecum may assume a normal location in up to 20% patients. This normal location may cause malrotation to be missed on this type of study.<sup>9,16</sup> The contrast enema finding is also nonspecific because cecal location can be variable without malrotation.

Many cases of quiescent malrotation in adults are currently being detected on cross-sectional imaging (particularly CT) performed for various unrelated reasons.<sup>17</sup> CT not only shows the intestinal malpositioning seen on barium studies but also depicts associated extraintestinal findings not evident on conventional examination. For example, deviation from the normal relationship between the Superior Mesenteric Artery (SMA) and Superior Mesenteric Vein (SMV) is a useful indicator of malrotation.<sup>18</sup> In most patients with quiescent malrotation, the SMA and SMV will assume a vertical relationship of show left-right inversion.<sup>17</sup> Abnormalities of SMA-SMV orientation are not entirely diagnostic, however, because some patients with malrotation will have a normal relationship, and a vertical or inverted relationship can also be seen in patients without malrotation.<sup>17</sup> Therefore, isolated detection of such an abnormality is not sufficient for diagnosis but should warrant a closer examination of the bowel.

Midgut volvulus, a clockwise twisting of the bowel around the SMA axis because of the narrowed mesenteric attachment, is the most feared complication of intestinal malrotation and a clear indication for emergent surgery. The clinical diagnosis of midgut volvulus in adolescents and adults is difficult because the presentation is usually nonspecific and malrotation is rarely considered. Recurrent episodes of colicky abdominal pain with vomiting for months or years are typical and may eventually lead to imaging.<sup>17</sup> Diarrhea and malabsorption from chronic venous lymphatic obstruction may also occur. Findings on abdominal radiographs in midgut volvulus are usually abnormal but non-specific. The upper gastrointestinal examination shows the typical corkscrew appearance of the proximal small bowel. However, in older patients with acute symptoms, CT is generally performed instead of a barium examination. Fortunately, the CT findings of malrotation with midgut volvulus are characteristic. The CT whirl or whirlpool

sign describes the swirling appearance of bowel and mesentery twisted around the SMA axis.<sup>15,17</sup> A similar appearance can be seen on sonography. Additional CT findings include duodenal obstruction, congestion of the mesenteric vasculature, and evidence of underlying malrotation. The presence of intestinal ischemia or necrosis is an ominous sign.

The classic treatment for incomplete intestinal rotation is the Ladd procedure, which entails counterclockwise detorsion of the midgut volvulus (if present), division of the abnormal colo duodenal ladd bands tethering the midgut and causing extrinsic compression, widening of the mesenteric base to prevent further volvulus and removal of the malposition appendix.<sup>19</sup> These principles have remained the same since Ladd's address to the New Hampshire Medical Society in 1936.<sup>8</sup> Generally, symptomatic patients with malrotation should be treated surgically. Moreover, Spigland et al, recommended that all patients with malrotation are candidates for laparotomy, even if they are asymptomatic, because the complications associated with intestinal malrotation are based on anatomical reasons that do not alter with age, thus the potential to develop sudden onset of acute midgut volvulus in an asymptomatic patient, at any age, exists.<sup>3</sup>

Recently, laparoscopic techniques for treating malrotation in both infants and adults have been described. Mazziotti et al, recently reported a series of malrotation patients managed successfully with laparoscopic intervention.<sup>8</sup> Moreover, Matzke et al, published their comparative results for open and laparoscopic Ladd procedures, concluding that the laparoscopic Ladd procedure is feasible, safe and as effective as the standard open Ladd procedure for the treatment of adults who have intestinal malrotation without midgut volvulus.<sup>13</sup>

## CONCLUSION

The clinical diagnosis of malrotation after childhood is usually not considered, because of the rare incidence of the disorder. These patients often present with obstruction and ischemia associated with a volvulus, or with chronic abdominal pain with elations, as in this case. Diagnosis requires a high index of suspicion. Specific findings that are diagnostic of malrotation can be detected through the use of both upper and lower gastrointestinal tract barium studies, angiography of the superior mesenteric artery, CT scan and often emergency laparotomy. Treatment remains as it was originally described by Ladd in 1936: mobilization of the right colon and duodenum, division of Ladd's bands, division of adhesion around the superior mesenteric artery and appendectomy. Complete resolution of acute obstruction or chronic abdominal pain is the result of a high index of suspicion for malrotation, appropriate diagnostic studies, and aggressive definitive treatment.

*Funding: No funding sources*

*Conflict of interest: None declared*

*Ethical approval: Not required*

## REFERENCES

1. Powell DM, Othersen HB, Smith CD. Malrotation of the intestines in children: the effect of age on presentation and therapy. *J Pediatr Surg.* 1989 Aug 1;24(8):777-80.
2. Fukuya T, Brown BP, Lu CC. Midgut volvulus as a complication of intestinal malrotation in adults. *Diges Dis Sci.* 1993 Mar 1;38(3):438-44.
3. Spigland N, Brandt ML, Yazbeck S. Malrotation presenting beyond the neonatal period. *J Pediatr Surg.* 1990 Nov 1;25(11):1139-42.
4. von Flüe M, Herzog U, Ackermann C, Tondelli P, Harder F. Acute and chronic presentation of intestinal nonrotation in adults. *Dis Col Rec.* 1994 Feb 1;37(2):192-8.
5. Torres AM, Ziegler MM. Malrotation of the intestine. *World J Surg.* 1993 May 1;17(3):326-31.
6. Fischer JE, Bland KI, Callery MP, editors. *Mastery of surgery.* Lippincott Williams and Wilkins; 2006 Dec 18.
7. Frantzides CT, Cziperle DJ, Soergel K, Stewart E. Laparoscopic Ladd procedure and cecopexy in the treatment of malrotation beyond the neonatal period. *Surg Laparoscopy Endo.* 1996 Feb 1;6(1):73-5.
8. Mazziotti MV, Strasberg SM, Langer JC. Intestinal rotation abnormalities without volvulus: the role of laparoscopy. *J Am Coll Surg.* 1997 Aug 1;185(2):172-6.
9. Monty ML, Gohl MC. Midgut Nonrotation in Adults. *Am J Surg.* 1975;129:319-23.
10. Ladd WE. Congenital obstruction of the duodenum in children. *New Eng J Med.* 1932 Feb 11;206(6):277-83.
11. Brandt ML, Pokorny WJ, McGill CW, Harberg FJ. Late presentations of midgut malrotation in children. *Am J Sur.* 1985 Dec 1;150(6):767-71.
12. Spitz L, Orr JD, Harries JT. Obstructive jaundice secondary to chronic midgut volvulus. *Arch Dis Child.* 1983 May 1;58(5):383-5.
13. Matzke GM, Dozois EJ, Larson DW, Moir CR. Surgical management of intestinal malrotation in adults: comparative results for open and laparoscopic Ladd procedures. *Surg Endo Int Tech.* 2005 Oct 1;19(10):1416-9.
14. Pickhardt PJ, Bhalla S. Intestinal malrotation in adolescents and adults: spectrum of clinical and imaging features. *Am J Roentgenol.* 2002 Dec;179(6):1429-35.
15. Berdon WE. The diagnosis of malrotation and volvulus in the older child and adult: a trap for radiologists. *Pediatr Radiol.* 1995 Mar 1;25(2):101-3.
16. Maxson RT, Franklin PA, Wagner CW. Malrotation in the older child: surgical management, treatment, and outcome. *Am Surg.* 1995 Feb;61(2):135-8.
17. Zissin R, Rathaus V, Oscadchy A, Kots E, Gayer G, Shapiro-Feinberg M. Intestinal malrotation as an incidental finding on CT in adults. *Abdominal Imaging.* 1999 Nov 1;24(6):550-5.
18. Nichols DM, Li DK. Superior mesenteric vein rotation: a CT sign of midgut malrotation. *Am J Roentgenol.* 1983 Oct 1;141(4):707-8.
19. Schulz LS, Lasher EP, Bill AH. Abnormalities of rotation of the bowel. *Am. J. Surg.* 1961;101:128-33.

**Cite this article as:** Pradiptha NT, Wiargitha K. Adult intestinal malrotation: a case report. *Int J Res Med Sci* 2019;7:4807-11.