

Original Research Article

Surgical importance of distance from mandibular condyle to carotid canal and foramen spinosum: an anatomical study

Sangeetha Arumugam¹, Nandha Kumar Subbiah^{2*}

¹Department of Anatomy, Katuri Medical College and Hospital, Guntur, Andhra Pradesh, India

²Department of Anatomy, All India Institute of Medical Sciences, Mangalagiri, Andhra Pradesh, India

Received: 13 October 2019

Revised: 03 November 2019

Accepted: 08 November 2019

*Correspondence:

Dr. Nandha Kumar Subbiah,

E-mail: snandha@gmail.com

Copyright: © the author(s), publisher and licensee Medip Academy. This is an open-access article distributed under the terms of the Creative Commons Attribution Non-Commercial License, which permits unrestricted non-commercial use, distribution, and reproduction in any medium, provided the original work is properly cited.

ABSTRACT

Background: The objective of this study was to compare the distance from mandibular condyle to internal carotid artery and middle meningeal artery.

Methods: In this study 20 skulls obtained from the Department of Anatomy were utilized for the study. The following two parameters were measured using Vernier Caliper (digital). 1. Distance from Mandibular condyle to carotid canal 2. Distance from medial margin of Mandibular condyle to Foramen spinosum. All the measurements were taken thrice to minimize errors. Photograph of the skull base showing the measurements done was captured.

Results: A total of 40 sides, 20 right and 20 left sides were studied. The mean distance between medial margin of mandibular condyle to carotid canal was 11.2 mm±0.6 on right side and 11.6mm±0.8 on left side. The mean distance from the medial margin of mandibular condyle to Foramen spinosum (middle meningeal artery) was 9.3 mm±1.1 on right side and 9.8mm±0.9 on left side.

Conclusions: The distance between mandibular condyle to Middle meningeal artery is less compared to the distance between Mandibular condyle to carotid artery. The current study concludes that MMA is comparatively at high risk for damage compared to internal carotid artery.

Keywords: Carotid canal, Foramen spinosum, Internal carotid artery, Middle meningeal artery, Temporomandibular joint

INTRODUCTION

Infratemporal Fossa (ITF) is an area under the middle cranial fossa. It is bounded medially by lateral pterygoid muscle, laterally by condylar process and ramus of mandible. Roof is formed by greater wing of sphenoid and has foramen ovale and spinosum for the passage of mandibular nerve and Middle Meningeal Artery (MMA) respectively.^{1,2} Posteriorly, it is related to carotid sheath and its contents. Carotid sheath encloses Internal Carotid Artery (ICA), internal jugular vein and vagus nerve.³ The proximity of the medial aspect of the Temporomandibular Joint (TMJ) to the vessels and nerves of the infratemporal fossa raises the potential risk

of damage and complications associated with TMJ surgery on the medial aspect of the joint.⁴ Many studies have reported the complications of damage of nerves and arteries associated with TMJ surgery.⁵ Earlier studies have demonstrated the close proximity of an arthroscopy puncture site to the superficial temporal artery and vein.^{6,7} Moses et al, reported pseudoaneurysm and arteriovenous malformation of the superficial temporal artery and vein associated with arthroscopic TMJ surgery.⁸ Vascular injury also involves vessels medial and deep to the joint. Middle Meningeal Artery (MMA) and internal carotid artery are two important vessels in relation to medial aspect of joint which are at high risk for injury. Radical condylectomy done for the release of TMJ ankylosis

predisposes to middle meningeal artery injury.⁹ Intrapetrous part of ICA passes through carotid canal present in the floor of temporal bone. Chuong et al, reported occurrence of sinus bradycardia during surgery of TMJ due to carotid artery involvement.¹⁰ Very few literatures have been reported on the distance of vessels in relation to the medial capsule of TMJ. Hence, understanding the anatomic relationship of the main vessels to the TMJ is of utmost importance to prevent intra-operative or postoperative complications. The aim of the present study was to compute the anatomical relationship of the vessels of infratemporal fossa to TMJ and its importance during surgeries.

METHODS

The study was undertaken using twenty (20) dry skull bones used for teaching undergraduate medical students in the Department of Anatomy, Katuri Medical College and Hospital (KMCH), Andhra Pradesh, India (Study period; April 2019 to July 2019). Adult dry skull bones with intact carotid canal, foramen spinosum and mandibular fossa were included in the study wherein broken, disfigured, anomalous and foetal skull bones were excluded. All the measurements were made bilaterally using a Vernier calliper (Digital) so that a total of 40 sides were studied. Measurements were taken three times on each side for the parameters outlined below and the average between them were recorded. Photographs of the specimens were taken to document each skull's unique anatomy. The following parameters were measured (Figure 1).

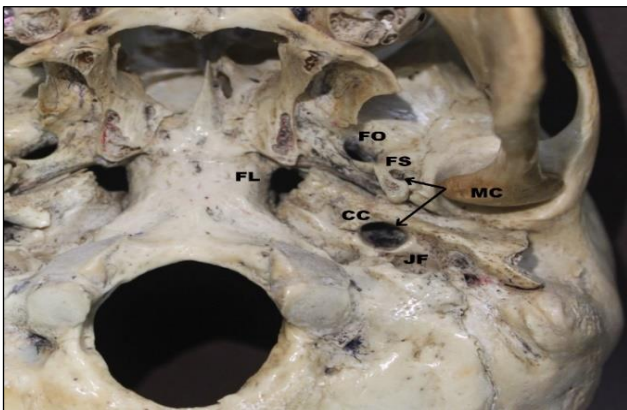


Figure 1: Skull base showing relation of medial margin of Mandibular Condyle (MC) to Carotid canal (CC) and Foramen spinosum (FS).

MC: Mandibular Condyle, CC: Carotid canal, FS: Foramen spinosum, FO: Foramen ovale, FL: Foramen lacerum, JF: Jugular fossa

- Distance from medial margin of Mandibular condyle to carotid canal
- Distance from medial margin of Mandibular condyle to Foramen spinosum

Statistical analysis

The continuous data were presented as mean, standard deviation, maximum and minimum. All data were analysed using the Statistical Package for Social Sciences (SPSS; Chicago, IL, USA) program, version 15.

RESULTS

After compiling the observations and using SPSS software, the following results were obtained, which are arranged in tabular form as shown in Table 1. The study was conducted in 20 skulls and measurements were taken on both sides, so a total of 40 sides were studied. Out of 40, 20 were right and 20 were left. The maximum and minimum distance between mandibular condyle to carotid canal was 12 mm and 10 mm on right side and 13.2mm and 10mm on left side respectively. But the mean distance between medial margin of mandibular condyle to carotid canal was 11.2mm±0.6 on right side and 11.6mm±0.8on left side. The maximum and minimum distance between mandibular condyle to foramen spinosum was 11 mm and 7 mm on right side and 11 mm and 8 mm on left side respectively. The mean distance from the medial margin of mandibular condyle to foramen spinosum (middle meningeal artery) was 9.3 mm±1.1 on right side and 9.8mm±0.9 on left side.

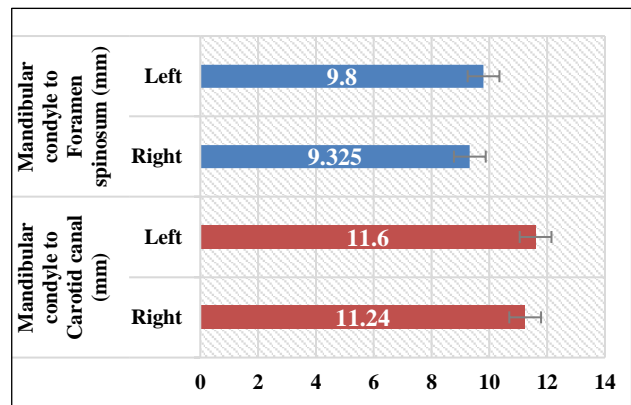


Figure 2: Comparison of measurements between mandibular condyle to carotid canal and foramen spinosum.

Comparison of these mean values between mandibular condyle to carotid canal and foramen spinosum on both sides is shown in (Figure 2). The present study showed that there were small differences in the mean values of distance between mandibular condyle to carotid canal on right and left sides which were statistically insignificant. Similarly, small differences in mean values between mandibular condyle to foramen spinosum were observed, which was statistically insignificant. However, on comparison of values of each side there was significant difference, right side showed least distance of 9.3±1.1 from mandibular condyle to foramen spinosum in comparison to 11.24±0.6 from mandibular condyle to carotid canal. Hence, the obtained values show that

foramen spinosum is closer to mandibular condyle than carotid canal on both the sides with right side being the least distance.

Table 1: Measurements between mandibular condyle to carotid canal and foramen spinosum.

Skull no.	Carotid canal to mandibular condyle (mm)		Foramen spinosum to mandibular condyle (mm)	
	Right	Left	Right	Left
1	11	12	7	9
2	12	13.2	9	10
3	12	13.1	8	9
4	11	12	9	10
5	12	12	10	10.5
6	12	11	9	10
7	12	11.5	11	11
8	11.5	12	10	11
9	11	11.5	9	10
10	11	11.6	11	9
11	11	12.5	10	8
12	11.5	10	9	9
13	10	11	9	10.5
14	11	11	9	10
15	12	10.5	10	11
16	11	10.8	11	11
17	10.8	11.5	10.5	11
18	10.5	11	8	9
19	11	11.8	8	8
20	10.5	12	9	9
Mean±sd	11.24±0.6	11.6±0.8	9.32±1.1	9.8±0.9

DISCUSSION

Surgical anatomy of Infratemporal Fossa (ITF) and the structures present in it are very crucial for surgeries involving ITF and TMJ. Normal anatomy of this region is disturbed in case of tumors leading to complications during surgeries mostly due to injury of vessels and nerves. TMJ is related to the lateral wall of ITF and is composed of the temporal bone above and the condyle of mandible below, and an articular disk separating the joint into two compartments.¹¹ TMJ ankylosis is a fusion of these joint surfaces. Various surgical procedures have been established for the treatment of TMJ ankylosis. These include gap arthroplasty, interposition arthroplasty, and total joint reconstruction. 6 Complications after TMJ surgeries could be intracranial or extracranial. Extracranial complications are likely to involve superficial temporal vessels, maxillary artery, Middle Meningeal Artery (MMA) and Internal Carotid Artery (ICA).⁷ Intracranial complications such as Extra Dural Hemorrhage (EDH) due to rupture of an MMA is life threatening.¹²⁻¹⁴

Ramat Braimah et al, did a retrospective study in Nigerian patients with TMJ Ankylosis and they observed

that massive intraoperative hemorrhage was observed as a complication in 4 patients who underwent condylar and coronoid osteotomies. This is attributed to the vessel wall rupture on the medial side of TMJ. The study concluded that it is due to the lack of preoperative CT scan based assessment of distance of vessels from mandibular condyle.⁸ Further, Zakaria et al, reported that the distances from the mandibular condyle to internal carotid artery, internal jugular vein, maxillary artery respectively were reduced in TMJ Ankylosis patients when compared to patients without ankyloses.¹⁵ Vranis et al, studied facial trauma patients with mandibular condyle fractures and found ICA injury in 5.5% of the subjects.¹⁶ ICA injury could occur due to medial dislocation of the condylar head with impingement of the carotid artery, medial dislocation of the inferior fragment of the condylar fracture, posterior translation of the ramus as it may compress the ICA against the vertebral transverse process. The above studies emphasize the need to ascertain the anatomical relation of vessels and nerves to the TMJ/ mandibular condyle.

In the quest to establish the anatomic relations of vessels to TMJ, various authors have taken several bony landmarks to measure the distance of vessels to TMJ. Talebzadeh et al, measured the transverse distance from the carotid artery to the zygomatic arch. This ranged from 29 mm to 48 mm.¹⁷ The authors chose zygomatic arch as a landmark as it is easily visible during surgery. Alonso F et al, measured the distance between the medial edge of the mandibular condyle to the lateral edge of the proximal carotid canal and the measurements were 1.03 cm and 1.11 cm on right and left sided sides respectively. In the current study, author measured the distance between the medial margin of mandibular condyle to outer margin of carotid canal and the mean value was 11.24 mm (1.12 cm) on right side and 11.6mm (1.16 cm) on the left side as shown in (Table 1). The values of the present study were in lines with the values reported by Alonso et al. Hence, mandibular condyle is an important landmark as this area is simple to identify and often involved during osteotomies.

The average distance between Zygomatic arch to Middle meningeal artery was 21 mm irrespective of the sides as reported by Talebzadeh et al, Sharma et al, reported a case of post-operative drowsiness following TMJ replacement surgery.¹⁷ On CT scan examination, it was diagnosed as EDH secondary to MMA rupture.^{18,19} The close proximity of the MMA to the medial capsule could increase the risk of hemorrhage during TMJ surgery.

To this knowledge, current study is the first to measure the distance between medial margin of mandibular condyle to foramen spinosum. Middle meningeal artery, a branch from first part of Maxillary artery, enters the skull through foramen spinosum following a brief course in the infra temporal fossa. The average distance between medial margin of mandibular condyle and foramen spinosum was 9.3 mm and 9.8 mm on right and left side

respectively, but the least distance was 7 mm on right side and 8 mm on left side as shown in Table 1. One of the clinically significant findings of the present study is the proximity of middle meningeal artery to mandibular condyle compared to that of carotid canal. Hence, the chances of iatrogenic damage/ injury to Middle Meningeal Artery is high in comparison to internal carotid artery. Anatomic knowledge of these measurements is crucial to the clinician with regard to TMJ surgeries.

CONCLUSION

An understanding of the relevant anatomy of structures medial to TMJ is vital for the surgeons. To this knowledge, the present study is the first to report comparative distance between mandibular condyle and two important vessels (ICA and MMA) medial to it. This report indicates that MMA is relatively closer to TMJ and hence author suggest that the distance between mandibular condyle and foramen spinosum should be measured preoperative to TMJ surgeries by CT imaging to prevent complications.

Funding: No funding sources

Conflict of interest: None declared

Ethical approval: Not required

REFERENCES

- Sue B. External skull. In: Standring S, eds. Gray's Anatomy: The Anatomical Basis of Clinical Practice. 41st ed. Philadelphia: Elsevier Limited; 2016: 416-428.
- Bergman RA, Tubbs RS, Shoja MM, Loukas M, editors. Bergman's comprehensive encyclopedia of human anatomic variation. John Wiley and Sons; 2016;1:21.
- Lang J. Skull Base and Related Structures: In: Lang J, eds. Atlas of Clinical Anatomy. London: Schattauer.; 1999:179-184.
- Alonso F, Bernard S, Irwin PA, Tubbs RI, Iwanaga J, Loukas M, et al. The relationship between the carotid canal and mandibular condyle: an anatomical study with application to surgical approaches to the skull base via the infratemporal fossa. *Anat.* 2016;10(3):193-9.
- Cuccia AM, Caradonna C, Caradonna D, Anastasi G, Milardi D, Favalaro A, et al. The arterial blood supply of the temporomandibular joint: an anatomical study and clinical implications. *Imag Sci Dentistr.* 2013;43(1):37-44.
- Bejjani GK, Sullivan B, Salas-Lopez E, Abello J, Wright DC, Jurjus A, et al. Surgical anatomy of the infratemporal fossa: the styloid diaphragm revisited. *Neurosurg.* 1998;43(4):842-52.
- Holmlund A, Hellsing G. Arthroscopy of the temporomandibular joint: an autopsy study. *Intern J Oral Surg.* 1985;14(2):169-75.
- Westesson PL, Eriksson L, Liedberg J. The risk of damage to facial nerve, superficial temporal vessels, disk, and articular surfaces during arthroscopic examination of the temporomandibular joint. *Oral Surg, Oral Med, Oral Pathol.* 1986;62(2):124-7.
- Moses JJ, Topper DC. Arteriovenous fistula: an unusual complication associated with arthroscopic temporomandibular joint surgery. *J Oral Maxillofacial Surg.* 1990;48(11):1220-2.
- Braimah R, Taiwo A, Ibikunle A, Oladejo T, Adeyemi M, Adejobi F, et al. Clinical experience in managing temporomandibular joint ankylosis: five-year appraisal in a Nigerian subpopulation. *J Korean Associat Oral Maxillofacial Surg.* 2018;44(3):112-9.
- Chuong R, Piper MA. Sinus bradycardia related to temporomandibular joint surgery. *Oral Surg, Oral Med, Oral Pathol.* 1991;71(4):423-5.
- Vrionis FD, Cano WG, Heilman CB. Microsurgical anatomy of the infratemporal fossa as viewed laterally and superiorly. *Neurosurg.* 1996;39(4):777-87.
- Cheyne F, Chossegros C, Blanc JL, Gola R, Lachard J. Complications of temporo-mandibular arthroscopy. Report of 100 arthroscopies. *Revue de Stomatologie Chirurgie Maxillo-faciale.* 1992;93(4):252-7.
- Carroll A, Smith K, Jakubowski JT. Extradural haematoma following temporomandibular joint arthrocentesis and lavage. *British J Neurosurg.* 2000;14(2):152-4.
- Murphy MA, Silvester KC, Chan TY. Extradural haematoma after temporomandibular joint arthroscopy: A case report. *Intern J Oral Maxillofacial Surg.* 1993;22(6):332-5.
- Zakaria A, Salma A, Jinane K, Naouar I, Nadia MH. Temporomandibular Joint Ankylosis: An Epidemiological Study in Marrakesh. *Am J Med Sci and Med.* 2018; 6(2):37-40.
- Vranis NM, Mundinger GS, Bellamy JL, Schultz BD, Banda A, Yang R, et al. Extracapsular mandibular condyle fractures are associated with severe blunt internal carotid artery injury: analysis of 605 patients. *Plast Reconstruct Surg.* 2015;136(4):811-21.
- Talebzadeh N, Rosenstein TP, Pogrel MA. Anatomy of the structures medial to the temporomandibular joint. *Oral Surg, Oral Med, Oral Pathol, Oral Radiol, Endodontol.* 1999;88(6):674-8.
- Sharma V, Bhatia PS, Kumar M, Pawar M. Extradural hematoma following temporomandibular joint interposition arthroplasty. *Anesth Essays Res.* 2017;11(2):522.

Cite this article as: Arumugam S, Subbiah NK. Surgical importance of distance from mandibular condyle to carotid canal and foramen spinosum: an anatomical study. *Int J Res Med Sci* 2019;7:4733-6.