

Original Research Article

Computerized tomography based evaluation of level I and II axillary lymph nodes by high conventional tangential fields in carcinoma breast

Lalit Chandrakant¹, Shabnum Thakur^{1*}, Manoj Gupta², Rajeev K. Seam³, Manish Gupta¹, Sanjeev Sharma⁴

¹Department of Radiotherapy and Oncology, IGMC Shimla, Himanchal Pradesh, India

²Department of Radiotherapy and Oncology, AIIMS, Rishikesh, Uttarakhand, India

³Department of Radiotherapy and Oncology, M.M.U, Ambala, Haryana, India

⁴Department of Radiology, IGMC Shimla, Himanchal Pradesh, India

Received: 18 December 2019

Revised: 17 December 2019

Accepted: 27 December 2019

*Correspondence:

Dr. Shabnum Thakur,

E-mail: thakurshabnum7@gmail.com

Copyright: © the author(s), publisher and licensee Medip Academy. This is an open-access article distributed under the terms of the Creative Commons Attribution Non-Commercial License, which permits unrestricted non-commercial use, distribution, and reproduction in any medium, provided the original work is properly cited.

ABSTRACT

Background: Axillary radiation and surgery have provided equivalent local control in early breast cancer patients. It is believed that tangential field (TF) radiation that was used to treat the breast coincidentally delivered radiation treatment to the lower axilla and eradicated the disease. In the era of CT-based three dimensional- (3D) radiotherapy planning, however concerns have been raised about the adequacy of coverage of the axillary levels in the tangential fields. In this study, author evaluated the coverage of the axillary nodal levels I and II using high conventional tangential fields in patients with or without axillary dissection.

Methods: A prospective study was conducted which included 18 cases for a period of one year, radiation therapy was planned to the chest wall or whole breast by using the high conventional tangential field using 2D radiation portals. Central lung distance (CLD) and the distance of superior border was measured from the head of the humerus and were recorded. CECT chest was done in the same position alike during conventional simulation. All the images were shifted to the treatment planning system. The Contouring of Axillary lymph nodes level I and II was done on Oncentra contouring software.

Results: The coverage of the axillary nodes was not related to central lung distance (CLD). However, some with CLD of 1cm had more coverage of the level I nodes than with CLD of 2 cm and the maximum CLD in the field was 2.5 cm. Of the 18 patients in the study, 13 patients had <2 cm distance from the humeral head and all the axillary level II LN covered in the field. Whereas 5 patients having distance >2 cm did not have adequate coverage of level II axillary LN's.

Conclusions: The distance of the cranial border of the tangent portal from the head of the humerus shows a relationship with coverage of level II nodes cranially. As the distance decreases the coverage of level II nodes cranially keeps increasing. In majority of the patients a distance of 2 cm or less than 2 cm ensured good coverage of level II nodes cranially. Similarly, no correlation was found between volumetric coverage of the axillary nodes with central lung distance.

Keywords: Axillary dissection, Central lung distance, High conventional tangential field

INTRODUCTION

The age-adjusted incidence rates of breast cancer in India is lower than the western countries, with an annual incidence of approximately 1,44,000 new cases of breast

cancers in India and the most common female cancer in urban India. Breast cancer in India varies from as low as 5 per 100,000 female populations per year in rural areas to 30 per 100,000 female populations per year in urban areas.¹ At this institute a total of 190 patients of carcinoma breast were registered for a period of 2 years, accounting it as the second most common malignancy in female patients, which accounts for 18.0% of all female malignancies. At presentation, ~50% of patients were >50 years of age. PMRT has been proven to reduce the 15-year isolated loco-regional recurrence rate for patients with lymph node-positive disease from 29% to 8%. A more revolutionary finding was that this significant absolute improvement in loco-regional control reduced the 15-year breast cancer mortality rate.²

Radiotherapy treatment fields are usually tangential to encompass the breast or thoracic wall and also cover the axilla. Currently, in patients with micro-metastatic involvement of the Sentinel Lymph node (SLN), systematic Axillary lymph node dissection (ALND) is not recommended when patients receive systemic therapy (ST) and whole breast irradiation. This principle would be true only if the dose delivered and volumes covered by the TF irradiation are sufficient to kill residual axillary cells.³

In a set up where the majority of patients present in stages III and IV, MRM is usually offered as surgical modality combining total mastectomy with removal of axillary nodes. Up to 30% loco-regional failure (LRF) has been demonstrated by various studies when surgery is employed as a sole treatment modality. The commonest site of loco-regional failure following mastectomy and axillary nodal dissection is the chest wall followed by the supraclavicular fossa and infra-clavicular region.^{4,5}

Axillary radiation and surgery have provided equivalent local control in early breast cancer patients. Irradiation of the axilla can be performed via separate anterior-posterior fields; alternatively a portion of the axilla (the most likely levels I and II) can be covered by the tangential fields; Irradiating the lower levels of the axilla through tangential fields is considered to be more practical.⁶

With the recent publication of (ACOSOG) Z0011, the optimal design of radiation fields for patients with positive SLNs who do not undergo ALND is uncertain. This will be increasingly important given that many patients with positive SLNs will forego ALND. In weighing whether such patients should receive regional nodal irradiation (RNI), it is important to consider the reason for the less than 1% regional recurrence rate in Z0011, despite the fact that an estimated 27% of patients had additional un-dissected positive nodes.⁷

It is believed that TF radiation that was used to treat the breast coincidentally delivered radiation treatment to the lower axilla and eradicated the disease. If a large component of the axilla were in the TF region, this is likely to have contributed significantly.⁸ In the era of CT-

based three dimensional (3D) radiotherapy planning however, concerns have been raised about the adequacy of coverage of the axillary levels in the tangential fields.⁹

The primary aim of this study was to evaluate the coverage of the axillary nodal levels I and II using high conventional tangential fields in patients with or without axillary dissection.

METHODS

The prospective study was conducted for a period of 1 year (July 2015 to June 2016), 18 patients were enrolled and were planned for radiation therapy to the chest wall or whole breast by using the high conventional tangential field.

Inclusion criteria

Age of 20-70 years, stage= II, III, IV, KPS>70, BCS with sentinel lymph node dissection and post mastectomy with normal biochemical and biochemistry profile.

Exclusion criteria

Age of <20 and >70 years, KPS<70 and deranged hematological and biochemistry profile.

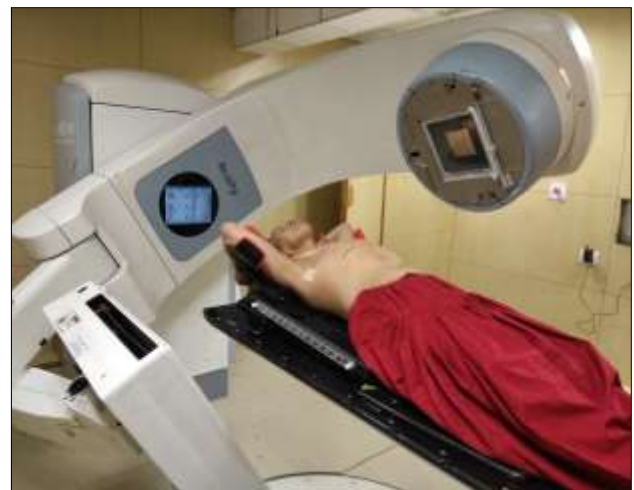

Figure 1: Planning on simulator with standard borders marked by fiducials.

2D radiation portals were designed on conventional simulator as shown in (Figure 1). On the medial and lateral high conventional tangential field, the borders were marked by using radio-opaque fiducials as on the head of clavicle or 1st intercostal space which were identified as the superior border, and the 2 cm below the infra-mammary fold were labelled as the inferior border. The lateral border was mid-axillary line, and medial border, if no internal mammary portal is used, should be at or 1 cm over the midline.

The simulation films were taken by the standard technique and central lung distance (CLD) was calculated

as shown in (Figure 2) by using the standard scale software on the treatment planning station (TPS).

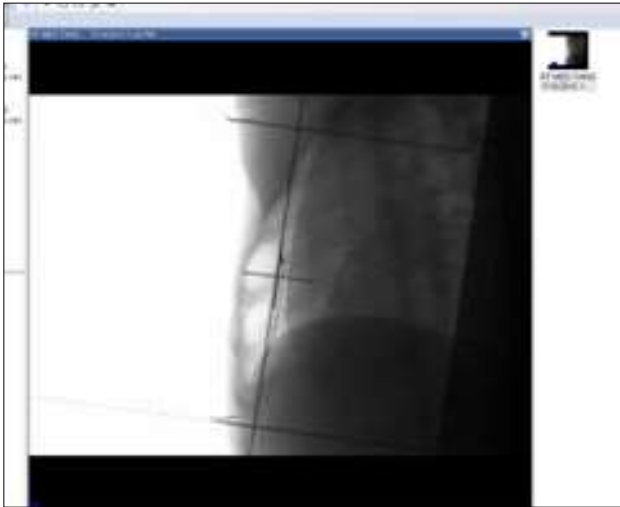

Figure 2: Central lung distance.

The distance of the superior border was measured from the head of the humerus shown in (Figure 3). CECT chest was done in the same position along with same immobilization accessories used during conventional simulation; 2mm thick slices was taken from thyroid notch to upper abdomen which included the liver as the field borders of portal marked by radio-opaque fiducial.

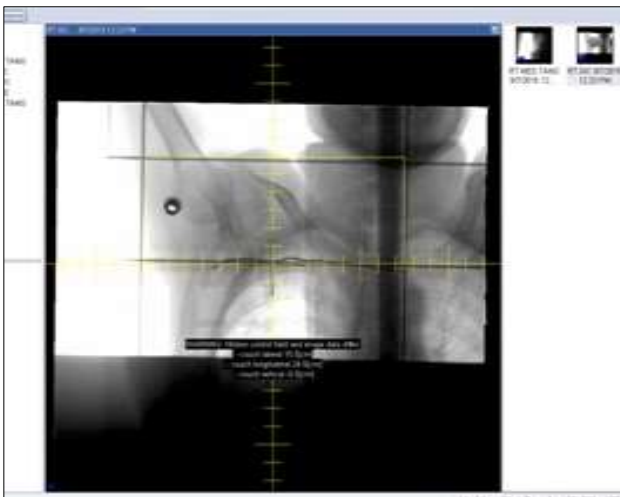


Figure 3: Distance of superior tangent field border from humeral head.

The CECT revealed that the marked field is adequate to cover the axillary lymph nodes level I and II. The coverage were recorded positive if it lies within the field and negative if lymph nodes are outside the field. All the images were copied on DVD and shifted to treatment planning system Oncentra.

The Contouring of Axillary lymph nodes level I and II were done on Oncentra contouring software. The axillary

level I were shown in blue colour wash as shown in (Figure 4) and level II were marked by red colour wash as shown in (Figure 5). The serial of lines were drawn to assess the coverage of lymph nodes level I and II and measured as full, adequate, inadequate or nil. The superior border also identified whether covering level II adequately or not and information was recorded in a tabulated form.

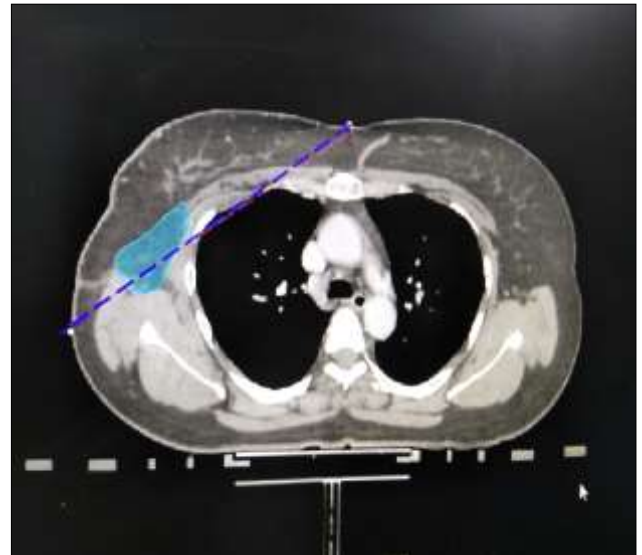

Figure 4: Axillary lymph node Level-I and position of the beam.

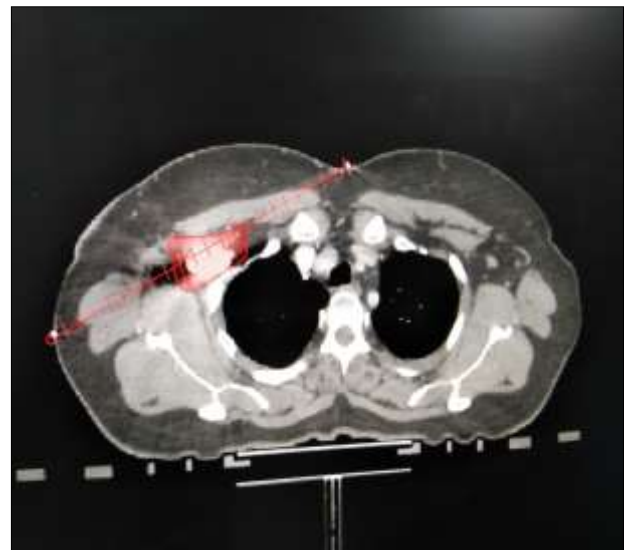

Figure 5: Axillary lymph node level-II and the position of the beam.

Statistical analysis

Data was collected and entered in Microsoft excel spread sheet, cleaned and analysed using Epi-info software. Descriptive statistics was used to summarise demographic data. Proportions and percentages were used to categorical variables.

RESULTS

Total number of patients included in the study were eighteen out of which, more than 50% of patients were above 50 years and more than 94.4% patients had a mastectomy and 5.6% had undergone breast-conserving surgery (BCS) with sentinel lymph node dissection (SLND). All patients underwent CECT in the same conventional planning setup like same breast board and same position.

The characteristics of all patients were recorded such age, stage, laterality etc. 50% of patients were less than 50 years and rest were more than 50 years and maximum age was 68 years and the minimum age was 26 years. Out of a total 18 patients, 9(50%) were below the age of 50 years and 9(50%) were more than 50 years. 55.5% of patients enrolled in the study presented with stage II disease and 38.9% patients were of stage III and 5.6% was in stage IV.

Table 1: Central lung distance and volume % of level I and II axillary nodes covered in tangential portals of total patients in study.

| Patients | Axillary Level-I % of volume of node covered in the field | Axillary Level-II % of volume of node covered in the field | CLD in cm |
|----------|---|--|-----------|
| 1 | 0 | 0 | 1.5 |
| 2 | 0 | 0 | 1.0 |
| 3 | 10 | 0 | 2.0 |
| 4 | 17 | 0 | 2.0 |
| 5 | 0 | 0 | 1.0 |
| 6 | 0 | 0 | 2.0 |
| 7 | 10 | 0 | 1.0 |
| 8 | 20 | 0 | 1.5 |
| 9 | 50 | 0 | 2.0 |
| 10 | 70 | 50 | 1.0 |
| 11 | 50 | 0 | 1.0 |
| 12 | 25 | 0 | 2.0 |
| 13 | 20 | 0 | 1.5 |
| 14 | 0 | 0 | 2.0 |
| 15 | 0 | 0 | 2.0 |
| 16 | 10 | 0 | 1.0 |
| 17 | 0 | 0 | 2.5 |
| 18 | 15 | 0 | 2.0 |

Out of 18 patients, 13(72.2%) had right-sided disease and 5(27.8%) had left-sided disease. There were more cases of right-sided disease. All the patients were planned on 2D simulator "Acuity" and then planning CECT was obtained in the same position, with same breast board. The data of individual patient recorded in the DVD was analyzed on Oncentra contouring software slice by slice. As shown in (Table 1), the maximum coverage of level I was 70% and the minimum was 0%. However, none of

the patients had adequate coverage of the level I nodes. In all the patients except one, the level II axillary nodes coverage was nil in tangential portals. Only one patient had 50% coverage of level II nodes.

However, the coverage of the axillary nodes was not related to central lung distance (CLD). Some with CLD of 1cm had more coverage of the level I nodes than with CLD of 2 cm and the maximum CLD in the field was 2.5 cm.

As shown in (Figure 6) and (Table 2), the distance of the cranial border of the tangent portal from the head of the humerus shows a relationship with coverage of level II nodes cranially. As the distance decreases the coverage of level II nodes cranially keeps increasing. In most of the patients, a distance of 2 cm or less than 2 cm ensure good coverage of level II nodes cranially.

Table 2: Relationship between cranial coverage of Level-I and level-II nodes with cranial border of tangential portal distance from head of the humerus.

| Axillary I coverage | Axillary II coverage | Superior border distance from the head of humerus in cm |
|---------------------|----------------------|---|
| Covered | Covered | 2.0 |
| Covered | Covered | 1.0 |
| Covered | Covered | 1.5 |
| Covered | Not covered | 2.5 |
| Covered | Covered | 0.5 |
| Covered | Covered | 2.0 |
| Covered | Covered | 0.5 |
| Covered | Covered | 2.0 |
| Not covered | Not covered | 4.0 |
| Covered | Covered | 0.5 |
| Covered | Covered | 1.5 |
| Covered | Covered | 1.5 |
| Covered | Not covered | 2.5 |
| Covered | Covered | 2.0 |
| Covered | Not covered | 2.5 |
| Covered | Covered | 2.0 |
| Not covered | Not covered | 2.5 |
| Covered | Covered | 2.0 |

Table 3: Coverage of the axillary level-II lymph nodes.

| Distance measured | Covered | Not Covered | % of |
|--------------------|---------|-------------|------|
| ≤2 cm | 13 | 00 | 100 |
| >2 cm | 0 | 05 | 0 |
| Percentage covered | 72% | 28% | 100 |

Table 3 shows, total patients were 18 in study, 13 patients had ≤2 cm distance from the humeral head and all had the axillary level II lymph nodes covered in the field, whereas 5 patients having distance >2cm did not had adequate coverage of level-II axillary LNs.

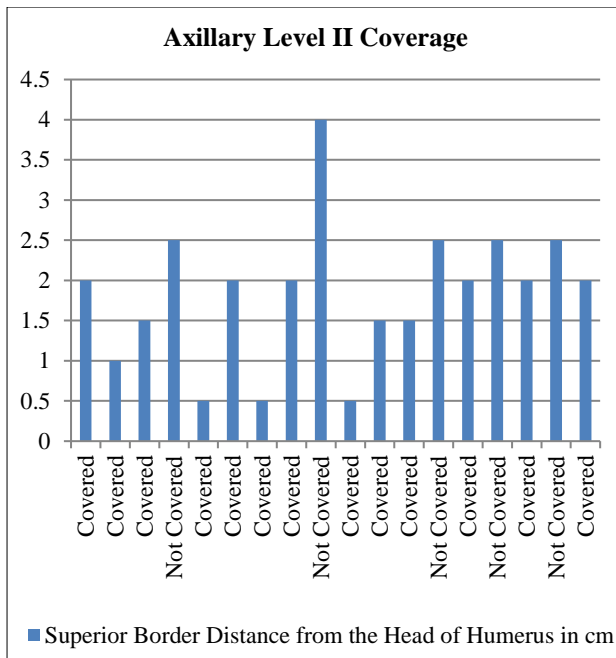


Figure 6: Relationship between cranial coverage of level-II and Level I nodes with cranial border of tangential portal distance from head of humerus.

DISCUSSION

Radiotherapy has an important role in the treatment of breast cancer at every stage. In early-stage disease, radiotherapy is an integral part of breast-conserving therapy. For patients with more advanced cancers, adjuvant radiotherapy substantially decreases the risk of local recurrence and also improves the survival among patients with positive axillary lymph nodes. In locally advanced disease (often the most common presentation in the limited-resource setting), after neoadjuvant systemic therapy, patients require both radiotherapy and modified radical mastectomy in an effort to achieve local control.¹⁰

Local recurrence after breast conservation was seen in 3% to 17% of patients and occurred in 2% to 10% of patients following mastectomy. The surgery has been a mainstay of standard axillary management for patients with invasive breast carcinoma from last so many years. In the pre-sentinel node era, axillary lymph node dissection (ALND) was considered a critical component of surgery because it provided both treatment and information on nodal stage. The Sentinel lymph node biopsy (SLNB) allowed the reliable identification of patients with axillary lymph node metastasis and axillary lymph node dissection (ALND) was limited to patients with axillary lymph node metastasis who might benefit from this procedure. For patients with sentinel lymph node metastasis, axillary lymph node biopsy has remained a standard practice. Recently, some investigators have questioned the need for routine axillary lymph node dissection (ALND) in patients with limited sentinel lymph node (LN) metastasis, and they have suggested that axillary lymph node dissection

(ALND) might be considered overtreatment especially after the result of American College of Surgeons Oncology Group (ACOSOG) Z0011 trial.¹¹

Although the Z0011 protocol required that patients receive whole-breast radiotherapy (RT) using standard tangential fields and specified that the third field of directed nodal treatment should not be used, the extent of RT coverage of the regional nodes in these patients has not previously been described. It has been hypothesized that radiation oncologists, who could not be blinded to patients' treatment assignments and who had discretion over the extent of the axillary contents included in tangential fields, might have systematically treated patients on the SLND-only arm with high tangents to include a component of axillary level I/II more often than those in the ALND (axillary lymph node dissection) arm.

The present study was conducted to evaluate whether the level I and level II axillary nodes are adequately covered in high tangent portals or not. Total of 18 patients were included and evaluated in this study, most of whom were presented after mastectomy, 50% of the patients were below 50 years of age. Most of the patients were stage II and III. Majority were having right-sided disease. First, we correlated the coverage of the level II nodes cranially with the upper border of the tangent portal. It was observed that there was a clear and strong correlation with cranial coverage and upper border of the portal. Higher the upper border more was the coverage of level II node cranially. Author found that if the upper border of the tangent portal is within 2 cm from the caudal border of the head of the humerus then in 100% of the patients the coverage was adequate. However, in patients where the upper border was more than 2 cm from the caudal edge of the humerus, the coverage of level II nodes was inadequate in all the patients. So, from this study author can recommend that the cutoff of 2 cm from the humeral head is important in covering the level II nodes cranially.

However, author found that none of the patients had adequate coverage of the axillary lymph nodes volumetrically as in all the patients, the post border of the tangent portal was not covering the nodes posteriorly as reflected by contouring the nodes and projecting the posterior border of the field on contoured nodes. Author tried to establish any correlation of the volumetric coverage of the nodes with central lung distance (CLD), but again author did not find any relationship between the two. Shin-Hyung Park, in a similar kind of study, showed gross inadequate coverage of the axillary nodes volumetrically.¹²

From this data, it is clear that with tangent portals, it is not possible to irradiate the axilla adequately. However, author can conclude that cranial coverage of level II nodes is possible if the distance of the upper border of the tangent portal from the caudal edge of the humerus is two or less than two centimeters. However, author must remember the adequate coverage of the level II node

cranially does not warrant to adequate coverage of the axillary nodes volumetrically.

Funding: No funding sources

Conflict of interest: None declared

Ethical approval: The study was approved by the Institutional Ethics Committee

REFERENCES

1. Srivastava VK, Tanvir K, Sarin R. Consensus document for management of breast cancer. ICMR. 2016;(1):12-3.
2. Barsoum M, Mostafa M, El Hossieny H, Nasr A, Mahmoud M, Fouda S. Dosimetric prospective study comparing 2D and 3D planning for irradiation of supraclavicular and infraclavicular regions in breast cancer patients. J Egypt Nat Cancer Institute. 2015;27(1):25-34.
3. Stefanovski Z, Smichkoska S, Petrova D, Lazarova E. Advantages of the technique with segmented field for tangential breast irradiation. In Proceed 3rd Conference Med Physics Biomed Engineer. 2013;18:18-9.
4. Recht A, Gray R, Davidson NE, Fowble BL, Solin LJ, Cummings FJ, et al. Locoregional failure 10 years after mastectomy and adjuvant chemotherapy with or without tamoxifen without irradiation: experience of the Eastern Cooperative Oncology Group. J Clin Oncol. 1999;17(6):1689.
5. Belkacemi Y, Allab-Pan Q, Bigorie V, Khodari W, Beaussart P, Totobenazara JL, et al. The standard tangential fields used for breast irradiation do not allow optimal coverage and dose distribution in axillary levels I–II and the sentinel node area. Annals Oncol. 2013;24(8):2023-8.
6. Setton J, Cody H, Tan L, Morrow M, Hudis C, Catalano J, et al. Radiation field design and regional control in sentinel lymph node-positive breast cancer patients with omission of axillary dissection. Cancer. 2012;118(8):1994-2003.
7. Haffty BG, Hunt KK, Harris JR, Buchholz TA. Positive sentinel nodes without axillary dissection: implications for the radiation oncologist. J Clin Oncol. 2011;29(34):4479-81.
8. Alço G, Iğdem SI, Ercan T, Dincer M, Şentürk R, Atilla S, et al. Coverage of axillary lymph nodes with high tangential fields in breast radiotherapy. Brit J Radiol. 2010;83(996):1072-6.
9. Caudle AS, Hunt KK, Tucker SL, Hoffman K, Gainer SM, Lucci A, et al. American College of Surgeons Oncology Group (ACOSOG) Z0011: impact on surgeon practice patterns. Annals Surg Oncol. 2012;19(10):3144-51.
10. Bese NS, Kiel K, El-Gueddari BE, Campbell OB, Awuah B, Vikram B. International Atomic Energy Agency. Radiotherapy for breast cancer in countries with limited resources: program implementation and evidence-based recommendations. Breast J. 2006;12:96-102.
11. Giuliano AE, McCall L, Beitsch P, Whitworth PW, Blumencranz P, Leitch AM, et al. Locoregional recurrence after sentinel lymph node dissection with or without axillary dissection in patients with sentinel lymph node metastases: the American College of Surgeons Oncology Group Z0011 randomized trial. Annals Surg. 2010;252(3):426.
12. Crile JG, Cooperman A, Esselstyn JC, Hermann RE. Results of partial mastectomy in 173 patients followed for from five to ten years. Surg, Gynecol Obstetr. 1980;150(4):563-6.

Cite this article as: Chandrakant L, Thakur S, Gupta M, Seam RK, Gupta M, Sharma S. Computerized tomography based evaluation of level I and II axillary lymph nodes by high conventional tangential fields in carcinoma breast. Int J Res Med Sci 2020;8:474-9.