

## Case Report

# Diaphragmatic fenestration an effective treatment for refractory postoperative chylothorax: a case report

Oluwaseun R. Akanbi<sup>1</sup>, Swaminathan Vaidyanathan<sup>2\*</sup>, Prakash Agarwal<sup>3</sup>, Janeel Musthafa<sup>2</sup>,  
Neville A. G. Solomon<sup>2</sup>

<sup>1</sup>Department of Thoracic and Cardiovascular Surgery, University of Ilorin Teaching Hospital, Ilorin, Kwara State, Nigeria

<sup>2</sup>Department of Paediatric Cardiac Surgery, Apollo Children's Hospital, Chennai, Tamil Nadu, India

<sup>3</sup>Senior Consultant, Paediatric Surgery, Apollo Children's Hospital, Chennai, Tamil Nadu, India

**Received:** 04 December 2019

**Revised:** 27 December 2019

**Accepted:** 31 December 2019

### \*Correspondence:

Dr. Swaminathan Vaidyanathan,

E-mail: [swaminathan\\_27@yahoo.co.in](mailto:swaminathan_27@yahoo.co.in)

**Copyright:** © the author(s), publisher and licensee Medip Academy. This is an open-access article distributed under the terms of the Creative Commons Attribution Non-Commercial License, which permits unrestricted non-commercial use, distribution, and reproduction in any medium, provided the original work is properly cited.

## ABSTRACT

Postoperative chylothorax remains a clinical challenge to the surgeon with substantial morbidity and risk of mortality. Though an uncommon complication, it is known to complicate cardiac and non-cardiac thoracic surgeries. Conservative measures are first employed in managing this. Surgical options are adopted when the effusion is protracted, most recent of which includes diaphragmatic fenestration. A 9-year-old girl is presented who developed recurrent right chylothorax following thoracoscopic excision of a cystic lymphangioma. Following failed conservative therapy, she had thoracic duct ligation and right diaphragmatic fenestration (using fenestrated polytetrafluoroethylene patch) with satisfactory outcome. Aetio-pathologic mechanisms implicated in postoperative chylothorax have been classified into traumatic (iatrogenic injury to the thoracic duct or its branches) and non-traumatic. With initial conservative measures (repeated pleural aspirations and intercostal drainage, medium chain triglyceride/ low fat feeds or alternatively, fasting and total parenteral nutrition) spontaneous closure remains unpredictable. Diaphragmatic fenestration when employed resulted in faster resolution of effusion and earlier commencement of enteral feeding with no significant complication. Diaphragmatic fenestration is effective and safe for treating refractory post-operative chylothorax.

**Keywords:** Chylothorax, Diaphragmatic fenestration, Effusion, Thoracic duct

## INTRODUCTION

Postoperative chylothorax remains a clinical challenge to the surgeon with substantial morbidity and risk of mortality.<sup>1-4</sup> This significant morbidity results from loss of fluid, proteins and immunoglobulins leading to respiratory compromise, malnutrition and immunosuppression with increasing susceptibility to sepsis with prolonged hospital stay.<sup>1,4,5</sup> Its incidence following cardiac surgery varies widely, mostly reported

as 0.5% to 5% with some studies reporting much higher values.<sup>1-3,5</sup>

This wide variation in incidence is attributed to heterogeneity in the study population.<sup>3</sup> Although chylothorax is noted to complicate surgery for congenital heart disease most commonly (e.g. Fontan completion, Glenn shunt, repair of transposition of great arteries, heart transplantation) it could also complicate non-cardiac thoracic surgeries (oesophageal, lung or mediastinal).<sup>4,6,7</sup>

Algorithms for the management of postoperative chylothorax currently offer a conservative approach to the care of patients in the early days following diagnosis. Methods employed include fasting, use of medium chain triglyceride/ low fat feeds, total parenteral nutrition, and octreotide therapy.<sup>2,3,7,8</sup>

Less invasive surgical options include periodic pleural aspirations and intercostal drainage which are employed to facilitate pleural drainage. Thoracic duct embolization by interventional radiology, in the recent years, is of added benefit. With these approaches, there is resolution of most cases of chylothorax.

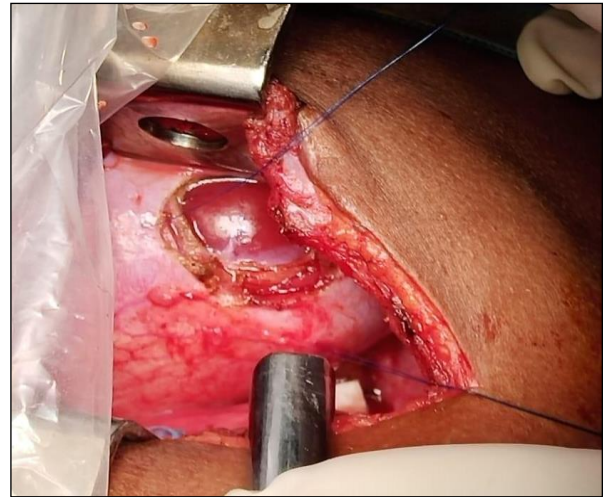
In cases of protracted pleural drainage, surgical intervention has proven to yield better outcomes when instituted early. Thoracic duct ligation, pleurodesis, pleurectomy and the use of pleuroperitoneal shunts have been employed with varying results. Most recently the use of diaphragmatic fenestration has been employed with promising results. Authors present a case report depicting this following a thoracic surgery.

## CASE REPORT

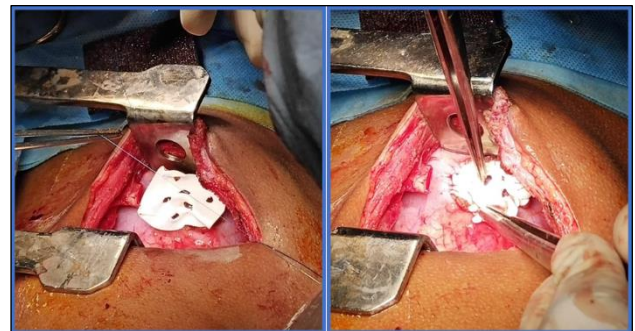
A 9-year-old girl was brought in with breathing difficulty associated with pain on inspiration on the right side of her chest. No fever or cough. She had undergone thoracoscopic excision of a bilobed mediastinal cystic lymphangioma three weeks prior which was complicated by chylous leak on the right side. This was managed conservatively with total parenteral nutrition, medium chain triglyceride diet and octreotide following which she was discharged home. She had been on tadalafil and ambrican for primary pulmonary hypertension 5 years prior to surgery. Significant chest finding at re-admission was reduced air entry on the right hemithorax.

Following repeat right intercostal drainage for recurrent right chylothorax, conservative measures (fasting with total parenteral nutrition) were reinstated with no improvement in the volume of drain effluent after a week. Daily chest drain effluent was in excess of 20 ml/kg/day. An attempt at embolization of the rent in the thoracic duct on the 9<sup>th</sup> day following intercostal drainage was not successful with eventual development of chylothorax on the left requiring left intercostal drainage. Based on the persistent drainage, a decision for surgical intervention was taken.

On the 12<sup>th</sup> day, she initially had right video assisted thoracoscopic surgery later converted to a right thoracotomy. Chyle leak was noted near the aortic hiatus. The thoracic duct was ligated en masse using polypropylene sutures and reinforced with Teflon pledgets BioGlue was applied to seal off any further leak. A 2cm x 3cm opening in the right hemidiaphragm was created (Figure 1). This was closed using a multiply fenestrated 0.6 mm Polytetrafluoroethylene (PTFE) patch (Figure 2A and 2B).



**Figure 1: Diaphragmatic opening (2 cm x 3 cm) created in right hemidiaphragm as seen at thoracotomy.**



**Figure 2: (A) Multi-fenestrated 0.6mm polytetrafluoroethylene (PTFE) patch cut to size and being sutured to the opening in right hemidiaphragm; (B) PTFE patch in place after suturing with fenestration in patch being highlighted.**

Progressive, significant, decline in chest drain effluent was noted in the days following surgery with commencement of enteral feeding by the 7<sup>th</sup> post-operative day. Following removal of the left chest drain (post-operative day 11), she was discharged home with the right chest drain in place. This was removed during her subsequent clinic visit. At last follow up (3 months after discharge), clinical and radiologic assessment showed no recurrence of the chylothorax, no evidence of ascites, no abnormality of respiratory function and good exercise tolerance.

## DISCUSSION

Even though an uncommon complication following paediatric cardiothoracic surgery, postoperative chylothorax is known for its significant morbidity and mortality in these cohort of patients if untreated. It poses a challenge to the managing surgeon particularly in cases when it becomes protracted. Loss of lymphatic fluid rich in proteins, fats, and immunoglobulins results in

dehydration, malnutrition, immunosuppression with increased preponderance to infections.<sup>1,4,5</sup> These, in addition to the prolonged hospital stay, result in increased cost of care.

Aetio-pathologic mechanisms implicated in the formation of postoperative chylothorax have been classified into traumatic and non-traumatic (Pulmonary Lymphatic Perfusion Syndrome - PLPS and Central Lymphatic Flow Disorder - CLFD). Traumatic leaks could result from iatrogenic injury to the central thoracic duct, an accessory lymphatic vessel or its major branch.<sup>1</sup> Salva et al, discovered in their study that in most cases of traumatic leaks, the central thoracic duct was intact. PLPS was observed commonly in patients with univentricular physiology causing diffuse lymphatic ooze from the pleural surface even in the absence of thoracic duct injury. CLFD has been defined as abnormal central lymphatic flow due to congenital absence of the thoracic duct, anatomic thoracic duct outlet obstruction, effusions in more than one compartment (chylothorax, chylous ascites), and the presence of dermal backflow through lymphatic collaterals in the abdominal wall.

First line therapy involves conservative measures which include the use of repeated pleural aspirations and intercostal drainage employed to facilitate pleural drainage. Medium chain triglyceride/ low fat feeds or alternatively, fasting and total parenteral nutrition is commenced. Spontaneous closure with conservative treatment remains unpredictable.<sup>6,9</sup> When fasting and total parenteral nutrition was combined with octreotide therapy, resolution of the pleural effusion approached 50% as reported by Talwar et al, and 85% as reported by Christofe et al.<sup>3,8</sup> Chan et al, in their series noted no overall decrease in pleural fluid.<sup>2</sup> Patient had been managed successfully using conservative means during the first occurrence. Following recurrence, despite the use of octreotide, there was persistence of the pleural drainage. Thoracic duct embolization has reportedly yielded success in patients with traumatic leaks. There however could be prolonged/ high volume pleural drainage despite these conservative measures resulting in the need for surgical intervention.

Thoracic duct ligation with non-absorbable suture is thought to address the point of traumatic leak. This can be achieved by thoracotomy, thoracoscopy or laparotomy.<sup>3,4</sup> This does not address the ooze of lymphatic fluid from the lung parenchyma.<sup>7</sup> Some authors have employed the use of pleurodesis and pleurectomy to obliterate the pleural space to mitigate this. The attendant pain and limitation in pulmonary function makes this option not optimal.<sup>5</sup>

Durairaj et al, described successful diaphragmatic fenestration for persistent chylothorax using a polypropylene mesh in a 12-year-old patient after the Fontan operation.<sup>10</sup> Further case series by Talwar and colleagues and Kumar et al also documented successful

treatment of chylothorax following cardiac surgery using polytetrafluoroethylene (Gore-Tex) patch.<sup>5,9</sup> Diaphragmatic fenestration has the advantage of reducing external loss of pleural fluid proteins and nutrient as this is absorbed in the peritoneal cavity.<sup>10</sup> Its efficacy in reducing the volume of daily pleural effluent as well as the number of days required for chest drainage has been demonstrated.<sup>5,7</sup> As in patient, there was quick return to enteral feeding after diaphragmatic fenestration. The fenestrations in the patch allow adequate drainage of pleural fluid into the peritoneal cavity reducing the chance of infection and occlusion a problem noted to occur with the use of pleuroperitoneal shunts, while preventing herniation of intraabdominal content.<sup>3,9,10</sup>

Savla et al, showed that diaphragmatic fenestrations worked better with cases of traumatic chylous effusions and PLPS as compared with those with CLFD.<sup>1</sup> In the latter the collateral dermal lymphatic flow as well as chylous ascites makes diaphragmatic fenestration a less favored option. Patient had no evidence of ascites on screening making the option of fenestration appropriate. Although she had bilateral chylothorax, she had right diaphragmatic fenestration only with subsequent resolution on both sides. Bilateral diaphragmatic fenestration has been described in some reports however right sided diaphragmatic fenestration alone has been found to effectively treat chylothorax on the left side too.<sup>5,7</sup>

Potential complications of diaphragmatic fenestration are respiratory compromise from impaired diaphragmatic function and an increase in abdominal girth signifying chylous ascites. No report of such was noted in the literature nor in the presented case. To conclude however, that diaphragmatic fenestration has no associated adverse clinical manifestation may be premature as the number of cases reported so far are limited. Prospective multi-centre studies and long term follow up may help elucidate this.

## CONCLUSION

Postoperative chylothorax causes significant morbidity and mortality risk when it complicates cardiothoracic surgery. Diaphragmatic fenestration as a mode of intervention has been found to be safe and efficacious in resolving prolonged chylothorax unresponsive to conservative measure. There exists the need for further study to highlight the limitations of this procedure.

*Funding: No funding sources*

*Conflict of interest: None declared*

*Ethical approval: Not required*

## REFERENCES

1. Savla JJ, Itkin M, Rossano JW, Dori Y. Post-operative chylothorax in patients with congenital heart disease. *J Am Coll Cardiol.* 2017 May 8;69(19):2410-22.

2. Chan EH, Russell JL, Williams WG, Van Arsdell GS, Coles JG, McCrindle BW. Postoperative chylothorax after cardiothoracic surgery in children. *Ann Thor Surg.* 2005 Nov 1;80(5):1864-70.
3. Talwar S, Agarwala S, Mittal CM, Choudhary SK, Airan B. Pleural effusions in children undergoing cardiac surgery. *Ann Pediatr Cardiol.* 2010 Jan;3(1):58.
4. Fahimi H, Casselman FP, Mariani MA, van Boven WJ, Knaepen PJ, van Swieten HA. Current management of postoperative chylothorax. *Ann Thor Surg.* 2001 Feb 1;71(2):448-50.
5. Kumar TS, Balduf K, Boston U, Knott-Craig C. Diaphragmatic fenestration for refractory chylothorax after congenital cardiac surgery in infants. *J Thor Cardio Surg.* 2017 Dec 1;154(6):2062-8.
6. Robinson CL. The management of chylothorax. *Ann Thor Surg.* 1985 Jan 1;39(1):90-5.
7. Talwar S, Das A, Choudhary SK, Airan B. Diaphragmatic fenestration for resistant pleural effusions after univentricular palliation. *World J Pediatr Cong Heart Surg.* 2016 Mar;7(2):146-51.
8. Christofe NM, Pessotti CF, Paiva L, Jatene IB. Incidence and Treatment of Chylothorax in Children Undergoing Corrective Surgery for Congenital Heart Diseases. *Braz J Cardio Surg.* 2017 Oct;32(5):390-3.
9. Talwar S, Choudhary SK, Mukkannavar SB, Airan B. Diaphragmatic fenestration for resistant pleural effusions after the Fontan operation. *J Thor Cardio Surg.* 2012 Jan 1;143(1):244-5.
10. Durairaj M, Sharma R, Choudhary SK, Bhan A, Venugopal P. Diaphragmatic fenestration for resistant pleural effusions after univentricular repair. *Ann Thor Surg.* 2002 Sep 1;74(3):931-2.

**Cite this article as:** Akanbi OR, Vaidyanathan S, Agarwal P, Musthafa J, Solomon NAG. Diaphragmatic fenestration an effective treatment for refractory postoperative chylothorax: a case report. *Int J Res Med Sci* 2020;8:767-70.