

## Original Research Article

# Retroperitoneal laparoscopic adrenalectomy: its role in the management of adrenal tumour and tertiary care centre experience

Avinash Pratap Singh Thakur<sup>1\*</sup>, G. Venugopal<sup>2</sup>, Darsan S.<sup>2</sup>

<sup>1</sup>Department of Urology, Super Speciality Hospital, Netaji Subhash Chandra Bose Medical College, Jabalpur, Madhya Pradesh, India

<sup>2</sup>Department of Urology, Super Speciality Block, Government Medical College, Thiruvananthapuram, Kerala, India

**Received:** 19 December 2019

**Revised:** 02 January 2020

**Accepted:** 28 January 2020

### \*Correspondence:

Dr. Avinash Pratap Singh Thakur,  
E-mail: drapst@gmail.com

**Copyright:** © the author(s), publisher and licensee Medip Academy. This is an open-access article distributed under the terms of the Creative Commons Attribution Non-Commercial License, which permits unrestricted non-commercial use, distribution, and reproduction in any medium, provided the original work is properly cited.

## ABSTRACT

**Background:** Laparoscopic adrenalectomy for adrenal tumour has gained increased popularity worldwide. To decrease the complications of commonly used transperitoneal approach, by not entering into peritoneal cavity the retroperitoneal laparoscopic adrenalectomy (RLA) has developed. It has several advantages over the transperitoneal approach and associated with reduced morbidity and excellent outcome. The objective of this study was to report our experience with RLA for treatment of adrenal tumour.

**Methods:** The study was done from August 2014 and December 2017, data of 44 patients who underwent RLA for adrenal tumour in the institute were retrospectively reviewed. Patient's demographical, clinical, diagnostic and procedural data were recorded. All patients were assessed by history, physical examinations, laboratory values with biochemical marker test and imaging by computed tomography/magnetic resonance imaging. Treatment outcome was assessed in terms of operative time, haemoglobin drop, conversion rate, hospital stay and complications.

**Results:** In 44 adrenalectomy, 24 men and 20 women, with a mean age of  $47.0 \pm 8.9$  years were enrolled. Mean body mass index was  $23.5 \pm 2.2$  kg/m<sup>2</sup>. Right adrenal tumour was seen in 26 cases and left in 18 cases. Mean adrenal mass size was  $2.6 \pm 0.85$  cm. Mean operative time was  $109.1 \pm 21.16$  minutes, mean haemoglobin drop was  $0.47 \pm 0.26$  gram/L. Conversion to open surgery was necessary in 2 patients. Mean postoperative hospital stay was  $4.0 \pm 0.91$  days. Recovery time mean value was  $12.18 \pm 1.7$  days postoperatively. In final histopathology result adenoma was most prevalent (25 cases) and myelolipoma was least (1 case).

**Conclusions:** RLA appears to be safe and effective alternative to transperitoneal adrenalectomy for moderate size adrenal tumour in particular less than 6 cm. It is associated with less blood loss, shorter hospitalization, low conversion rate, fewer complications and early recovery. RLA offers an alternative method for treating adrenal tumour with improved surgical outcomes.

**Keywords:** Adrenalectomy, Laparoscopic adrenalectomy, Retroperitoneal laparoscopic adrenalectomy

## INTRODUCTION

The adrenal glands are located suprarenally in the retro peritoneum within the gerota fascia; they are known to be central to homeostasis in the body. They produce several

hormones such as aldosterone, cortisol and adrenaline. Frequency of adrenal tumour is very less, more commonly they found during routine examinations for some other pathology. The adrenal tumour may be benign or malignant. Adrenalectomy is usually recommended if the

adrenal mass size is more than 4 cm, if it enlarges by 1 cm or more during the follow up, or if there is evidence of autonomous hormonal secretion.

There is longstanding history of adrenal surgery. In 1889, Thornton described first open adrenalectomy (OA), which was the only surgical approach to adrenal diseases for decades. After that, several approaches to adrenal glands have been developed. Nowadays there are different surgical approaches available to manage the adrenal masses such as laparoscopic adrenalectomy (LA), robotic-assisted procedure and more recently single-incision technique. All of these having strengths and weaknesses; the selection of any approach depends on different parameters of the tumour and patients characteristics (such as tumour size, malignancy, patient's conditions and surgeons experience).

Gagner et al. in 1992 first described the laparoscopic treatment of adrenal masses; it was performed by laparoscopic trans peritoneal route.<sup>1</sup> The initial indications for adrenalectomy by laparoscopic approach included various pathological conditions, e.g. Cushing's disease, aldosterone-producing adenoma, non-functioning adenoma and other rare pathologies (myelolipoma and adrenal cyst). Later on with rapid experience in the laparoscopic surgery many early contraindications (e.g. pheochromocytoma, obesity, previous abdominal surgery, large adrenal lesions and malignancy) proved not to be absolute; management of these conditions rather related to the surgical skills of the team.<sup>2</sup>

Laparoscopic surgery for adrenal disease is preferable to open surgery due to better safety, less blood loss, shorter operative times, less morbidity, greater cosmesis and more rapid patient recovery.<sup>3,4</sup> It is considered to be the standard of care for most surgically resectable adrenal lesions.

Nowadays, role of open adrenalectomy is very limited; it is indicated in malignant large adrenocortical tumours due to the risk of tumour cell dissemination or haemodynamic instability and in other adrenal tumours which are not amenable to LA. The OA is associated to more bleeding, greater postoperative pain and longer stay in hospital resulting in higher morbidity and mortality rate.<sup>5</sup>

The debate is continue on the indication to LA for lesions >6 cm, some surgeons are in support but others are against it.<sup>6-8</sup> Although there is current controversy in the laparoscopic management of large and metastatic adrenal masses, but it is the recommended method of surgery for benign adrenal masses.<sup>9,10</sup>

Trans peritoneal laparoscopic adrenalectomy (TLA) is considered a standard technique to manage the functioning and non-functioning adrenal diseases, even with large masses up to 12-15 cm can be treated by TLA.<sup>1,11</sup> However, there are some disadvantages of trans peritoneal approach, such as ileus after surgery, risk of visceral damage and CO<sub>2</sub> retention.<sup>12</sup>

The first retroperitoneal laparoscopic adrenalectomy (RLA) was reported in 1994.<sup>13</sup> RLA is now considered as a better method for small benign (less than 6 cm) adrenal tumours.<sup>14</sup> Several studies have demonstrated that, as compared to TLA, RLA has some advantages, including direct access to the adrenal gland, no manipulation of peritoneal organs, less blood loss, shorter operation times, less postoperative pain, shorter length of hospital stay and improved cosmesis.<sup>15-17</sup> In contrast, a smaller working space, possibility of kidney injury and a longer learning curve are the drawbacks to RLA.<sup>18</sup> The safety and feasibility of both retroperitoneoscopic and transperitoneal approaches have been proven; but, there is certain debate about superiority among them.

In this study, cases of RLA were analysed over the last 3 years at the institution. The aims of this study were to describe the 3 years' experience with RLA for adrenal diseases and to evaluate the feasibility, safety and outcomes of this approach in the management of adrenal pathologies.

## METHODS

A retrospective study was done from August 2014 and December 2017, data of 44 patients who underwent retroperitoneal laparoscopic adrenalectomy (RLA) in the institute were retrospectively reviewed.

### Inclusion criteria

- Patients age less than 70 years,
- Adrenal benign functioning tumours up to 6 cm in diameter,
- Patients with good cardiopulmonary performance status.

### Exclusion criteria

- Tumour size larger than 6 cm,
- Patients with suspected primary malignant adrenal tumour (local invasion or metastases, on the basis of imaging examinations),
- Patient had a bleeding diathesis,
- Patient with skeletal deformity.

All patients were assessed by history, physical examinations, laboratory values (including haemogram, renal function and liver function test, serum electrolytes and coagulation profile along with biochemical marker testing) chest X-ray, ECG and imaging techniques.

As per the patient history and physical examinations, relevant hormonal tests were performed including serum cortisol levels, 24-hour urinary free cortisol level, 24 hour urinary meta-nephrines, nor-metanephrines, vanillyl-mandelic acid levels, plasma aldosterone, plasma renin and aldosterone/renin ratio (ARR).

To determine the localization and diameter of adrenal mass computed tomography (CT)/magnetic resonance imaging (MRI) was used.

### **Patient selection**

Indications for adrenalectomy included functioning adrenal masses, symptomatic non-functioning masses, suspicious masses for malignancy, masses showing a tendency for growth with time or incidentaloma.

### **Pre-operative management**

Patients with the diagnosis of pheochromocytoma (PCC) were advised for cardiology evaluation and subsequent prescription of alpha and beta blocker for blood pressure regulation at least 14 days prior to surgery. These patients were also admitted preoperatively for adequate control of blood pressure and adequate hydration by crystalloid solutions prior to the surgery. In patients of Conn's disease with low serum levels of potassium, therapy with potassium and spironolactone was given in preoperative period.

Informed consent was obtained from all patients, which mentioned the potential risks and benefits of proposed operation. All the operations were performed with retroperitoneal laparoscopic approach by single surgeon, experienced in laparoscopic surgery, assisted by skilled collaborative team.

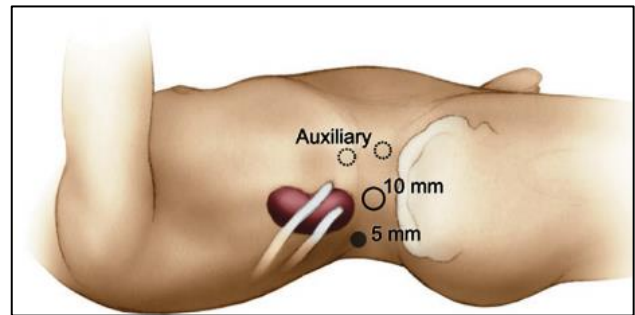
### **Intra-operative management**

All patients received general anaesthesia with endotracheal intubation. Anaesthesia chart and pathology lab reports of all patients were collected. Systolic blood pressure (SBP) levels <90 mmHg were considered hypotensive and SBP  $\geq$ 180 mmHg were considered hypertensive crises. Combination of nitroprusside (0.2-10  $\mu$ g/kg/min) and short-acting beta-blockers (esmolol intravenously) was used to manage intraoperative hypertension.

### **Surgical technique**

After GA and intubation, patient placed in flank position with lateral flexion and the kidney rest was elevated to accentuate the flank. Near the tip of the 12th rib a 10 mm incision was made, underlying muscle and fasciae were divided until the lumbodorsal fascia was reached. The lumbodorsal fascia was also divided and then by blunt dissection a plane between the psoas fascia and the posterior Gerota fascia was created. Then a retroperitoneal dissection balloon (custom made balloon of excised glove finger tied over suction catheter) was placed and inflated for 10 minutes. Entry in the correct plane was assured by laparoscope then trocar was placed and secured. After insufflation of retro peritoneum, a 5 mm trocar was placed at the angle of origin of the 12th rib and paraspinous muscle. Another 10-mm trocar was placed near the

anterior superior iliac spine about two fingerbreadths above the iliac crest (Figure 1).



**Figure 1: Port position in RLA.**

Three trocars were used for left or right adrenalectomy and an additional trocar used whenever required.

The initial part of dissection for adrenal tumour involved determining the upper pole of kidney. The dissection was directed medially, between the crura of the diaphragm and adrenal gland. At the beginning of surgery, main adrenal vein was identified, dissected and divided between clips then other vessels were isolated, and sealed. Lastly, the adrenal gland with tumour was dissected free completely and disposed of in a plastic bag and then retrieved via an extended muscle-splitting port side incision. The retroperitoneal space was examined for haemostasis; a drain was placed and port side closed.

### **Postoperative management**

All patients were administered with fluids, postoperative hypotensive episodes were managed by intravenous crystalloids infusions and hydrocortisone.

Early mobilization and feeding were started on the first postoperative day. Drain was removed on the first/second post-operative day. Cortisol-secreting adenoma patients were managed with intravenous stress doses of hydrocortisone or prednisolone on the day of surgery, after that steroid replacement therapy was given orally.

Patients' follow up consisted of clinical evaluation and blood test 1 week after discharge, then again after 4 weeks followed by half-yearly. An endocrine evaluation was performed once a year to exclude recurrence.

### **Data collection**

- Patient's evaluation included pre-operative, intra-operative and post-operative data.
- Patients' demographic data and other data regarding comorbidities, previous abdominal operations, indication for surgery, tumour size, tumour side, operation time, haemoglobin drop, blood transfusion, conversion rate, length of postoperative hospital stay, and complications were collected and analysed.

The operating time was defined as the time from entry of the telescope and working ports to closure of the incision after removing the adrenal mass from the body.

**Statistical analysis**

All variables were categorical and percentage and proportions were calculated manually.

**RESULTS**

Total 44 patients were analysed, comprising 24 (54.55%) males and 20 (45.45%) females. The mean age was of 47.0±8.9 years. The mean body mass index (BMI) was 23.5±2.2 kg/m<sup>2</sup>. Total 26 (59.09%) cases were of right-sided and 18 (40.90%) cases were of left-sided adrenal tumours.

The mean size of the adrenal mass was 2.6±0.85 cm. During preoperative evaluation 10 patients were affected by PCC, 8 by Cushing’s disease. Conns disease was diagnosed in 6 patients, while in remaining 20 patients tumour were non-functioning. History of previous abdominal surgery was present in 6 cases (Table 1).

**Table 1: Demographics and tumour characteristics.**

Variable	All patients (Total N = 44)
Age in years (mean, range)	47.0±8.9 (30- 63)
Male and female ( ratio)	24/20
BMI in kg/m <sup>2</sup> (mean, range)	23.5±2.2 (19.3- 27.4)
Adrenal tumour size in cm (mean, range)	2.6±0.85 (1.4- 4.0)
Right and left	26/18
Hormonal diagnosis:	
Pheochromocytoma	10
Cushing’s disease	8
Conn’s disease	6
Non-functioning tumour	20
Comorbidities - Diabetes	5
Hypertension heart disease	10
Renal insufficiency	2
Previous abdominal surgery	6

Regarding surgery the mean operative time of RLA was 109.1±21.16 minutes. Mean haemoglobin drop was 0.47±0.26 gram/L. Out of 44 patients 2 patients required blood transfusion (4.5%) because of intraoperative bleeding and both were converted to open surgery (Table 2).

Intraoperative hypertensive crises were reported in 8 cases (70% in PCC patients, 12.5% in cushing patients, in 1 case at the time of induction, in 7 cases during adenoma manipulation) and hypotensive crises in 2 cases, but all patients were promptly and successfully managed.

Among the intra-operative complications, there was one case of inferior vena cava injury which was converted to open and managed by suture and floseal. Another case of diaphragm injury due to pleural cavity opening was successfully treated without conversion. There were no postoperative major complications in any patients. Mean post-operative hospital stay was 4.0±0.91 days. Recovery time mean value was 12.18±1.7 days after the day of surgery (Table 2).

**Table 2: Perioperative and post-operative outcome.**

Factor	All patients (N =44)
Operation time (minutes) (mean, range)	109.1±21.16 (78-172)
Haemoglobin drop (gram/l) (mean, range)	0.47±0.26 (0.1-1.4)
Blood transfusion	2/44 (4.5%)
Hypertensive crises (SBP > 180 mmHg)	8/44
Hypotensive crises (SBP < 90 mmHg)	2/44
Mortality	0
Conversion to open procedure	2/44 (4.5%)
Complications	3/44
Post-operative hospital stay (in days)	4.0±0.91 (3-7)
Recovery time ( in days)	12.18±1.7 ( 9-16)

**Table 3 Post-operative histopathological diagnosis.**

Histopathology	Number of cases
Adenoma	25
Pheochromocytoma	10
Adrenal lipoma	4
Adrenocortical Carcinoma	2
Benign cystic lesion	2
Myelolipoma	1

In final histopathology result adenoma was most prevalent which was found in 25 cases, PCC was identified in 10 cases, adrenal lipoma in 4, benign cystic lesion in 2, adrenocortical carcinoma in 2 and myelolipoma was identified in 1 case (Table 3). Overall 30-day morbidity rate was 6.8% (3/44 patients) and consisted of one case of abdominal wall hematoma, one case of port site hernia and one case of delayed wound healing in a diabetic patient.

After surgery hormonal serum levels normalization was seen in all patients diagnosed with functional adenoma.

**DISCUSSION**

Nowadays there is prominence of minimally invasive treatments, in place of open surgery laparoscopic and robotic methods have started to be used. Following the description of first minimally invasive adrenalectomy by Gagner, laparoscopic adrenalectomy (LA) gradually

became popular among surgeons and considered as a treatment method.<sup>19</sup> Laparoscopic approach is now used as a standard method in the surgical treatment of adrenal tumour.<sup>20</sup>

LA allowed a reduced ileus, decreased postoperative pain, a shorter hospitalization, a better cosmetic result, an earlier return to work with a lower morbidity (less than 20%) and mortality rates (below 0.5%).<sup>21,22</sup> On the other hand, open adrenalectomy associated to higher mortality (1-4%) and morbidity rates (pulmonary and cardiac issues, bleeding, wound infections, pulmonary thromboembolism) and is reserved only for large adrenal tumours (diameter > 6 cm) or primary malignancies, based on the complete resection, minimum tumour local recurrence and major survival.<sup>23,24</sup>

Although different laparoscopic surgical techniques have been described to deal with adrenal tumours such as anterior, posterior, lateral and retroperitoneal approaches, the trans peritoneal lateral approach (TLA) is most commonly used.<sup>25</sup> The most important advantages of the trans peritoneal method are that, it provides a larger working area and clearer visualisation of the surrounding structures as well as most familiar anatomy for surgeons.<sup>26</sup> However, in this approach there is need to mobilize intra-abdominal organs and structures, which has a high risk for vascular or organ injury. Because most of the laparoscopic surgeons feel safer and more confident when working in larger peritoneal space, they are recalcitrant to use the RLA approach.<sup>27</sup>

RLA have proven benefits comparing to the transperitoneal approach, it provides a direct and rapid access to the adrenal gland without entering into the intraperitoneal cavity eliminating the risk of trauma to abdominal viscera. In the patients with previous laparotomy procedures there is always a risk of adhesions; in such condition also it is very helpful.

Another advantage in RLA is a limited need to retract the spleen, pancreas or liver to expose the adrenal glands, because TLA in the lateral decubitus position requires detachment of the splenic attachment from the lateral abdominal wall on the left side and mobilization of the right lobe of liver on the right side. An enlarged liver which makes its retraction difficult with right adrenal tumours is another indication for the retroperitoneal approach.

RLA is superior in terms of intraoperative blood loss, complication, post-operative hospitalization, first oral intake and time to ambulation. Because of small incision and slight tissue injury the bleeding in RLA will inevitably be less.

A balloon was used for retroperitoneal space creation because it is rapid and without anatomical distortion. The anatomy of retroperitoneal space provides fewer landmarks only than the intra peritoneal space. However, the quadratus lumborum muscle, lateroconal fascia and the

kidney provide enough guidance to find the adrenal gland. To expose the adrenal gland, removal of the fat surrounding the upper pole of kidney is essential.

Initially patients with tumour size smaller than 7 cm were qualified for RLA. With the advancement of minimally invasive surgery, literature constantly showed that the larger adrenal tumours can also be managed by RLA approach.

For adrenal tumours less than 6 cm size, the risk of malignancy is 1 in 10,000 as demonstrated by Gajraj and Young.<sup>28</sup> In present study 6 cm was considered as the upper limit of adrenal mass amenable to a retroperitoneal approach. However in the literature, tumour of size as small as 3 cm have been described as primary adrenal cancers.<sup>29</sup> Therefore, to differentiate between benign and malignant adrenal tumours the tumour size alone is not sufficient.

For tumours larger than 6 cm size without malignant features, a trans peritoneal technique was preferred, with the patient in a lateral decubitus position as described by Gagner et al because of larger space of intraperitoneum for safe dissection of larger tumours.<sup>2</sup>

In the literature of adrenalectomy, the mean age of patients to have an adrenal tumour is around 45 and 50.<sup>30</sup> In present study, the age of the patients ranged from 30 to 63 years and mean was  $47.0 \pm 8.9$  years. As compare to male, greater numbers of females have a tendency to be determined to have adrenal tumours.<sup>31</sup> Present study result is different from this perception. Mean adrenal tumour size was  $2.6 \pm 0.85$  cm which is lesser than the other reported series. Present study data of preoperative outcomes are similar with the data in the literature described by an experienced laparoscopic surgeon's group.<sup>32</sup>

According to several studies RLA is easier to perform and is associated with lesser pain in the postoperative period.<sup>18,33</sup> Another advantage of RLA is shorter operative time than TLA.<sup>34</sup> It can be performed safely and efficiently in patients with significant comorbidities.

Initially the duration of RLA procedure was more; long operative time was reported by Yoshimura et al. with laparoscopic adrenalectomy, but gradually with experience gained, it was decreased very much.<sup>35</sup> Lin et al. showed a learning curve of 60 patients, when concerned at blood loss and operating times, for RLA.<sup>36</sup> Cabalag et al showed a short learning curve of 10 patients in RLA (duration of surgery was 110-60 minute) after a training course.<sup>37</sup> Walz et al, reported the mean operative time for more than 500 LRA procedures was reduced to 40 minutes.<sup>33</sup> In present study the mean operation time was  $109.1 \pm 21.16$  minutes, which was much higher than Walz et al but near to Cabalag et al.

As compared to other adrenal lesions laparoscopic surgery of PCC has been reported to be more difficult even for



experienced surgeons.<sup>38</sup> To decrease the risk of intraoperative pressure rise during PCC resection, tumour mobilization was avoided before sealing the adrenal vessels. A preoperative selective adrenergic blockade did not prevent intraoperative hypertensive episodes (7 out of 10 cases of PCC) in every patient, occurred principally during manipulation of tumour, and promptly treated by anaesthesiologists. In these difficult cases anytime sudden bleeding can start so procedure should only be started after the preoperative blood arrangement and to make the necessary rapid intervention the anaesthetist must be warned for central catheterisation or broad vascular route.

For the management of malignant adrenal tumours the use of laparoscopic interventions remains controversial.<sup>39</sup> In the study the patients diagnosed with adrenocortical carcinoma were excluded. Despite this radical exclusion, histopathological analyses of removed specimen revealed 2 cases of adrenocortical carcinoma (ACC). During follow-up examinations up to 6 months in these 2 patients there was no evidence of recurrence.

RLA approach was safe, effective, well tolerated, with a negligible complication rate. We reported only two cases of conversion to open surgery (4.5%), due to intraoperative bleeding. Whenever, risky complications occur in laparoscopic technique, a rapid conversion is mandatory to avoid life threatening events.<sup>21</sup> The postoperative hospital stay in the series was  $4.0 \pm 0.91$  days, which is quite less than other Centres.<sup>40</sup>

In final histopathology results, adenoma was most commonly reported tumour; PCC was second most common, while myelolipoma was least common. There is a large series published by Bonjer and co-workers, which reported very promising results of retro peritoneoscopic adrenalectomy.<sup>41</sup>

The most common method used to treat the adrenal tumours in China is lateral retroperitoneoscopic adrenalectomy which is promoted by Zhang et al.<sup>42</sup> RLA may be the preferred approach in patients with tumour diameter <6 cm, body mass index of <35 kg/m<sup>2</sup> and tumour with low suspicion of malignancy.

Overall, it is important to consider that in the adrenal gland surgery, a multidisciplinary approach is required which comprises surgeons, endocrinologists, anaesthesiologists and oncologists and the success of the procedure is also related to surgeons skills, experience and hospital volume.

In authors' opinion, the choice of the approach should be made based primarily on surgical experience, patient characteristics, as well as tumour size and location. RLA is the recommended approach to the resection of small and medium size (< 6 cm) adrenal tumours.

The study has some limitations. First, the study design was retrospective; second it was undertaken with a limited number of patients at a single centre so the potential

selection bias cannot be eliminated. In future, randomized prospective trials are required for validation of these results. However, the study results indicate excellent outcome without significant morbidity.

## CONCLUSION

However TLA is most commonly used method worldwide for the management of adrenal tumour, RLA offers an alternative method for treating adrenal tumour with improved surgical outcomes. This approach has a learning curve; it should be performed by a surgeon experienced in both laparoscopic and open adrenal surgery. RLA seems to be good and effective treatment for patients with a medium sized adrenal tumour in particular less than 6 cm. It is technically safe and feasible and associated with less blood loss, shorter hospitalization, low conversion rate, fewer complications and early recovery. Laparoscopic experience and surgical skill are important factors to achieve consistently good outcomes. The results will contribute the positive, safer and low-risk outcomes of RLA in the literature.

*Funding: No funding sources*

*Conflict of interest: None declared*

*Ethical approval: Not required*

## REFERENCES

- Gagner M, Lacroix A, Bolté E. Laparoscopic adrenalectomy in cushing's syndrome and pheochromocytoma. N Engl J Med. 1992;327:1033.
- Lezoche E, Guerrieri M, Crosta F. Perioperative results of 214 laparoscopic adrenalectomies by anterior transperitoneal approach. Surg Endosc. 2008;22:522-6.
- Sardi A, McKinnon W. Laparoscopic adrenalectomy for primary aldosteronism. JAMA. 1993;269:989-90.
- Go H, Takeda M, Takahashi H, Imai T, Tsutsui T, Mizusawa T, et al. Laparoscopic adrenalectomy for primary aldosteronism: a new operative method. J Laparoendosc Surg. 1993;3:455-9.
- McLeod KM, Arbor A. Complications following adrenal surgery. J Natl Med Assoc. 1991;83(2):161-4.
- Conzo G, Pasquali D, Gambardella C, Pietra DC, Esposito D, Napolitano S, et al. Long-term outcomes of laparoscopic adrenalectomy for Cushing disease. Int J Surg. 2014;12:107-11.
- Serji B, Souadka A, Benkabbou A, Hachim H, Jaiteh L, Mohsine R, et al. Feasibility and safety of laparoscopic adrenalectomy for large tumours. Arab J Urol. 2016;14:143-6.
- Henry JF, Sebag F, Iacobone M, Mirallie E. Results of laparoscopic adrenalectomy for large and potentially malignant tumors. World J Surg. 2002;26:1043-7.
- Guazzoni G, Montorsi F, Boccardi A, Pozzo DL, Rigatti P, Lanzi R, et al. Transperitoneal laparoscopic versus open adrenalectomy for benign

- hyperfunctioning adrenal tumors: a comparative study. *J Urol.* 1995;153:1597-600.
10. Zografos GN, Farfaras A, Vasiliadis G, Pappa T, Aggeli C, Vassilatou E, et al. Laparoscopic resection of large adrenal tumors. *JLS.* 2010;14:364-8.
  11. Brunt LM. The positive impact of laparoscopic adrenalectomy on complications of adrenal surgery. *Surg Endosc.* 2002;16:252-7.
  12. Cruz FL, Saenz A, Benarroch G, Astudillo E, Taura P, Sabater L. Laparoscopic unilateral and bilateral adrenalectomy for cushing's syndrome transperitoneal and retroperitoneal approaches. *Ann Surg.* 1996;224:727-34.
  13. Gaur DD. Retroperitoneoscopy: the balloon technique. *Ann R Coll Surg Engl.* 1994;76(4):259-63.
  14. Walz MK, Peitgen K, Hoermann R, Giebler RM, Mann K, Eigler FW. Posterior retroperitoneoscopy as a new minimally invasive approach for adrenalectomy: results of 30 adrenalectomies in 27 patients. *World J Surg.* 1996;20:769-74.
  15. Walz MK, Peitgen K, Walz MV, Hoermann R, Saller B, Giebler RM, et al. Posterior retroperitoneoscopic adrenalectomy: lessons learned within five years. *World J Surg.* 2001;25:728-34.
  16. Conzo G, Tartaglia E, Gambardella C, Esposito D, Sciascia V, Mauriello C, et al. Minimally invasive approach for adrenal lesions: systematic review of laparoscopic versus retroperitoneoscopic adrenalectomy and assessment of risk factors for complications. *Int J Surg.* 2016;28:118-23.
  17. Chai YJ. Systematic review of surgical approaches for adrenal tumors: lateral transperitoneal versus posterior retroperitoneal and laparoscopic versus robotic adrenalectomy. *Int J Endocrinol.* 2014;9:91-3.
  18. Rubinstein M, Gill IS, Aron M, Kilciler M, Meraney AM, Finelli A, et al. Prospective, randomized comparison of transperitoneal versus retroperitoneal laparoscopic adrenalectomy. *J Urol.* 2005;174:442-5.
  19. Paganini AM, Balla A, Guerrieri M, Lezoche G, Campagnacci R, D'Ambrosio G, et al. Laparoscopic transperitoneal anterior adrenalectomy in pheochromocytoma: experience in 62 patients. *Surg Endosc.* 2014;28:2683-9.
  20. Rieder JM, Nisbet AA, Wuerstle MC, Tran VQ, Kwon EO, Chien GW. Differences in left and right laparoscopic adrenalectomy. *JLS.* 2010;14:369-73.
  21. Pędziwiatr M, Wierdak M, Ostachowski M, Natkaniec M, Białas M, Hubalewska DA, et al. Single center outcomes of laparoscopic transperitoneal lateral adrenalectomy lessons learned after 500 cases: a retrospective cohort study. *Int J Surg.* 2015;20:88-94.
  22. Murphy MM, Witkowski ER, Ng SC, Mcdade TP, Hill JS, Larkin AC, et al. Trends in adrenalectomy: a recent national review. *Surg Endosc.* 2010;24:2518-26.
  23. Miller BS, Gauger PG, Hammer GD, Doherty GM. Resection of adrenocortical carcinoma is less complete and local recurrence occurs sooner and more often after laparoscopic adrenalectomy than after open adrenalectomy. *Surg.* 2012;152:1150-7.
  24. Cooper AB, Habra MA, Grubbs EG, Bednarski BK, Ying AK, Perrier ND, et al. Does laparoscopic adrenalectomy jeopardize oncologic outcomes for patients with adrenocortical carcinoma? *Surg Endosc.* 2013;27:4026-32.
  25. Cianci P, Fersini A, Tartaglia N, Ambrosi A, Neri V. Are there differences between the right and left laparoscopic adrenalectomy? Our experience. *Ann Ital Chir.* 2016;87:242-6.
  26. Özgör F, Binbay M, Akbulut MF, Şimsek A, Şahan M, Berberoğlu AY, et al. Laparoscopic transperitoneal adrenalectomy: Our initial results. *Turk J Urol.* 2014;40:99-103.
  27. Lee CR, Walz MR, Park S, Park JH, Jeong JS, Lee SH. A comparative study of the transperitoneal and posterior retroperitoneal approaches for laparoscopic adrenalectomy for adrenal tumors. *Ann Surg Oncol.* 2012;19:2629-34.
  28. Gajraj H, Young AE. Adrenal incidentaloma. *Br J Surg.* 1993;80:422.
  29. Linos DA, Stylopoulos N, Raptis SA. Adrenaloma: a call for more aggressive management. *World J Surg.* 1996;20:788-93.
  30. El Kappany, Shoma AM, El Tabey, El Nahas, Eraky II. Laparoscopic adrenalectomy: a single-center experience of 43 cases. *J Endourology.* 2005;19(10):1170-3.
  31. Mihai R. Diagnosis, treatment and outcome of adrenocortical cancer. *British J Surg.* 2015;102(4):291-06.
  32. Greco F. Laparoscopic adrenalectomy in urological centres the experience of the German Laparoscopic Working Group. *BJU Int.* 2011;108(10):1646-51.
  33. Walz MK, Alesina PF, Wenger FA, Koch JA, Neumann HP, Petersenn S, et al. Posterior retroperitoneoscopic adrenalectomy results of 560 procedures in 520 patients. *Surg.* 2006;30:899-908.
  34. Chen W, Li F, Chen D. Retroperitoneal versus transperitoneal laparoscopic adrenalectomy in adrenal tumor: a meta-analysis. *Surg Laparosc Endosc Percutan Tech.* 2013;23(2):121-7.
  35. Yoshimura K, Yoshioka T, Miyake O, Matsumiya K, Miki T, Okuyama A. Comparison of clinical outcomes of laparoscopic and conventional open adrenalectomy. *J Endourol.* 1998;12(6):555-9.
  36. Lin Y. Experience of retroperitoneoscopic adrenalectomy in 195 patients with primary aldosteronism. *Int J Urol.* 2007;14(10):910-3.
  37. Cabalag MS, Mann GB, Gorelik A, Miller JA. Posterior retroperitoneoscopic adrenalectomy: outcomes and lessons learned from initial 50 cases. *Anz J Surg.* 2015;85(6):478-82.
  38. Natkaniec M, Pędziwiatr M, Wierdak M, Białas M, Major P, Matłok M, et al. Laparoscopic adrenalectomy for pheochromocytoma is more difficult compared to other adrenal tumors.

- Wideochir Inne Tech Maloinwazyjne. 2015;10:466-71.
39. Przytulska J, Rogala N, Tupikowska BG. Current and emerging therapies for adrenocortical carcinoma review. *Adv Clin Exp Med.* 2015;24:185-93.
40. Castilho LN, Mitre AI, Arap S. Laparoscopic adrenalsurgery in a Brazilian center. *J Endourol.* 2003;17:11-8.
41. Bonjer HJ, Sorm V, Berends FJ. Endoscopic retroperitoneal adrenalectomy: lessons learned from 111 consecutive cases. *Ann Surg.* 2000;232:796-803.
42. Zhang X, Fu B, Lang B. Technique of anatomical retroperitoneoscopic adrenalectomy with report of 800 cases. *J Urol.* 2007;177(4):1254-7.

**Cite this article as:** Thakur APS, Venugopal G, Darsan S. Retroperitoneal laparoscopic adrenalectomy: its role in the management of adrenal tumour and tertiary care centre experience. *Int J Res Med Sci* 2020;8:993-1000.