

## Case Report

# A rare case of a giant epidermal cyst over the back

Neeraj Bansal\*, Ankita Vergadia, A. N. Mashke, Aashirwad Datey

Department of Surgery, Peoples College of Medical Sciences, Bhanpur, Bhopal, Madhya Pradesh, India

**Received:** 27 December 2019

**Revised:** 15 January 2020

**Accepted:** 28 January 2020

**\*Correspondence:**

Dr. Neeraj Bansal,

E-mail: [neeraj.grmc12@gmail.com](mailto:neeraj.grmc12@gmail.com)

**Copyright:** © the author(s), publisher and licensee Medip Academy. This is an open-access article distributed under the terms of the Creative Commons Attribution Non-Commercial License, which permits unrestricted non-commercial use, distribution, and reproduction in any medium, provided the original work is properly cited.

### ABSTRACT

Epidermoid cysts are commonly called as sebaceous cysts that mostly occur in the subcutaneous plain. Giant epidermoid cysts are rare and generally greater than 5 cm in size. Few cases of malignant transformation of the sebaceous cysts have also been reported in literature.

**Keywords:** Epidermal cysts, Giant, Malignant, Rare

## INTRODUCTION

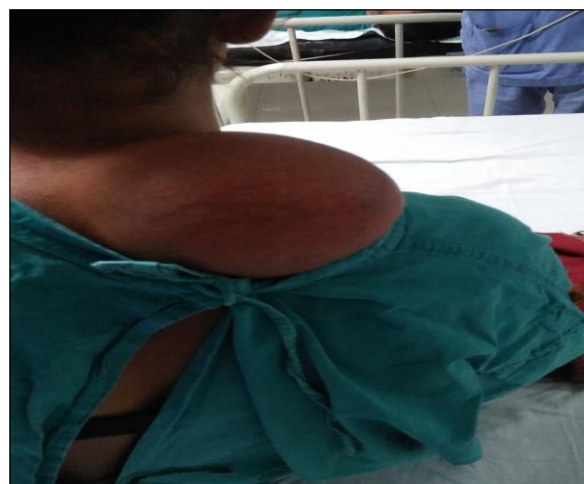Epidermal cysts, also called as sebaceous cyst is a unilocular retention cyst containing keratin which is intra-dermal in origin and being adherent to the epidermis.<sup>1</sup> This is the most common cutaneous cyst. These usually present as a painless mobile swelling, sometimes an infected cyst can present as a painful swelling. A giant epidermoid cyst is defined as being more than 5 cm in any dimension.<sup>2</sup>

These can occur at any site on the body except the palm and soles. Clinical examination with preoperative fine-needle aspiration gives the diagnosis. Sometimes radiological investigations may be needed. A giant epidermoid cyst may get secondarily infected, may lead to pressure over the underlying bone and rarely undergoes malignant transformation.

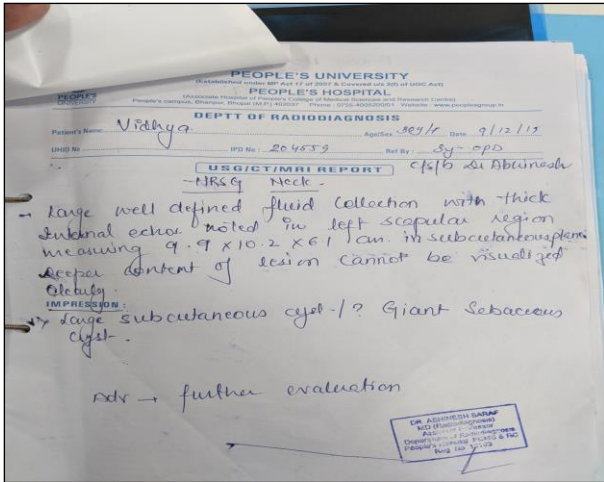
Epidermoid cysts have a well-developed granular cell layer and are lined by stratified squamous epithelium; rarely, pseudo-stratified ciliated columnar epithelium may be present on the cyst wall.<sup>3</sup> The cyst wall can have dystrophic type calcification. Excision is the treatment of choice. The aim was to study the occurrence of giant sebaceous cyst.

## CASE REPORT

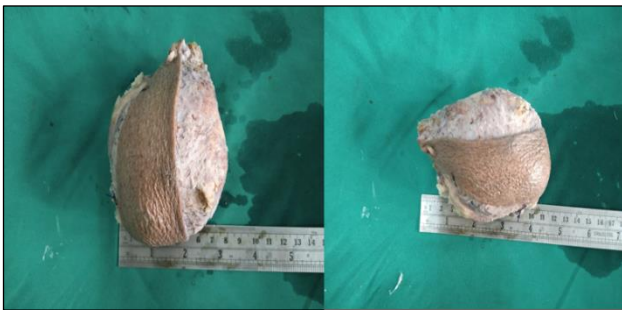A 38-year-old female patient presented to the surgery department with the complain of a slowly growing painless swelling over the back at the right side for last 4 years. The swelling was about 1 cm in size when she first noticed and since then its growing slowly.



**Figure 1: Giant epidermal cyst over the right upper back.**

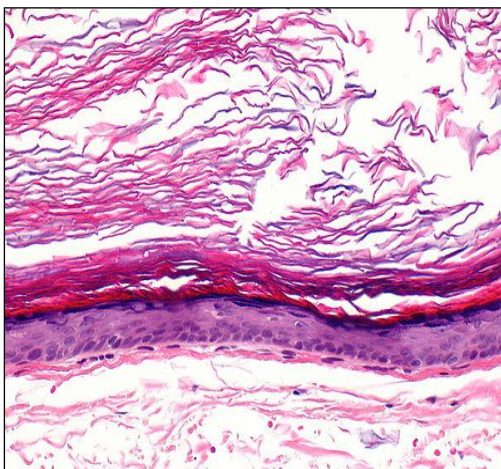


**Figure 2: Ultrasound showing giant epidermal cyst in the subcutaneous plane of the right upper back.**



**Figure 3: Surgical excision of the epidermal cyst that revealed well defined margins with elastic texture and contained a cream coloured fluid with butter like consistency.**

There was no pain or discharge associated with the swelling. The swelling had gradually increased in size over past 1 year to attain the present size of 10 \*10 \* 6 cm.



**Figure 4: Histopathological showed epidermal cyst wall with a thin layer of benign stratified squamous epithelium and lamellated keratin debris.**

Clinical examination of the swelling revealed a soft cystic painless swelling with smooth surface and well-defined margins over the right back region with no central black punctum (Figure 1). The diagnosis was confirmed by ultrasound (Figure 2) fine needle aspiration cytology and computed tomography. Excision of the swelling was done (Figure 3) that showed elastic texture and contained a cream-colored fluid with butter like consistency and primary closure over a drain. Histopathology (Figure 4) of the specimen revealed cyst with stratified squamous epithelium lining containing keratin debris. No malignant change was reported on histopathology. At the follow up examination at regular intervals of 15 days authors found no local recurrence of the lesion.

**DISCUSSION**

Giant epidermoid or sebaceous cyst is rarely seen in a surgical practice.<sup>4,5</sup> These can occur at any age, rare before puberty, and the most common age of presentation is a young adult male. The most common site of occurrence is the face, trunk, neck, scalp, scrotum, ear lobe and breast but, location at an unusual site raises concern.<sup>6</sup> Rarely, they may occur in a setting of hereditary syndromes like Gardner’s syndrome, basal cell nevus syndrome and pancyonchia congenital.<sup>7</sup> These are common in females usually on the scalp, more in people working in outdoor conditions with sunlight exposure and unhygienic concerned areas. On the scalp, it occurs in an area located in a line drawn along the hair line passing through the upper border of the ear lobule and joining these two lines at the occipital area. This is a retention type of cyst and usually occur as a result of migration of the epidermal cells into the dermis. They are lined with stratified squamous epithelium and contain keratin. Normal size varies from a few millimeters to a few centimeters but when the size exceeds 5 cm, it is referred to as a giant sebaceous cyst. The detection of small cysts and evolving into giant cysts takes years and it grows usually at a rate of not more than 0.5 cm per year. In the initial years, growth is more rapid than after attaining large size. Neglect on part of the patient in seeking surgical advice when the cyst is small leads to formation of a giant epidermoid cyst. Sebaceous cyst is a subcutaneous swelling with a punctum which is a hallmark in diagnosis. It is difficult to detect a punctum in large sebaceous cyst. Punctum in a giant sebaceous cyst is difficult to detect as swelling enlarges, because more and more hair follicles overlying it make it difficult to detect and makes them wider follicles. Giant epidermoid cysts have a propensity to develop malignancy.<sup>8</sup> Various types of malignancy that can arise from a giant sebaceous cyst are squamous cell carcinoma, basal cell carcinoma, mycosis fungoides and melanoma.<sup>9,10</sup>

Treatment of a sebaceous cyst is its total excision along with capsule. Authors have presented a rarely encountered case of a giant epidermal cyst over the back region where a total excision was performed, one of the

few cases presented in literature till date.<sup>11,12</sup> Diagnosis is generally achieved by FNAC. MRI is an useful adjunct to establish the diagnosis in atypical locations. Simple excision is the treatment of choice in uncomplicated cases, however in patients with large epidermal cysts and underlying medical disorders, regional perforator island flaps reconstruction has been performed. The outcome of these flaps depends on the underlying disease and the premorbid conditions.

## CONCLUSION

In the present case authors demonstrate that giant epidermal cyst may grow for long duration of time and produce adverse effect due to pressure exerted on the surrounding structures as well as serious cosmetic problems that may require psychiatric counselling. Therefore, early surgical excision is recommended for patients exhibiting giant epidermal cyst.

## ACKNOWLEDGEMENTS

Authors would like to thank their consultant Dr. A. N Mhaske and Dr. Ashirwad Datey for their constant guidance, support, encouragement. Authors would also like to thank Peoples Hospital Bhanpur, Bhopal for giving me this platform.

*Funding: No funding sources*

*Conflict of interest: None declared*

*Ethical approval: Not required*

## REFERENCES

1. Venus MR, Eltigani EA, Fagan JM. Just another sebaceous cyst?. Annal Royal Coll Surg Eng. 2007 Sep;89(6):W19.
2. Basterzi Y, Sari A, Ayhan S. Giant epidermoid cyst on the forefoot. Dermatol Surg. 2002 Jul;28(7):639-40.
3. Dive AM, Khandekar S, Moharil R, Deshmukh S. Epidermoid cyst of the outer ear: A case report and review of literature. Ind J Otol. 2012 Jan 1;18(1):34.
4. Haflah NM, Kassim AM, Shukur MH. Giant Epidermoid Cyst of the Thigh. Malay Orthop J. 2011 Nov;5(3):17.
5. Solak O, Tunay K, Haktanir NT, Ocalan K, Esme H, Tokyol C. Giant epidermoid cyst in the sternum region. Thoracic Cardi Surg. 2008 Jun;56(04):243-5.
6. Handa U, Kumar S, Mohan H. Aspiration cytology of epidermoid cyst of terminal phalanx. Diag Cytopathol. 2002 Apr;26(4):266-7.
7. Swygert KE, Parrish CA, Cashman RE, Lin R, Cockerell CJ. Melanoma in situ involving an epidermal inclusion (infundibular) cyst. Am J Dermatopathol. 2007 Dec 1;29(6):564-5.
8. Sumi Y, Yamamoto N, Kiyosawa T. Squamous cell carcinoma arising in a giant epidermal cyst of the perineum: a case report and literature review. J Plastic Surg Hand Surg. 2012 Sep 1;46(3-4):209-11.
9. Debaize S, Gebhart M, Fourrez T, Rahier I, Baillon JM. Squamous cell carcinoma arising in a giant epidermal cyst: a case report. Acta Chirurgica Belgica. 2002 Jan 1;102(3):196-8.
10. Tanaka M, Terui T, Sasai S, Tagami H. Basal cell carcinoma showing connections with epidermal cysts. Journal of the Eur Acad Dermatol Venereol. 2003 Sep;17(5):581-2.
11. Houdek MT, Warneke JA, Pollard CM, Lindgren EA, Taljanovic MS. Giant epidermal cyst of the gluteal region. Radiol Case Rep. 2010 Jan 1;5(4):476.
12. Kshirsagar AY, Sulhyan SR, Deshpande S, Jagtap SV. Malignant change in an epidermal cyst over gluteal region. J cutan Aesthetic Surg. 2011 Jan;4(1):48.

**Cite this article as:** Bansal N, Vergadia A, Mashke AN, Datey A. A rare case of a giant epidermal cyst over the back. Int J Res Med Sci 2020;8:1169-71.