

Original Research Article

Catheter induced hypospadias, urethral trauma and penile abscess in completely recoverable neurological afflictions: preventable entities

Harbhupinder S. Sandhu*, Harjinder Singh, Amarjit Sharma

Department of Urology, Government Medical College, Patiala, Punjab, India

Received: 15 January 2020

Revised: 29 January 2020

Accepted: 04 February 2020

*Correspondence:

Dr. Harbhupinder S. Sandhu,

E-mail: hssandhudr@gmail.com

Copyright: © the author(s), publisher and licensee Medip Academy. This is an open-access article distributed under the terms of the Creative Commons Attribution Non-Commercial License, which permits unrestricted non-commercial use, distribution, and reproduction in any medium, provided the original work is properly cited.

ABSTRACT

Background: Catheter associated complications are very common in the emergency departments of medicine, general surgery, orthopaedics and in community. They mostly occur in patients with neurological afflictions because of inexperience of the first handlers as they lack the insight of altered physiology and anatomy in the lower urinary tract because of neurological lesions and also because of an inadequate advice at the time of discharge regarding the catheter care. Objectives of this study were to find the prevalence of per-urethral catheter associated injuries in patients with neurological lesions in a tertiary care centre of south-eastern Punjab and their prevention in completely recoverable neurological afflictions.

Methods: This is a cross-sectional observational study conducted in urology department from 1st August 2017-31st August 2018. The data was taken from medicine, general surgery and orthopedic emergency departments. A total of 82 patients were taken from 19-78 years and 49 patients had per-urethral catheter placement. Analysis was done using Statistical Program of Special Sciences, version 20.

Results: It was observed that overall neurological lesions are more common in males (80.48%) as compared to females (19.51%) and distributed over an age range of 19-84 years in both sexes. Out of total patients, 59.75% required per urethral catheterization. The prevalence of per-urethral catheter associated complications was 20.40%.

Conclusions: Insertion of per-urethral catheter is a simple procedure but an error of omission on the part of health professionals' results in a serious complication in a neurological patient. Proper insertion technique and catheter care are to be followed to prevent avoidable complications in this subset of patients.

Keywords: Cerebrovascular accident, Per-urethral catheter, Prolapsed intervertebral disc, Self-clean intermittent catheterization, Suprapubic cystostomy, Urodynamic study

INTRODUCTION

Lower Urinary tract involvement occurs in various neurological diseases like PIVD, Traumatic spine injuries, Transverse myelitis, CVA, Parkinsonism, Multiple sclerosis, Sacral Agenesis etc. Transverse myelitis is a neurological disorder of the spinal cord caused by inflammation at a particular spinal level. This can cause pain, muscle weakness, paralysis, sensory

problems or bladder and bowel dysfunction. Similarly, traumatic spine injuries can cause upper motor neuron or lower motor neuron type of lesions in which lower urinary tract and bowel involvement may occur to variable dimensions. For urinary retention or incontinence patients are usually discharged on PUC. Long term indwelling PUC'S may cause various adverse effects like infection, erosion of urethra or bladder neck esp. in females, urethral stricture, bladder stones etc. The risk of

mechanical injury to urethra and urinary bladder neck by an indwelling catheter increases if it is not held securely to abdominal wall or thigh. A simple adhesive tape can be used to anchor the catheter, but tapes, particularly those containing rubber, can cause irritant and allergic reactions in susceptible patients. Tapes with synthetic adhesives overcome this problem, but they too may sometimes be associated with reactions. Adhesive tapes that are occlusive may cause skin maceration.¹ Spinal cord injury patients, who have neuropathic skin, are vulnerable for developing adverse reaction to adhesive tapes. If an indwelling catheter is to be used for long-term, SPCor SCIC is recommended to prevent complications of long-term urethral catheter drainage.² Amongst all the above-mentioned neurological lesions, Transverse Myelitis needs elaboration as it has a variable outcome.

METHODS

This is a cross-sectional observational study. It was undertaken in the department of urology with patient input from medical, general surgery and orthopedic emergencies between August 2017 to August 2018. Objectives of this study are to find the prevalence of PUC associated injuries in patients with neurological lesions in a tertiary care centre of south-eastern Punjab and their prevention in completely recoverable neurological afflictions. Only patients with neurological lesions and PUC placement were included. Patients who did not require any catheterization, on SPC and external catheter drainage were excluded. Analysis was done using Statistical Program of Special Sciences, version 20. Amongst the catheterized patients who developed complications, authors present four male patients as index cases.

Index case 1

A 30 yr old male presented in medical emergency with a complaint of sudden weakness of lower limb and unable to void for one day. It was preceded by a viral prodrome one week back. On examination there was a sensory impairment below T6 level (Figure 1). Power was grade 0 in both lower limbs, reflexes were brisk and lower abdomen was distended. His basic workup was within normal limit. USG Abdomen showed bladder distension. MRI spine was done which showed high signal intensity on axial T2 weighted images, involving more than two-third of cross-sectional area and central dot sign was present at T6 level. Diagnosed as a case of Acute Transverse Myelitis. Patient was managed conservatively, and PUC placed. Advised Physiotherapy and discharged to follow up in OPD. After two months patient reported with a complaint of swelling on the undersurface of penis. Referred to urology OPD. On examination patient had recovered completely neurologically but the distal penis was swollen, there was a small gangrenous patch over the ventral prepuce with ventral urethral erosion of 2.0 cm from meatus and

catheter was dangling. Patient managed conservatively, TWOC was successful, postvoid residue was insignificant. Hypospadias repair was advised but patient lost to follow-up.

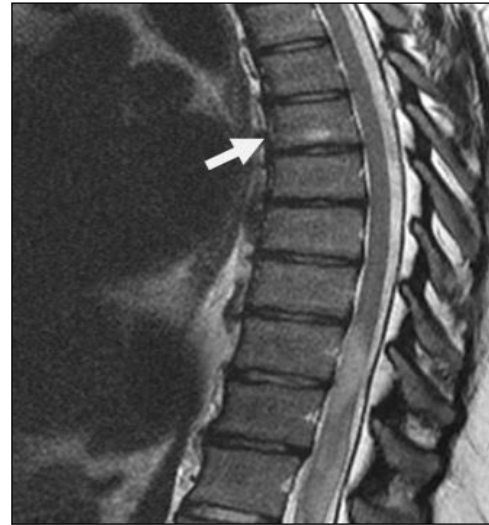

Figure 1: Transverse myelitis t6 vertebra.

Index case 2

A 50 yrs old male patient had a fall from height and got admitted in orthopedic emergency with a complaint of unable to stand and pass urine. On examination, sensations were impaired below C4 dermatomal level and there was grade III power in upper limbs and lower limbs, reflexes were brisk and suprapubic area was distended and dull. Basic investigative workup was within normal limits. MRI cervical spine showed a fracture of spinous process of C4 vertebra (Figure 2). Diagnosed as a case of # C4 spinous process with Quadriplegia with retention urine. PUC was placed and managed conservatively. Discharged after one week with physiotherapy and follow up advise. After four months he was sent for urological consultation regarding catheter status. On examination, upper limbs recovered completely, there was grade III-IV power in lower limbs and was able to walk with support. PUC was in situ but was dangling. There was a ventral slit of approx. 1.5-2.0 cm in urethra (Figure 3).

Bilateral testes were normal. DRE showed grade II prostate which was benign and tender. FNE showed normal perianal sensations, anal tone was adequate, sphincter contractions were adequate but BCR was brisk. CBC, RFT and USG KUB was unremarkable. Urine culture was positive for *E. coli*. Patient was given antibiotics for four weeks along with alpha blocker and tubing was fixed. On subsequent follow up patient recovered completely and came walking to OPD. PUC was removed. TWOC was successful with little splaying of stream and nil postvoid residue on sonography was advised hypospadias repair but refused.

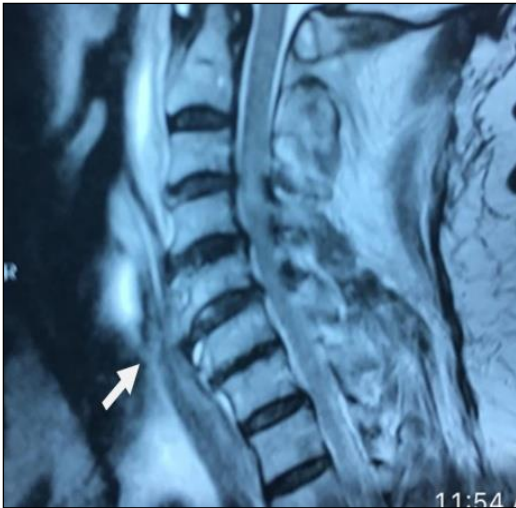

Figure 2: Fracture spinous process C4 vertebra.

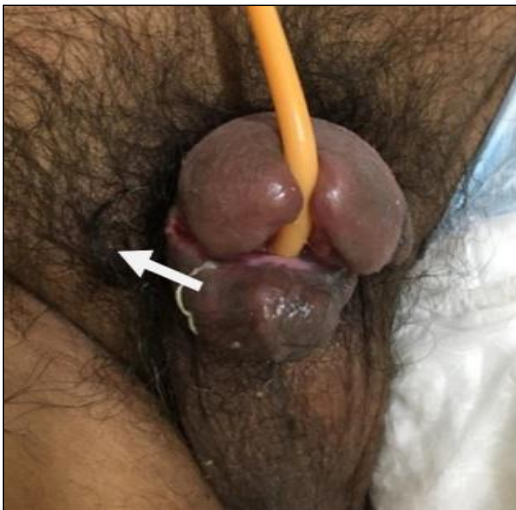

Figure 3: Ventral slit of urethra.

Remarks

These patients were discharged on indwelling Foleys catheter which resulted in erosion of urethra. Ventral erosion of urethra by indwelling catheter can lead to bleeding from raw edges of bifurcated urethra and increased chances of infection because of presence of blood and short urethral length. Such patients on long standing catheters with urethral damage pose a challenge in surgical reconstruction. Most patients have serious comorbidities and single operation does not usually solve all the problems.³ Casey and associates studied eleven patients with neurogenic bladder dysfunction who underwent urethral reconstruction.⁴ Men undergoing reconstruction for urethral erosion had inferior outcomes compared to those with other urethral pathology. Patients with spinal cord injury in whom urethral reconstruction is considered should be advised that urethral surgery carries a high risk of reoperation and eventual need for urinary diversion. Clearly many patients with neurological

disease and severe urethral pathology are best treated with urinary diversion.⁵

The need for urinary diversion can be avoided if spinal cord injury patients are not allowed to develop ventral erosion of urethra by indwelling catheter. Anchoring the drainage tube of urobag to abdomen with an adhesive tape will allow free movement of catheter and avoid any pull on the catheter and penis. When urethral catheter is fixed taut or if it is not fixed but goes around thigh and back of the patient while sleeping and more so if patient develops erection, the indwelling catheter acts as a bowstring and cuts through the urethra (Figure 4). The simple precaution of keeping the catheter free and only adhering the drainage tube to abdomen or thigh prevents catheter induced erosion of urethra. By and large not putting PUC can all together prevent erosion of urethra. Self or assisted CIC is preferable to indwelling urinary catheter drainage. SPC is another alternative which can prevent erosion of urethra but has guarded implications in recoverable neurological afflictions.

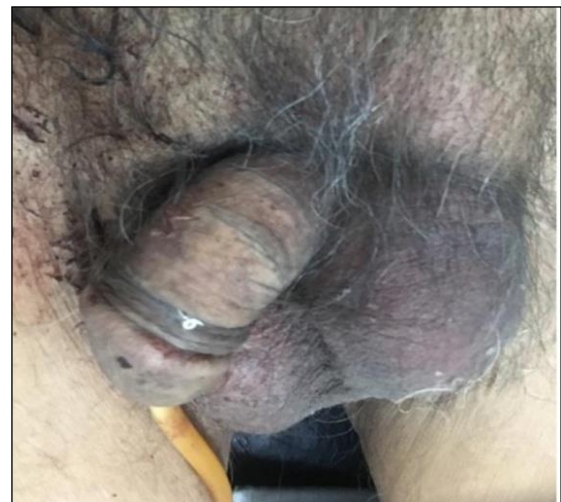

Figure 4: Catheter around thigh.

Index case 3

A 19-year-old male patient with tetraplegia (C 5 incomplete) subsequent to fall in 60 feet deep borewell status post cervical spine fixation in a tertiary care centre was discharged after partial recovery on PUC. He was advised physiotherapy, change of catheter after one month at local hospital and regular follow-ups. The catheter was changed by community health professional in a village and was draining purulent urine partially. On examination patient was lying on stretcher, hemodynamically stable and there was about 200 ml of purulent urine in urobag. He started sweating and his respiration increased with slightest movement of catheter. The catheter shaft appeared little longer, but balloon was not felt in premium. Clinical impression was that Foleys catheter had been placed incorrectly and balloon has been inflated in the urethra. Authors shifted patient to emergency, deflated the balloon

and tried to push the catheter in bladder but patient started sweating, became dysnoeic, had severe bradycardia and hypertensive crises. Immediately injection atropine was given intravenously and capsule nifedipine 10 mg was placed sublingually. There was sudden fall in blood pressure and patient had a cardiac arrest. Injection adrenaline and atropine given intravenously, and CPR started. Patient revived and oxygenated through venti mask. Managed conservatively with i.v antibiotics, antacids, analgesics and on stabilization SPC was done. Subsequently RGU was done which showed that catheter balloon was inflated in prostatic urethra (Figure 5). PUC was placed over guidewire and discharged on SPC and PUC (acting as a splint). He recovered almost completely with residual paresis in left lower limb (Power grade IV) and decreased touch sensations. PUC was removed after four weeks and repeat RGU was done which was normal. SPC was clamped after patient was ambulatory and subsequently removed.

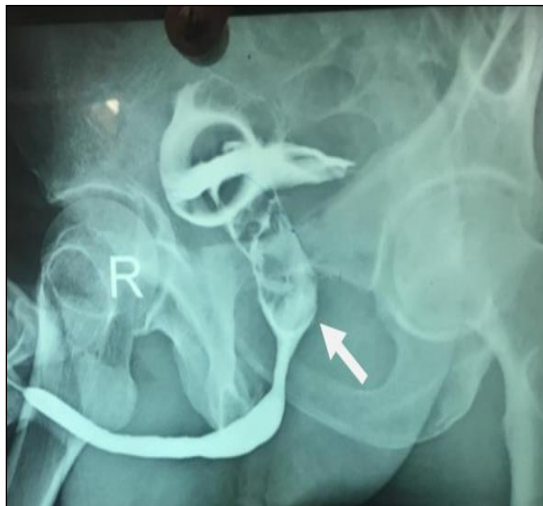

Figure 5: RGU showing catheter balloon inflated in urethra.

Remarks

Placement of urinary catheter in tetraplegic patient requires technical knowledge, judgement, skill and art. Spasm/dyssynergia of urethral sphincters (EUS or Bladder neck) may hinder movement of urethral catheter in spinal cord injury patients. Even if catheter is placed successfully, sudden bladder spasms may push the catheter out before balloon is inflated. Presence of false passages can further complicate the situation. In this kind of scenario an inexperienced health professional may not anticipate the problem and inflate the balloon. This leads to inflation of Foleys catheter balloon in urethra as happened in this patient and subsequent trail of procedures to rectify the anomaly. If excessive length of catheter lies outside of penis, this indicates that “Long catheter sign” is positive and denotes incorrect placement of Foleys catheter.⁶ An astute physician will identify this clinical sign but this may remain elusive to staff nurses, interns and junior residents working in medical, surgical

and orthopedic emergencies of tertiary care centers and more so to community health professionals. This case is an eye opener and clearly gives a strong message that senior health care professionals should perform urethral catheterization in spinal cord injury patients in order to minimize the risks of catheter related complications, which may be life threatening as in this case. Nurses, interns and junior residents may not have gained sufficient expertise to carry out catheterization in spinal cord trauma patients.

Kashefi and associates from university of California-San Diego School of Medicine observed that iatrogenic urethral injuries were a substantial source of preventable morbidity in hospitalized male patients. These researchers designed and implemented a nursing education programme that included basic urological anatomy, urethral catheter insertion techniques and catheter safety.⁷ Introduction of such kind of education programmes in emergency wards may significantly decrease the incidence of iatrogenic urethral injury and thus improve patient safety.

Index case 4

A 62 years old male, a case of PIVD (L4-5) with diabetes mellitus who had developed weakness of both lower limbs and retention urine after a fall from height and was being managed in orthopedic department, was brought in urology OPD with a complaint of swelling of penis after change of per urethral catheter by community health professional few days back. On examination patient was on wheelchair, power in lower limbs was grade IV, febrile, penis was edematous, deformed with whitish look and there was ulceration over base of penis and anterior scrotum. Foleys catheter was in situ. Diagnosed as a case of uncontrolled diabetes mellitus with PIVD with catheter induced penile abscess (Figure 6). Patient was placed on i.v antibiotics, analgesics, antacids and regular insulin with serial monitoring of blood sugars. SPC along with incision and drainage of penile abscess done followed by subsequent debridement sessions. Patient responded, well, improved neurologically and shifted to plastic surgery department for grafting (Figure 7).

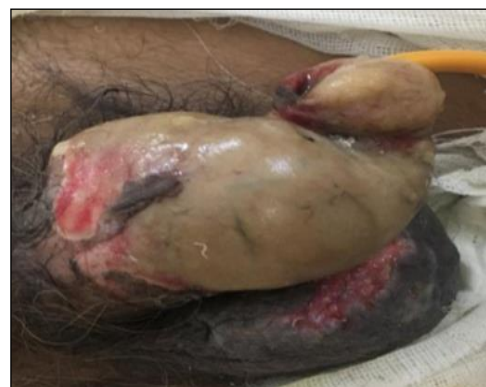

Figure 6: Catheter induced penile abscess.

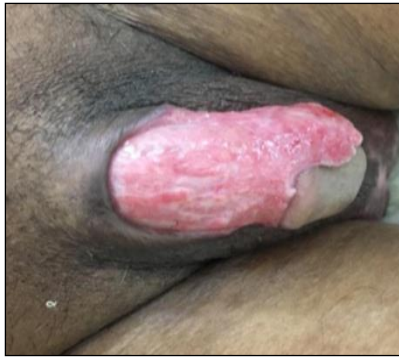

Figure 7: Debrided penis.

Remarks

Infection/cellulitis/abscess of penis and scrotal superficial tissues after per urethral catheter insertion is a preventable complication. This patient was elderly, diabetic from poor socioeconomic status and was having phimosis. During catheter insertion when prepuce was retracted, fissures appeared over the prepuce and there was slight bleeding. As he was uncontrolled diabetic, neither proper aseptic technique was followed during catheter insertion nor patient was placed on antibiotic after the procedure by community health care professional.

Patient developed swelling of the penis which was detected after five days as there was no pain due to diabetic neuropathy or neurological deficit. In patient only superficial penile tissues were involved as compared to Niedrach and associates study in which Penile abscess involved the corpus cavernosum: a case report.⁸ It is pertinent to mention in this case that Foleys per urethral catheter should be placed with proper aseptic precautions with “No Touch” technique and under proper antibiotic coverage especially when patients are diabetics and have developed minor injuries during the procedure.

RESULTS

A total of 82 patients were studied. Age ranged from 19-84 yrs. Distribution of patients according to gender and various neurological lesions is shown in Table 1. Eleven female patients and twenty-eight male patients had normal PUC placement. Eight male patients were on external catheter drainage, ten patients on SPC; nine male and one female and fourteen patients did not require any catheterization; eleven male and four females. Two of Transverse myelitis patient and four of cervical spine fracture patients had iatrogenic hypospadias. Two patients, one of cervical spine fracture and another of thoracic spine fracture had traumatic urethral catheterization and two patients, one operated case of PIVD and another of CVA with diabetes mellitus had penile abscess. Overall neurological lesions are more common in males as compared to females and distributed over an age range of 19-84 years in both sexes (Table 1). Out of total 59.75% of patients required PUC. The prevalence of PUC associated complications is 20.40%. All these are males (100%). Six patients (12.24%) had iatrogenic hypospadias. Two patients (4.08%) had traumatic urethral catheterization and two patients (4.08%) had penile abscess (Figure 8).

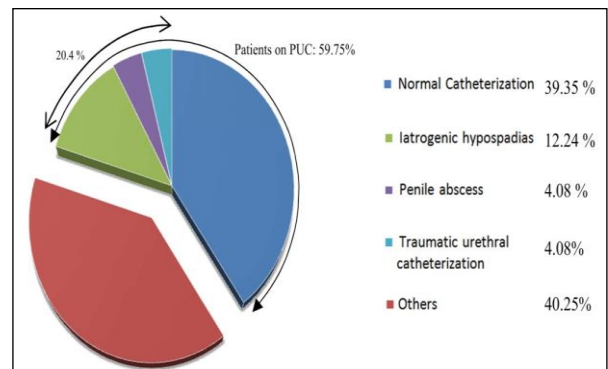


Figure 8: Complication percentage.

Table 1: Distribution of neurological lesions in patients.

Gender	Transverse-myelitis	Cervical spine Fracture	Thoracic spine Fracture	PIVD	Multiple sclerosis	CVA	Parkinsonism	Total
Male	5	12	7	8	2	24	8	66(80.48%)
Female	3	3	-	1	4	4	1	16(19.51%)

DISCUSSION

Long-term indwelling urinary catheterization is done in patients who have spinal cord injury, neurological or musculoskeletal disorder impairing walking movements or bladder control of person and in elderly with urinary retention who are unfit for surgery. It is a widespread

practice in medical field and its well-recognized complications are (1) Urinary tract infection including urethritis, cystitis, pyelonephritis, epididymoorchitis, periurethral abscess, and transient bacteremia (2) paraphimosis (3) catheter blockage due to concretion deposition. (4) cellular toxicity from catheter and urethral stricture (5) bladder spasms and mechanical-bladder perforation (6) urinary bladder malignancy

associated with catheter. The uncommon complications of prolonged Foley's catheterization include aberrant Foley's catheter placement, urethral diverticula, ischemic necrosis of penis, pseudoaneurysm of bulbar artery, catheter-associated penile fracture and iatrogenic hypospadias.⁹ Iatrogenic hypospadias is a rare clinical condition. There is limited data available about the incidence of catheter-induced iatrogenic hypospadias. Prolonged indwelling urethral catheter produces downward pressure which may be due to larger size of Foley's catheter, traction due to weight of the urine in urobag which is transmitted to the catheter and Foleys ballonor improper technique of securing catheter, which interferes with blood supply of urethra causing ischemic effects. Small caliber catheters are preferred as they do not put pressure on urethral mucosa or glands. In this case, it was not properly secured with abdomen. The time interval between urethral catheterization and detection of hypospadias in patients was 2 and 4 months as reported literature shows that hypospadias can develop anytime between 1 month and 16 years after urethral catheterization. Andrew and associates reported similar injury on 16 neurologically ill patients.¹⁰ Due to longer length of urethra these complications are more common in males as corroborated in this study.

Of all the above quoted neurological afflictions, Transverse myelitis requires elaborate overview as it has variable outcomes. Myelitis is a neurological disorder of the spinal cord, caused by inflammation which often damages the myelin sheath and interrupts the messages that the spinal cord nerves send throughout the body.¹¹ Signs and symptoms of transverse myelitis usually develop over a few hours to a few days and may sometimes progress gradually over several weeks. It usually affects both sides of the body below the affected area of the spinal cord, but sometimes there are symptoms on just one side of the body. This can cause pain, muscle weakness, paralysis, sensory problems or bladder and bowel dysfunction like urinary frequency, urgency, incontinence, difficulty or inability to void, incomplete evacuation or bowel constipation.¹² It affects individuals of all ages with some studies reporting peaks in second and fourth decade of life.¹³ Several factors can cause it like Bacterial infections eg. Lyme disease, Syphilis; Viral infections eg. Measles, immune system disorders, multiple sclerosis, spinal injuries, spinal malformations or vascular diseases like atherosclerosis or idiopathic, all of which can reduce the amount of oxygen in spinal cord tissue.¹⁴ If parts of the spinal cord don't have enough oxygen, nerve cells often begin to die. The dyeing tissue can cause the inflammation that leads to transverse myelitis. Blood tests, lumbar puncture, CT, MRI scan of spine or rarely myelography are the tools to diagnosis.¹⁵

Urinary symptoms in transverse myelitis

With the onset of acute Transverse Myelitis, the patient's bladder has little or no sensation and fills with urine. If

the bladder is allowed to distend, urine will dribble continuously, leading to retention with overflow incontinence. Some form of catheterization program, either indwelling (Foley) or intermittent, is started to prevent the bladder muscle over-stretching. Subsequently patients will become aware of bladder filling and able to urinate although emptying may not initially be complete. With regard to symptoms, the patients may complain of increased frequency, urgency, urge incontinence, or there could be complaints of incomplete evacuation of bladder or straining to void.¹⁶ This incomplete emptying of the bladder is due to a combination of a reduced contraction and dyssynergia of the urethral sphincter muscle. Over several weeks or months further recovery of function may occur as the spinal cord recovers. Bladder dysfunction could be one of the most disabling sequelae and shows variable recovery even in cases with complete neurological recovery.¹⁷

Evaluation of urinary tract symptoms

Base line kidney function is assessed with a serum creatinine, urine analysis, urine culture and USG KUB. Those who make a fast recovery need no further evaluation. Further kidney evaluation with intravenous pyelography, computed tomography and renal isotope scan may be recommended if there is any evidence on ultrasound of upper tract changes such as stones, dilatation, or prior abnormality due to congenital or acquired disease. Lower urinary tract evaluation is also deferred in those patients making quick recovery otherwise bladder management in these patients should be based on UDS findings as bladder characteristics have no definitive pattern consistent with the neurological status.¹⁸ It should be performed as baseline following passage of spinal shock and return of spinal reflexes to classify bladder type and to guide decision making regarding the method of bladder management. Subsequently annual, biannual or periodic UDS are performed depending upon the change in symptoms and the risk of upper tract deterioration which can be picked up on Ultrasound as it does not expose patients to radiation.

Treatment

Early treatment in the acute phase usually consists of steroids, immunoglobulins, plasmapheresis continuous bladder drainage with an indwelling Foley catheter and supportive care.^{19,20} When the fluid dynamics are stabilized, intermittent catheterization is begun by the nursing staff. Subsequently patients learn SCIC depending on their age, hand dexterity and motivation. In men there are few physical impediments to self-catheterization as majority have thoracic or lumbar lesions. In women even with thoracic and lumbar lesions, the spasticity of the lower limbs and the need for them to lie down to catheterize, may limit their ability to continue with this program after discharge from hospital. It is pertinent for patients to empty their bladders on time so

that the muscle is not over stretched. In an average adult 500 ml should be the maximum volume retained in the bladder.²¹

In the first few weeks, depending on the degree of spinal cord recovery, the bladder sensation and the ability to void may return. Good prognostic factors are the ability to walk before twenty days from the start of the illness and a history of retention only rather than retention with overflow incontinence. The later probably leads to over stretching of detrusor thus delaying recovery. Early catheterization at the onset of the acute illness holds merit. Transverse myelitis affects everyone differently, and the recovery process will vary for each individual. Recovery from transverse myelitis usually begins within a few weeks of the onset of symptoms and can continue for up to two years, or sometimes longer. People usually make the best recovery between three and six months after the onset of symptoms. Even if recovery is slow, it is still important to persevere with physiotherapy and rehabilitation. Approximately a third of people with transverse myelitis can expect to make a good or full recovery with very limited or no long-term effects.^{16,19} It is very difficult to predict what sort of recovery an individual will make.

Recovery of bladder control and emptying in Transverse Myelitis parallels the recovery of function in the lower limbs. Early and complete recovery leads to complete return of bladder and sphincter functions. Almost 20 percent of patients have some residual lower urinary tract symptoms along with some impairment in the lower limb function, but it is difficult to determine from the literature. Ganesan and Borzyskowski observed an insignificant correlation between motor recovery and urinary symptoms in patients with myelitis.²² However, in another study by Leroy-Malherbe et al, with pediatric transverse myelitis patients, authors observed a positive correlation between early motor recovery and improvement in bladder symptoms.²³ The symptoms and the lower urinary tract manifestations may change with age. Long-term surveillance is therefore recommended in patients with residual bladder symptoms following Transverse Myelitis.

Severe ventral erosion of glans penis and urethra, improper placement of Foleys catheter in urethra and penile abscess caused by indwelling PUC are avoidable complications. They occur in surgical, medical and orthopedic emergency wards but also are commonly done by community health professionals. Therefore, authors planned to create a avoidable complication list in patients with neurological afflictions, especially recoverable. To begin with following three avoidable complications related to management of neuropathic bladder may be included in this list of avoidable complications.

- Severe ventral erosion of glans penis and urethra caused by indwelling urethral catheter.

- Improper placement of Foleys catheter in urethra leading to inflation of ballon in urethra.
- Putting Foleys catheter not under strict aseptic precautions and antibiotic coverage leading to penile abscess.

After the emergency nurses/interns/junior residents/physicians have become familiar with the concept of avoidable complications and what to do when an episode occurs, this list should be expanded to include other adverse clinical incidents such as drug reactions and improper administration of drug dosages etc. authors believe that the physicians should observe the following protocol if avoidable complications occurs in patients with both recoverable and non-recoverable neurological afflictions.

- There should be a hospital risk management system and incident should be reported immediately.
- Communicate with the patient or family member as soon as possible about the incidence in line with hospital policy.
- Try to analyse the cause-where was the lapse.
- What initial action to be taken with the staff involved in the incident, which will ensure pragmatic approach?
- Implement the changes that have been agreed upon after the cause analysis.
- Training programme regarding PUC placement and prevention of complications can be considered for the health care professionals in emergency departments and in the community if feasible.
- Publish the number and type of complications.

By applying these principles and addressing the related clinical problems encountered in medical, surgical and orthopedic emergency departments, it is likely to improve patient safety and care by increasing awareness among health professionals who will be encouraged to identify and implement appropriate measures promptly in order to stop these complications from happening in emergency departments and in community at the first place. By and large it is of utmost importance to altogether avoid these complications in all patients with neuropathic bladders and especially with recoverable neurological afflictions as it drastically reduces the hospitalization and costs involved in secondary procedures, days laid off work, mental stress and un-necessary follow ups. Steps have already been taken to decrease the risks of SPC insertion.²⁴

CONCLUSION

Nevertheless, PUC insertion is a simple procedure but a simple error of omission on the part of health professionals' results in a serious complication in a neurological patient. Soit must be done only when unquestionably necessary. External male catheters, SPC or SCIC may be considered in cases of prolonged catheterization. Proper insertional technique has to be

followed such as choosing appropriate catheter size, aseptic precautions, adequate lubrication, complete insertion of catheter along with aspiration of urine before balloon inflation, instillation of proper amount of sterile fluid and securing the tubing to abdomen or thigh without tension on catheter to prevent avoidable complications.

Funding: No funding sources

Conflict of interest: None declared

Ethical approval: The study was approved by the Institutional Ethics Committee

REFERENCES

- British National Formulary. Wound care accessories. Surgical adhesive tapes: 2017. Available at: <http://www.nice.org.uk/mpc/BritishNationalFormulary.jsp>. Accessed 28 December 2019.
- Drinka PJ. Complications of chronic indwelling urinary catheters. *J Am Med Assoc*. 2006 Jul 1;297(6):388-92.
- Stoffel JT, McGuire EJ. Outcome of urethral closure in patients with neurologic impairment and complete urethral destruction. *Neurourology and Urodynamics: Official J Inter Contin Soci.* 2006 Jan;25(1):19-22.
- Casey JT, Erickson BA, Navai N, Zhao LC, Meeks JJ, Gonzalez CM. Urethral reconstruction in patients with neurogenic bladder dysfunction. *J Urol.* 2008;180(1):197-200.
- Secrest CL, Madjar S, Sharma AK, Covington-Nichols C. Urethral reconstruction in spinal cord injury patients. *J Urol.* 2003 Oct 1;170(4):1217-21.
- Vaidyanathan S, Hughes PL, Oo T, Soni BM. Long catheter sign: a reliable bedside sign of incorrect positioning of foley catheter in male spinal cord injury patients. *Cases J.* 2008 Dec 1;1(1):43.
- Kashefi C, Messer K, Barden R, Sexton C, Parsons JK. Incidence and prevention of iatrogenic urethral injuries. *J Urol.* 2008 Jun 1;179(6):2254-8.
- Niedrach WL, Lerner RM, Linke CA. Penile abscess involving the corpus cavernosum: a case report. *J Urol.* 1989 Feb 1;141(2):374-5.
- Garg G, Baghele V, Chawla N, Gogia A, Kakar A. Unusual complication of prolonged indwelling urinary catheter-iatrogenic hypospadias. *J Family Med Prim Care.* 2016 Apr;5(2):493.
- Andrews HO, Nauth-Misir R, Shah PJ. Iatrogenic hypospadias-A preventable injury?. *Spinal Cord.* 1998 Mar;36(3):177-80.
- West TW. Transverse myelitis-a review of the presentation, diagnosis, and initial management. *Discov Med.* 2013 Sep 29;16(88):167-77.
- Sakakibara R, Hattori T, Yasuda K, Yamanishi T. Micturition disturbance in acute transverse myelitis. *Spinal Cord.* 1996 Aug;34(8):481-5.
- Jeffery DR, Mandler RN, Davis LE. Transverse myelitis: retrospective analysis of 33 cases, with differentiation of cases associated with multiple sclerosis and parainfectious events. *Archiv Neurol.* 1993 May 1;50(5):532-5.
- Berman M, Feldman S, Alter M, Zilber N, Kahana E. Acute transverse myelitis: incidence and etiologic considerations. *Neurology.* 1981 Aug 1;31(8):966.
- Misra UK, Kalita J, Kumar S. A clinical, MRI and neurophysiological study of acute transverse myelitis. *J Neurol Sci.* 1996 Jun 1;138(1-2):150-6.
- Nakipoglu GF, Ozgirgin N. Urodynamic evaluation and rehabilitation outcomes in transverse myelitis. *Neurosci.* 2009;14:37-40.
- Berger Y, Blaivas JG, Oliver L. Urinary dysfunction in transverse myelitis. *J Urol.* 1990 Jul;144(1):103-5.
- Gupta A, Kumar SN, Taly AB. Urodynamic profile in acute transverse myelitis patients: Its correlation with neurological outcome. *J Neurosci Rural Pract.* 2017 Jan;8(01):044-8.
- Debette S, Sèze DJ, Pruvo JP, Zephir H, Pasquier F, Leys D, et al. Long-term outcome of acute and subacute myelopathies. *J Neurol.* 2009;256:980-8.
- Gupta A, Taly AB, Srivastava A, Murali T. Non-traumatic spinal cord lesions: epidemiology, complications, neurological and functional outcome of rehabilitation. *Spinal Cord.* 2009 Apr;47(4):307-11.
- Choi S, Awad I. Maintaining micturition in the perioperative period: strategies to avoid urinary retention. *Curr Opin Anesthesiol.* 2013 Jun 1;26(3):361-7.
- Ganesan V, Borzyskowski M. Characteristics and course of urinary tract dysfunction after acute transverse myelitis in childhood. *Develop Med Child Neurol.* 2001 Jul;43(7):473-5.
- Leroy-Malherbe V, Sebire G, Hollenberg H, Tardieu M, Landrieu P. Sphincteric disorders of acute transverse myelopathy in children. Diagnostic, prognostic, rehabilitative aspects. *Archiv Pediatr.* 1998 May 1; 5(5):497-502.
- National Patient Safety Agency Rapid Response Report. Minimising risks of suprapubic catheter insertion. NSPA/2009/RRR005. Available at http://www.npsa.nhs.uk/patient_safety/alerts_and_directions. Accessed on 20 December 2019.

Cite this article as: Sandhu HS, Singh H, Sharma A. Catheter induced hypospadias, urethral trauma and penile abscess in completely recoverable neurological afflictions: preventable entities. *Int J Res Med Sci* 2020;8:847-54.