

## Case Report

# An unusual association of pyoderma gangrenosum with ulcerative colitis and thyrotoxicosis successfully treated with infliximab: a case report

Abdullah Abualiat\*, Hala Edris, Salaheldin Alfadni, Tariq Aziz, Mahmoud Hussein

Department of Dermatology, Armed Forces Hospital, Southern Region, Kingdom of Saudi Arabia

**Received:** 15 February 2020

**Revised:** 23 February 2020

**Accepted:** 07 March 2020

**\*Correspondence:**

Dr. Abdullah Abualiat,

E-mail: [sabualiat@gmail.com](mailto:sabualiat@gmail.com)

**Copyright:** © the author(s), publisher and licensee Medip Academy. This is an open-access article distributed under the terms of the Creative Commons Attribution Non-Commercial License, which permits unrestricted non-commercial use, distribution, and reproduction in any medium, provided the original work is properly cited.

### ABSTRACT

Pyoderma Gangrenosum (PG) is a rare chronic immune-mediated inflammatory dermatosis manifested as painful skin ulceration, commonly affecting the lower limbs. The pathogenesis of the disease is complex. Abnormalities in neutrophil function, dysregulation of the innate immune system, and Tumor Necrosis Factor (TNF) were postulated. An underlying associated systemic disease was reported in more than 50% of PG patients, including inflammatory bowel disease, rheumatoid arthritis, and malignancies, with few cases reported an associated thyroid disease. Authors report a case of extensive PG associated with both ulcerative colitis and thyrotoxicosis co-morbidities not mentioned before in one patient. The patient was successfully treated with the anti-TNF alpha infliximab.

**Keywords:** Infliximab, Inflammatory bowel disease, Pyoderma gangrenosum, Thyrotoxicosis

### INTRODUCTION

Pyoderma Gangrenosum (PG) is an uncommon immune-mediated inflammatory condition that belongs to a group of neutrophilic dermatoses. The lesions usually start as painful, hemorrhagic pustules, red papules, plaques, or nodules that rapidly increase in size and form ulcerations with undetermined purple-colored borders commonly on the lower extremities.<sup>1</sup>

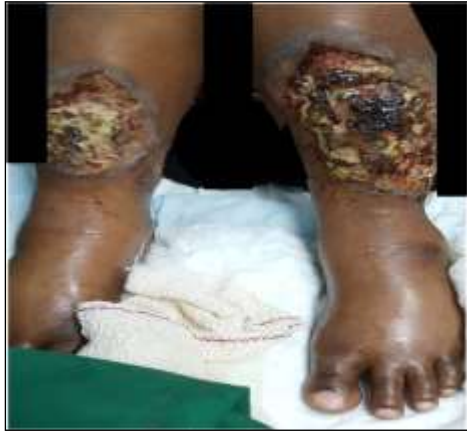More than 50% of PG patients have an associated underlying systemic disease. It occurs approximately in 1-2% of patients with Inflammatory Bowel Disease (IBD). Conversely, 36-50% of patients with PG have IBD.<sup>2</sup> Hematologic disorders and arthritis were frequent PG co-morbidities, with few cases reported an associated thyroid disease.<sup>3,4</sup> The morbidity and mortality of PG are directly related to the associated co-morbidities, mode of treatment, and follow-up. Systemic medication is

indicated for most of the patients suffering from PG. Nevertheless, systemic corticosteroids remain the principal therapy for induction of remission followed by maintenance with immunosuppressive medication such as cyclosporine A or methotrexate. More recently, infliximab, anti-TNF-alpha antagonists have been introduced as second-line therapy in resistant or recalcitrant PG.

### CASE REPORT

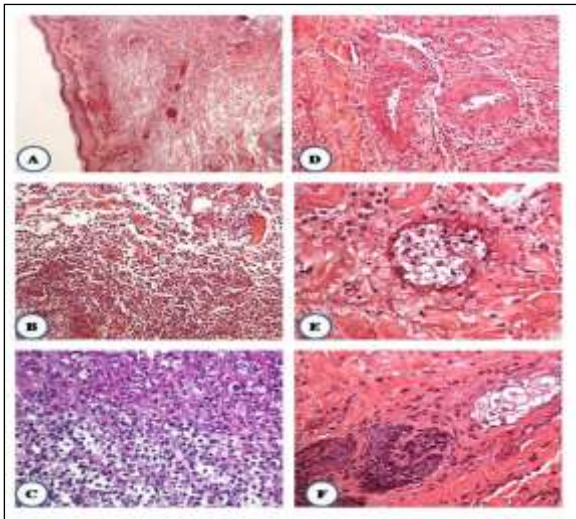
A 29-year-old lady presented to the ER with high-grade fever and bilateral extensive painful ulcerations over both legs and knees for three months. She is a known case of ulcerative colitis for 12 years and thyrotoxicosis for 2 years, not on regular medication or follow-up. The ulcers started as small painful lesions on both shins for which the patient underwent surgical debridement two months before the presentation. Following that, the lesions rapidly increased in size and became ulcerated. On

examination, there were bilateral, symmetrical necrotic ulcers on the anterior aspect of the legs measuring 15 cm x10 cm in diameter, with undermined violaceous borders, covered with hemorrhagic crust and sloughing with bilateral lower limb edema (Figure 1).



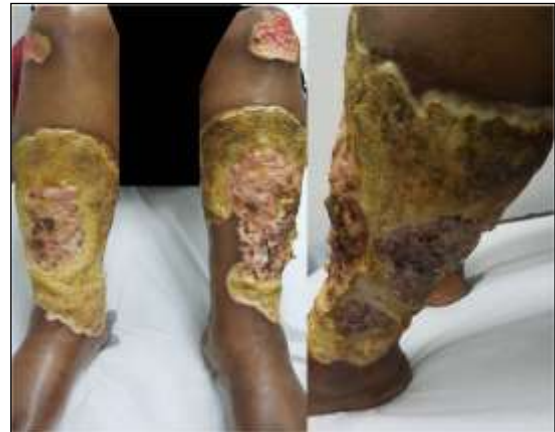**Figure 1: The PG case picture at presentation showing bilateral, symmetrical necrotic ulcers on the anterior aspect of both legs.**

Her initial lab results revealed high total WBCs, low hemoglobin, high C reactive protein, and very low TSH. Renal and liver profiles were normal. Clinical diagnosis of PG was established and confirmed by histopathological workout showing epidermal and dermal necrosis and abscess formation with diffuse pandermal neutrophilic infiltrate extending around the adnexal structures (Figure 2).



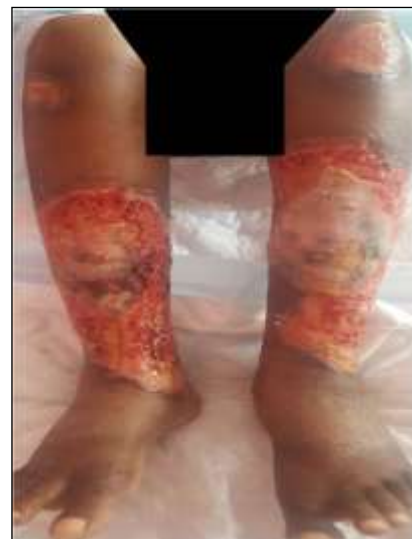**Figure 2: Histological features of pyoderma gangrenosum. The histologic sections show: (A, B and C) epidermal and dermal necrosis and abscess formation, (D): secondary vasculitis, and (E-F): diffuse pandermal neutrophilic infiltrate extending around the adnexal structures (sebaceous gland and peri-infundibular necrosis with dense neutrophilic infiltrate).**

Multidisciplinary team management was initiated by dermatology, wound care, plastic surgery, endocrinology, and gastroenterology. Antipyretic, IV antibiotics, and wound dressing were immediately started. Then pulse therapy of corticosteroid for five days followed by oral prednisolone and cyclosporine-A were given for six weeks but did not show any improvement. Conversely, the lesions increased in size, got infected, and became more extensive (Figure 3).



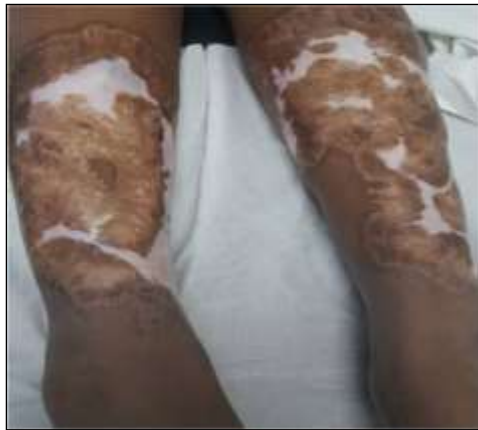**Figure 3: The PG case picture after 6 weeks of prednisolone and cyclosporine A therapy. The lesions increased in size, got infected, and became more extensive.**

Therefore, the patient was shifted to IV infliximab 5 mg/kg in week 0, 2, 6, and then every 8 weeks together with prednisolone 0.5 mg/kg and regular wound dressing. After two months of treatment, the ulcers over both knees almost healed with a marked bilateral improvement of the leg ulcers (Figure 4).



**Figure 4: The PG case picture after 2 months of infliximab therapy. The ulcers over both knees almost healed with a marked bilateral improvement of the leg ulcers.**

The patient continued on infliximab for one year, during which the leg ulcers completely healed with residual pigmentation (Figure 5).



**Figure 5: The PG case picture after one-year treatment with infliximab. The leg ulcers completely healed with residual pigmentation.**

## DISCUSSION

The presented case exhibited the typical progression of PG lesions, which starts as painful, hemorrhagic pustules, red papules, plaques, or nodules that rapidly increase in size and generate ulcerations with undetermined purple-colored borders commonly on the lower extremities.<sup>1</sup> Reported case exhibited a pathergy phenomenon (induction or exacerbation of PG at the sites of trauma) that is observed in about 30% of PG patients.<sup>5</sup>

The pathogenesis of the disease is complex and not fully explained. Occult bacterial infection, circulating autoantibodies, and the Shwartzman reaction (a local immune response to bacterial endotoxin resulting in tissue necrosis) were previously postulated to contribute to the pathogenesis of PG.<sup>6</sup> However, subsequent studies found little support for these theories and recent evidence regarding abnormalities in neutrophil function, genetic variations, and dysregulation of the innate immune system became the primary factors considered to contribute to the pathogenesis of PG which helped in a better understanding of the disease and hence determining new therapeutic targets.<sup>7</sup> Evidence supports the relevance of leucocytic cytokines such as Interleukin (IL)-8 and IL-23 to the pathogenesis of the disease.<sup>8</sup> Nevertheless, the important role of Tumor Necrosis Factor (TNF)-alpha in the pathogenesis of PG was supported by the good response of the disease to infliximab and other anti-TNF-alpha agents.<sup>9</sup> Most experience has been obtained in patients with chronic inflammatory bowel disease associated with PG.<sup>10</sup>

The diagnosis of PG is challenging as the clinical, histopathologic, and laboratory findings are nonspecific, and a diagnosis of PG can only be made through the exclusion of other causes of non-healing ulcers. In

patients known to have diseases associated with PG, the development of an ulcer should raise suspicion for this diagnosis. This case was diagnosed depending on the clinical picture, the association with ulcerative colitis and thyrotoxicosis, and the histopathological findings.

Many case reports have documented the dual association between PG and inflammatory bowel disease or PG with thyrotoxicosis.<sup>4</sup> However, to the best of our knowledge, this case report is the first one associating PG with both ulcerative colitis and thyrotoxicosis.

In general, PG patients are managed with a combination of topical and/or systemic therapies that suppress the inflammatory process and wound care measures that optimize the environment for wound healing. For more extensive disease, systemic treatment is used as a first-line intervention in PG.

The systemic therapies utilized in PG are immunosuppressive and immunomodulatory agents that calm the inflammatory process to allow for wound healing. Systemic glucocorticoids often induce a rapid response and are typically used as initial therapy.<sup>11</sup> In patients who cannot tolerate or fail to respond to systemic glucocorticoids, treatment with systemic cyclosporine can be attempted. This case showed no response to both glucocorticoids and immunosuppressive agents. Therefore, authors shifted to infliximab, a recently introduced chimeric antibody against TNF-alpha whose efficacy in the treatment of refractory or resistant PG with IBD is supported by many randomized-controlled trials as well as other studies.<sup>10</sup> This case showed a dramatic response to infliximab in the form of complete wound healing, which started after one month and the improvement of patient quality of life. Potential adverse effects of infliximab include infusion reactions, infections, demyelinating disease, and heart failure, which were fortunately not reported in this case.<sup>12</sup>

## CONCLUSION

The reported case highlights the rare presentation of extensive pyoderma gangrenosum in association with both thyrotoxicosis, ulcerative colitis with a successful response to the newer targeted anti-TNF therapies in combination with systemic corticosteroids.

*Funding: No funding sources*

*Conflict of interest: None declared*

*Ethical approval: Not required*

## REFERENCES

1. Wollina U. Clinical management of pyoderma gangrenosum. *Am J Clin Dermatol.* 2002 Apr 1;3(3):149-58.
2. Regueiro M, Valentine J, Plevy S, Fleisher MR, Lichtenstein GR. Infliximab for treatment of pyoderma gangrenosum associated with

- inflammatory bowel disease. *Am J Gastroenterol.* 2003 Aug 1;98(8):1821-6.
3. Langan SM, Groves RW, Card TR, Gulliford MC. Incidence, mortality, and disease associations of pyoderma gangrenosum in the United Kingdom: a retrospective cohort study. *J Invest Dermatol.* 2012 Sep 1;132(9):2166-70.
  4. Binus AM, Qureshi AA, Li VW, Winterfield LS. Pyoderma gangrenosum: a retrospective review of patient characteristics, comorbidities and therapy in 103 patients. *Bri J Dermatol.* 2011 Dec;165(6):1244-50.
  5. Schoemann MB, Zenn MR. Pyoderma gangrenosum following free transverse rectus abdominis myocutaneous breast reconstruction: a case report. *Annal Plastic Surg.* 2010 Feb 1;64(2):151-4.
  6. Ahronowitz I, Harp J, Shinkai K. Etiology and management of pyoderma gangrenosum. *Am J Clin Dermatol.* 2012 Jun 1;13(3):191-211.
  7. Wollina U, Tchernev G. Pyoderma gangrenosum: pathogenetic oriented treatment approaches. *Wiener medizinische Wochenschrift.* 2014 Jul 1;164(13-14):263-73.
  8. Gurung P, Kanneganti TD. Autoinflammatory skin disorders: the inflammasome in focus. *Trends Mole Med.* 2016 Jul 1;22(7):545-64.
  9. Brooklyn TN, Dunnill MG, Shetty A, Bowden JJ, Williams JD, Griffiths CE, et al. Infliximab for the treatment of pyoderma gangrenosum: a randomised, double blind, placebo-controlled trial. *Gut.* 2006 Apr 1;55(4):505-9.
  10. Peyrin-Biroulet L, Van Assche G, Gómez-Ulloa D, García-Álvarez L, Lara N, Black CM, et al. Systematic review of tumor necrosis factor antagonists in extraintestinal manifestations in inflammatory bowel disease. *Clin Gastroenterol Hepatol.* 2017 Jan 1;15(1):25-36.
  11. Reichrath J, Bens G, Bonowitz A, Tilgen W. Treatment recommendations for pyoderma gangrenosum: an evidence-based review of the literature based on more than 350 patients. *J Am Academy Dermatol.* 2005 Aug 1;53(2):273-83.
  12. Kaur N, Mahl TC. Pneumocystis jirovecii (carinii) pneumonia after infliximab therapy: a review of 84 cases. *Dige Dis Sci.* 2007 Jun 1;52(6):1481-4.

**Cite this article as:** Abualiat A, Edris H, Alfadni S, Aziz T, Hussein M. An unusual association of pyoderma gangrenosum with ulcerative colitis and thyrotoxicosis successfully treated with infliximab: a case report. *Int J Res Med Sci* 2020;8:1585-8.