

Original Research Article

Anterior epitympanic attic antrum space obstruction and symptom onset associated with myringosclerosis in benign chronic suppurative otitis media

Zulfikar Naftali^{1*}, Suprihati¹, Dharmana E.², Setyawan H.³

¹Department of Otolaryngology, ²Department of Parasitology, Faculty of Medicine, Diponegoro University, Semarang Indonesia

³Department of Public Health, Faculty of Public Health, Diponegoro University, Semarang, Indonesia

Received: 20 March 2020

Accepted: 22 April 2020

*Correspondence:

Dr. Zulfikar Naftali,

E-mail: zulfikarnaftali@yahoo.co.id

Copyright: © the author(s), publisher and licensee Medip Academy. This is an open-access article distributed under the terms of the Creative Commons Attribution Non-Commercial License, which permits unrestricted non-commercial use, distribution, and reproduction in any medium, provided the original work is properly cited.

ABSTRACT

Background: The AAA (Anterior epitympanic, Attic, and Antrum) space is the space between the mastoid and middle ear which functions to balance the pressure in both organs (buffer). Pathological tissue in the AAA cavity due to chronic infection would disrupt the buffer function and could change the morphology of the mucosa in the tympanic membrane and middle ear. Obstruction in the AAA space measured subjectively by observing the smoothness of the flow using saline solution has been shown to be associated with a plaque in the tympanic membrane (myringosclerosis) in Chronic Otitis Media (COM) patients. This study aims to determine the relationship between AAA space obstructions with myringosclerosis using CT-Scan for an objective result.

Methods: Retrospective study with case-control approach used in this study. Case criteria are Chronic Suppurative Otitis Media (CSOM) patients with myringosclerosis, both men and women and age 15-50 years, while the control group are benign CSOM patients without myringosclerosis. Data were analyzed with the chi-square test to prove the association between the AAA space status and length of symptom onset with myringosclerosis.

Results: During January 2017-December 2019 there were 33 respondents, 19 cases and 14 controls, 21 men and 12 women with an average age of 35 years (cases) and 23.5 years (control). The length of symptom onset more than 5 years ($p < 0.05$, OR 6.94 with CI 0.5-1.5) and AAA space obstruction ($p < 0.05$ OR 34.25 with CI 0.8-1.8) has been shown to be associated with myringosclerosis in people with benign CSOM.

Conclusions: AAA space obstruction and symptom onset more than 5 years significantly associated with myringosclerosis.

Keywords: AAA space obstruction, Benign CSOM, Myringosclerosis, Symptoms onset

INTRODUCTION

The middle ear space or tympanic cavity is the space between the ear canal and the inner ear. The tympanic cavity consists of 3 parts, from superior to inferior as follows: epitympanic, mesotympanic and hypotympanic. The lateral border of the tympanic cavity is the tympanic membrane, separating the tympanic cavity from the outer

ear canal.¹ Infection in the tympanic cavity (acute otitis media, otitis media with effusion, benign and malignant chronic suppurative otitis media) causes deposits of connective tissue, collagen, and hyaline in the submucosal tympanic membrane were called myringosclerosis.² Prognosis of benign chronic suppurative otitis media (CSOM) patients with myringosclerosis become worse because it increases the

degree of hearing loss, increases disease recurrence and decreases the success of tympanoplasty.^{3,4} The pathogenesis of myringosclerosis is unknown certainty. It is suspected that the mastoid antrum obstruction is related to this pathogenesis. Acute infection in the middle ear and mastoid cellule causes exudate deposits in the mastoid cellule, antrum, epitympanic and tympanic cavity.⁵ In the chronic infection, the mucosa in the mastoid and tympanic cavity could become edema and polypoid so narrow the AAA space (anterior epitympanic, attic and antrum), which is between the mastoid and tympanic cavity and even obstruction entirely.⁶ As a result, aeration to the mastoid is blocked and exacerbates the infection. The relationship between the AAA space obstruction and chronic infection is followed by morphological changes in the posterosuperior quadrant tympanic membrane that is anatomically adjacent to the AAA space. Fibrosis tissue in the lamina propria of the tympanic membrane, triggering the process of hyalinization and calcification of the tympanic membrane known as myringosclerosis.⁷ Previous study found an association of mastoid anterior obstruction with myringosclerosis. The antrum space obstruction in that study was assessed by observing the smoothness of the saline solution through the mastoid antrum.⁸ To obtain more objective and measurable results, this study used a CT-Scan mastoid to assess the presence of blockage not only the mastoid antrum but also the anterior epitympanic and attic.

METHODS

Case-control approach used in this study. Every benign CSOM patient who received treatment at the ear clinic at Kariadi Hospital during January 2017 and December 2019 period was likely to be the subject of this study. Calculation of sample size is determined based on the ratio of 2 proportions for dichotomous variables. The value (P1-P2) is set at 0.5 with a value of α 5% and a value of β 20%, so the minimum sample size for each case group and control group is 14.⁹

Case criteria were benign CSOM patients with myringosclerosis, aged 15-50 years, both men and women, while the controls were benign CSOM patients without myringosclerosis. The diagnosis of benign CSOM is based on anamnesis (otore and its duration), physical assessment by 0-degree endoscopic luminaire (perforation in central of tympanic membrane, thick perforation edge) and supporting assessment using CT-Scan 128 slices. Based on the CT-scan, the AAA space status is divided by 2 (obstruction and normal. AAA space status is said to be obstruction if there is gloom based on CT-scan interpretation (Figure 1). The symptom onset is divided into less than or more than 5 years. Patients categorized as myringosclerosis if there is a whitish plaque on the surface of the tympanic membrane. Exclusion criterias both of two groups (case and control) are benign CSOM patients with prior mastoidectomy or tympanoplasty, benign CSOM sufferers with malignancy

and total perforation of the tympanic membrane so that myringosclerosis could not be assessed.

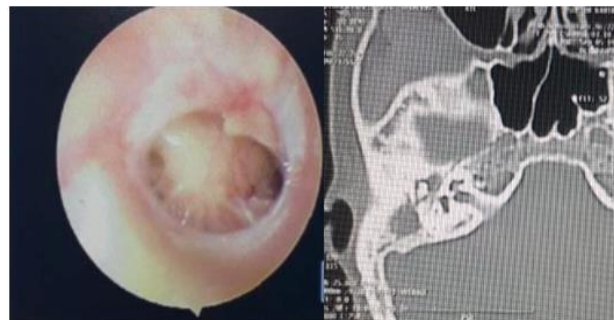


Figure 1: Myringosclerosis and AAA space obstruction.

Statistical tests using SPSS version 23. The relationship between independent variables (AAA space, symptom onset) and dependent variable (myringosclerosis) is assessed by Chi square test. If the chi-square requirements are not met, Fisher's test is used. The association stated significant if p-value <0.05 and the power of association sing Odd Ratio (OR) and Confident Interval (CI). The study was approved by the Ethics Commission of the Faculty of Medicine, Diponegoro University, Semarang, Indonesia.

RESULTS

There were 33 subjects divided into 19 cases and 14 controls. As many as 21 men and 12 women followed this study. There were 12 people in the case group with AAA space obstruction, while in the control group were 10 subjects. Each group is rated for general and specific characteristics. General characteristics include age, sex, location of CSOM and location of perforation. The general characteristics of the case group are as follows: 12(60%) men and 7 (40%) women; average age of 35 years. The location of CSOM in the right ear is 5 people (25%), the left ear is 9 (50%) and both ears are 5 (25%). Location of perforation; anteroinferior 1 (5%), central 5 (25%) and the rest 13 (70%) with subtotal perforation. The general characteristics of the control group are as follows: 9 men (64%) people and 5 women (36%) people; average age of 23.5 years. The location of CSOM in the right ear is 3 people (22%), the left ear is 8 (66%) and in both ears are 3 people (22%). Location of perforation; anteroinferior 1 (7%) and 13 (93%) people with subtotal perforation.

Specific characteristics include the type of mucosa of the middle ear, length od symptom onset and the status of the AAA space (anterior epitympanic, attic and antrum). In the case group, edema in the middle ear are 7 (36%) and normal mucosa are 12 (64%); length of symptom onset averaged 4.7 years and obstruction of AAA space was found in 12 (63%). In the control group, 4 (18%) with edema in the middle ear and the rest 10 people (82%) had normal mucosa, the average of length symptom onset is

4.7 years and there is AAA space obstruction in 10 people (82%) while 4 people (18%) normal condition. In Table 1, statistical tests using chi square showed a significant association between length of symptom onset with myringosclerosis ($p = 0.001$; OR 6.94). Patients with complaints over 5 years, having 6.9 times greater risk of

experiencing myringosclerosis. Anterior epitympanic, attic and antrum (AAA) space obstruction was also significantly associated with myringosclerosis ($p=0.001$: OR 34.25). Benign CSOM patients with obstruction in the AAA space, 34.25 times experience myringosclerosis compared to the normal AAA space.

Table 1: Characteristics of respondents.

Variable	Case	Control	p	CI 95%	OR
Ages (mean, yo).	35	23.5			
Sex	Man	12 (60%)	9 (64%)		
	Women	7 (40%)	5 (36%)		
Perforation site	Central	5 (25%)	0		
	Antero-superior	1 (5%)	1 (7%)		
	Antero-inferior	0	0		
	Sub-total	13 (75%)	13 (93%)		
Tympanic mucosa	Oedema	7 (36.3%)	4 (18%)		
	Normal	12 (63.7%)	10 (82%)		
Symptom onset	More than 5 y	10 (53%)	7 (50%)	0.001 [#]	0.5-1.5
	Less than 5 y	9 (47%)	7 (50%)		6.94
AAA paces status	Obstruction	12 (63.7%)	10 (71.2%)	0.001 [#]	0.8-1.8
	Normal	7 (36.3%)	4 (28.8%)		34.25

*chi-square test

DISCUSSION

Most of benign CSOM patients are men. Previous studies showed that men were less concerned about the initial symptoms of the illness and seek treatment when complaints chronic and interfere quality of life.¹⁰ The average age of patients in this study was 28 years, consistent with previous studies. Although the symptoms of benign CSOM can begin as a child, a low understanding of the patient's family causes delays in seeking treatment.^{11,12}

This study shows an association between symptom onset over 5 years, AAA space obstruction and myringosclerosis. Patients with complaint over 5 years are 6.9 times more likely to experience myringosclerosis than controls. These results are consistent with other studies, in which myringosclerosis was found in patients who have had 6 years of the middle ear infection.¹³ Chronic infections in the mastoid and middle ear are not directly related to tympanosclerosis, but first through changes in mucosal morphology in the AAA space.

The symptom onset more than 5 years changes the morphology of the middle ear mucosa and mastoid into polypoid and edema accompanied by an increase of lymphocyte and leukocyte level.⁶ Obstruction occurs if the mucosa in the AAA space changes to edema or polypoid. In contrast to previous studies which assessed drainage smoothness, this study chose CT-scan over

endoscopy to assess AAA space obstruction because it was more measurable.¹⁴⁻¹⁷ In this study, it was found that patients with AAA space obstruction had a 34 times greater risk of tympanosclerosis compared to controls. The AAA space which is supposed to be the oxygen pathway from the eustachian tube to the mastoid cellule is obstructed in the AAA space and could not function normally. Obstruction would cause hypoxia and related to selective epitympanic dysventilation that associated with pathological tissue in middle ear, including myringosclerosis.¹⁸⁻¹⁹

The limitation of this study is not assessed the grade of AAA space obstruction degree. Results of this study are expected could educate the importance of evacuating pathological tissue in AAA space to improve the successful of tympanoplasty and mastoidectomy.

CONCLUSION

AAA space obstruction and length of symptom onset more than 5 years significantly associated with myringosclerosis.

Funding: No funding sources

Conflict of interest: None declared

Ethical approval: The study was approved by the Institutional Ethics Committee of Medical Faculty Diponegoro University, No.251/EC/KEPK/FK-Undip/VI/2019.

REFERENCES

1. Mansour S, Magnan J, Haidar H, Nicholas K, Louryan S. Middle ear cavity In: C Zini, Saccardi MS, K Nicholas, S Louryan, eds. *Comprehensive and clinical anatomy of middle ear*. Springer Cham, Heidelberg; NewYork: Dordrecht London; 2013: 5-7.
2. Gray S, Lusk RP. Tympanic membrane-tympanostomy tubes. In: Cummings CW, Fredrickson JM, Harker LA, Krause LE, Schuller DE, eds. *Otolaryngology-Head and Neck Surgery*, 2nd ed. St Louis: Mosby Year Book, 1993: 2971-2977.
3. Yurttaş V, Ural A, Kutluhan A, Bozdemir K. Factors that may affect graft success in tympanoplasty with mastoidectomy. *ENT Updates*. 2015 Apr 1;5(1):9-12
4. Badran HS, Tawab HM, Wahba BM, Abulnasr KM. Myringosclerosis with chronic safe suppurative otitis media: hearing outcome after surgical management according to myringosclerotic patch site and inclusion in the surgery. *J Int Adv Otol*. 2014 Oct 1;10(3):260.
5. Pal I, Sengupta A. Clinicopathological and audiological study of tympanosclerosis. *Ind J Otolaryngol Head Neck Surg*. 2005;67(3):235-9.
6. Yetifer S, Hidir Y, Devenci MS. Morphologic changes of middle ear mucosa in chronic otitis media with or without cholesteatoma. *Mediterr J Otol*. 2008;4:102-8.
7. Baghat M. Patency of the Aditus Ad Antrum in Tubotympanic Chronic Suppurative Otitis Media. Available at: <http://www.sagepublications.com>. Accessed 2 January 2020.
8. Manjunath MK, Sworup RJ, Charry G, Shadab MD. Myringosclerosis: An indication of a blocked aditus. *Ind J Otolaryngol Head Neck Surg*. 2012;64(3):230-2.
9. Browner WS, Newman TB, Hulley SB. Estimating sample size and power: application and examples. In: Hulley SB, Cummings SR, Browner WS, Grady DG, Newman TB, eds. *Designing Clinical Research* 2013 4rd Ed. Philadelphia: lippincott Williams & Wilkins; 2013: 55-81.
10. Alabassi AM, Alsaimary IE, Najim JM. Prevalence and patterns of chronic suppurative otitis media and hearing impairment in Basrah city. *J Medi Sci*. 2010;1(4):129-33.
11. De Antonio R, Yarzabal JP, Crus JP, Schmidt JE, Kleijnen J. Epidemiology of otitis media in children from developing countries: A systematic review. *Int J Paediatr Otolaryngol*. 2016;85:65-74.
12. Anggraeni R, Hartanto WW, Djelantik B, Ghanie A, Utama DS, Setiawan EP, et al. Otitis media in Indonesian urban and rural school children. *Pediatr Infect Dis J*. 2014 Oct 1;33(10):1010-5.
13. George MV. The mastoid compartment of middle ear cleft-a clinic pathological study in patients with chronic otitis media-mucosal type. *Exp Rhinol Otolaryngol*. 2018;1(5):85-90.
14. El-Kady AS, Haroun Y, Kaseem KM, Galal O. The value of computed tomography scanning in assessment aditus ad antrum patency and choice of treatment line in revision myringoplasty. *Med J Cairo Univ*. 2009;77(2):53-7.
15. Anbarasu A, Chandrasekaran K, Balakrishnan S. Soft tissue attenuation in middle ear on HRCT: pictorial review. *Ind J Radiol Imag*. 2012;22:298-304.
16. Gorur K, Ozcan C, Talas DU. The computed tomographic and tympanometrical evaluation of mastoid pneumatization and attic blockage in patients with chronic otitis media with effusion. *Int J Pediatr Otorhinolaryngol*. 2006;70:481-5.
17. Marchioni D, Mattioli F, Alicandri-Ciuffelli M, Molteni G, Masoni F, Presutti L. Endoscopic evaluation of middle ear ventilation route blockage. *Am J Otolaryngol Head Neck Surg Medi Surg*. 2010;31:453-66.
18. Shirai K, Schachern PA, Schachern MG, Paparella MM, Cureoglu S. Volume of the epitympanum and blockage of the tympanic isthmus in chronic otitis media: a human temporal bone study. *Otol Neurotol*. 2015;36(2):254-259.
19. Marchioni D, Grammatica A, Alicandri-Ciuffelli M, Aggazzotti-Cavazza E, Genovese E, Pressuti L. The contribution of selective dysventilation to attic middle ear pathology. *Medi Hypoth*. 2011;77:116-120.

Cite this article as: Naftali Z, Suprihati, Dharmana E, Setyawan H. Anterior epitympanic attic antrum space obstruction and symptom onset associated with myringosclerosis in benign chronic suppurative otitis media. *Int J Res Med Sci* 2020;8:2013-6.