

Case Series

Management of idiopathic granulomatous mastitis: a surgical experience of ten cases

Abishek H. Karthik*, Lisha Suraj

Department of General Surgery, MGM Institute of Health Sciences, Navi Mumbai, Maharashtra, India

Received: 09 April 2020

Revised: 20 May 2020

Accepted: 28 May 2020

*Correspondence:

Dr. Abishek H. Karthik,

E-mail: abishek.karthik12@gmail.com

Copyright: © the author(s), publisher and licensee Medip Academy. This is an open-access article distributed under the terms of the Creative Commons Attribution Non-Commercial License, which permits unrestricted non-commercial use, distribution, and reproduction in any medium, provided the original work is properly cited.

ABSTRACT

Granulomatous mastitis is a chronic inflammatory condition of the breast that is rarely described in literature. It mimics breast abscess on clinical presentation giving dilemma to the surgeon. The etiology can be infectious, autoimmune or idiopathic. The various modalities of treatment for idiopathic granulomatous mastitis includes drainage of abscess, antibiotics and corticosteroid therapy. This is a case series of ten cases of diagnosed with granulomatous mastitis treated in the period of 2 years from 2018 and 2019 in Department of General Surgery, MGM Hospital Navi Mumbai. The data of all the patients were collected from records. They were following at regular intervals in the outpatient department to assess recurrence. The mean age of the patients was 41 years (range 26–47 years). Six patients gave history of breast-feeding in the last 5 years, one was lactating at the time of presentation. One of the patients was treated empirically for Tuberculous mastitis for the opposite breast. Others had no history suggestive of tuberculosis or other connective tissue diseases, such as rheumatoid arthritis or sarcoidosis USG breast was performed in all cases. Hypoechoic abscess was seen in 5 cases. The time taken for complete resolution of the disease was ranging from 2 weeks to 2 months. All patients had an uneventful recovery and no recurrences reported till now. GM is a rare benign breast disease that is difficult to distinguish from other inflammatory breast diseases or cancer. The diagnosis of GM must be based on a multidisciplinary approach. Surgical management followed by antibiotics was found to be sufficient to treat the condition in our patients. Corticosteroids need not be administered in all cases of this benign breast disease.

Keywords: Breast abscess, Corticosteroid therapy, Granulomatous mastitis, Inflammatory lump, Incision and drainage, Tuberculous mastitis, Wide local excision

INTRODUCTION

Granulomatous mastitis (GM) is a rare chronic inflammatory breast condition that was first described by Kessler and Wolloch in 1972.¹ Granulomatous changes occur around lobules and ducts of the breast in the absence of specific infection, trauma, or evidence of sarcoidosis.² It most commonly presents in parous women of reproductive age, with a history of breastfeeding in the previous 5-6 years.³ The etiology of granulomatous mastitis can be divided as infectious (most

common being Tuberculosis), autoimmune, duct ectasia, diabetes mellitus, sarcoidosis.⁴

If none could be identified it can be termed as Idiopathic Granulomatous mastitis (IGM). The most common clinical presentation is a firm, unilateral, and discrete breast mass that is often associated with an abscess or inflammation of the overlying skin and fistulae. The treatment usually involves surgical excision of lump and mastectomy followed by antibiotics and corticosteroid therapy.⁵ However, the optimal treatment of patients with

GM is uncertain. It will usually take 1-2 years to resolve on its own if left untreated.⁶

This case series included 10 patients who were diagnosed with granulomatous mastitis within the time period of 2 years from January 2018 and December 2019. All had presented with breast abscess or breast lump (bilateral/unilateral). The diagnosis was also confirmed from histopathology specimen of all the cases. All the patients who were diagnosed with tuberculous mastitis by the GenXpert and TB cultures were excluded. Other patients who were diagnosed with breast malignancy through histopathology of the excised lumps were also excluded. All underwent incision and drainage (single or multiple procedures) or wide excision of lump. All specimen were sent for histopathology. All patients were treated with antibiotics. Regular dressings and secondary suturing was done in all cases. Corticosteroid therapy was not given for any patients. All were followed up at regular intervals following surgery and suturing for

recurrence of abscess or mass. As this was an observational data collection study, with no hypothesis testing, formal calculation of sample size and statistical power was not performed.

CASE SERIES

The mean age of the patients was 41 years (range 26-47 years). All of the patients were premenopausal. Six patients gave history of breast-feeding in the last 5 years, one was lactating at the time of presentation. One of the patients was treated empirically for Tuberculous mastitis for the opposite breast. Others had no history suggestive of tuberculosis or other connective tissue diseases, such as rheumatoid arthritis or sarcoidosis. Table 1 shows the details of the patients regarding the age, parity and other comorbidities. One of the patients were nulliparous and rest were all multiparous parous women. Four of the patients were having comorbidities like Type II diabetes, hypertension or both.

Table 1: Patient details regarding age, parity and other comorbidities.

Case No.	Age(in years)	Parity	Comorbidities
1	36	P1L1, currently breast feeding	Past history of TB breast abscess in the opposite breast, had underwent Incision and drainage and was on AKT for 9 months
2	38	P2L2	None
3	47	P1L1	Known diabetes and hypertension
4	45	P3L2D1	History of previous I&D on both breasts 5 times in past 1 year
5	26	Nulliparous	None
6	42	P2L1A1	Known case of diabetes(controlled) initially left side abscess treated with I&D
7	33	P1L1A1	None
8	42	P2L2	Known case of Hypertension
9	35	P1L1	None
10	43	P1L1A1	Known case of diabetes

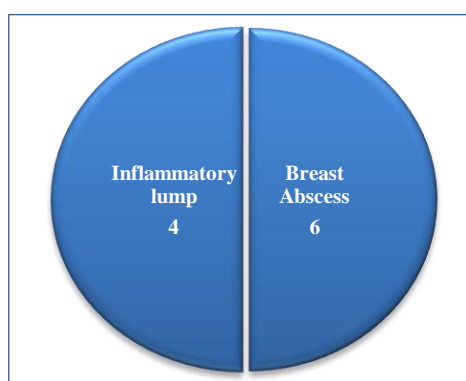


Figure 1: Modes of presentation of granulomatous mastitis.

Five patients had presented with breast abscess. One of the patient had a past history of Incision and drainage of

the opposite breast done for lactation abscess. 5 patients presented with breast lump which was diagnosed as inflammatory after USG and FNAC (Figure 1). The various modes of presentation of the disease in our patients in the study- 4 had presented with inflammatory lump and 6 with breast abscess

All underwent excision of the lump and 2 of them had to undergo repeated procedures for abscess/wide excision. USG breast was performed in all cases. Hypochoic abscess was seen in 5 cases. An ill-defined mass was observed in 2 patients, and diffusely increased asymmetric density was observed in 4 patients.

In case number 4, patient was a 45 year old P3L2D1 who presented with painful lump in the right breast (Figure 2). She had a past history of doing 5 surgeries- incision and drainage on both breasts in the past one year. USG confirmed presence of inflammatory mass and no pus

collection. She underwent wide excision of lump (Figure 3).

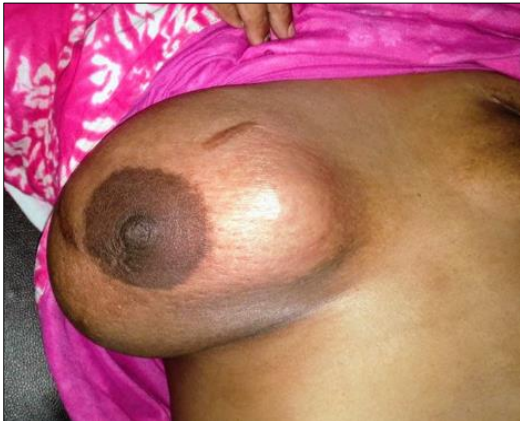

Figure 2: Right breast at the time of clinical presentation.

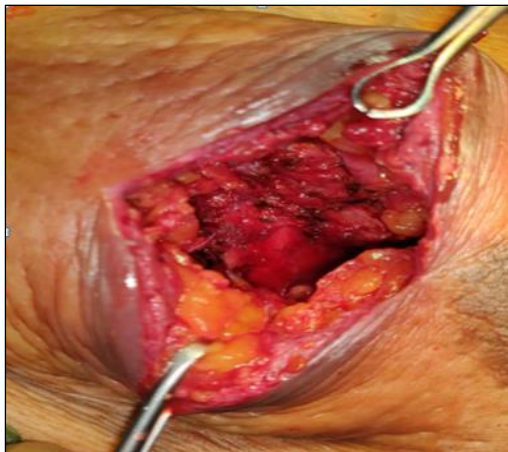


Figure 3: Wide excision of lump.

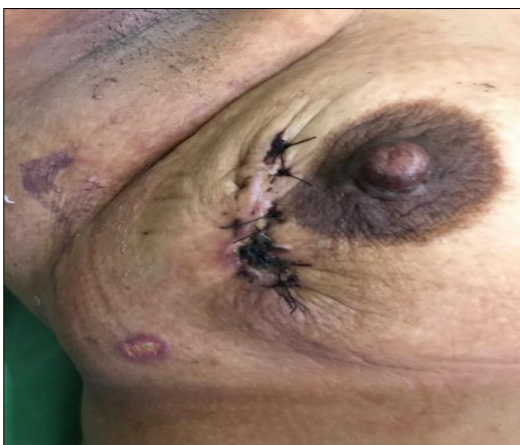


Figure 4: Secondary suturing of the wound.

Antibiotics were given. The primary wound which was initially closed, started to gape and there was an underlying pus collection found. After another Incision

and drainage, and repeated dressings, the wound was secondarily sutured (Figure 4).

The duration of complete resolution of the disease was ranging from 2 weeks to 2 months, as shown (Figure 5). Mean duration was 6 weeks. One of the patients took 18 weeks for complete resolution of the disease. One out of 10 patients had only 1 surgery for complete resolution of symptoms. Others had to undergo repeated surgeries in the form of incision and drainage of abscess or wide local excision of lump (Table 2). Case number 4 had to undergo surgeries repeatedly for 7 times for complete resolution of the disease.

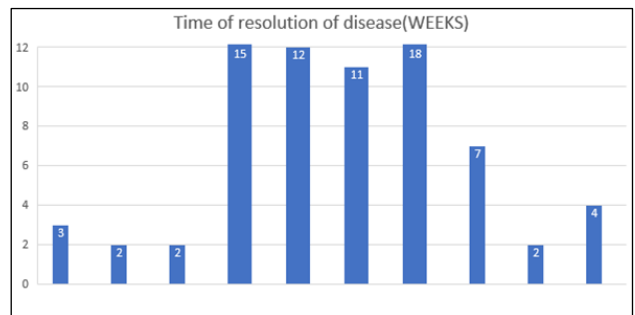


Figure 5: The distribution of the time of resolution of the disease in all 10 cases ranging from 2 weeks to 18 weeks.

Table 2: The number of surgeries required for each of the patient.

Case number	Number of surgeries
1	3
2	1
3	2
4	7
5	3
6	5
7	2
8	2
9	3
10	2

DISCUSSION

Idiopathic granulomatous mastitis is an uncommon breast lesion that is well known for its worrisome clinical presentations as a hard breast lump, particularly in younger women. Affected women are nearly always parous and usually present in their early thirties.⁷ On the whole, unilateral involvement of the breasts is common, although bilateral disease has also been reported.⁸ A tender extra-areolar lump is the usual presentation associated with fixation to the skin or to the underlying pectoralis muscle. Occasionally, retraction of nipple is seen, and regional lymphadenopathy may be present in up to 15% of cases.⁷ Patients will have a breast mass that can vary in size from 0.5 to 9 cm, and often the overlying

skin is inflamed. Inflammatory breast lesions of this kind may be clinically mistaken for malignancy, particularly if reactive draining lymph nodes are enlarged.

The etiology of IGM is unclear. The postulated causes include autoimmune disease, undetected organisms, reaction to childbirth and the use of oral contraceptives, but there are reports of IGM occurring in patients who have not received oral contraceptives.^{1,5} Fletcher and colleagues suggested that the initial event was damage to ductular epithelium by infection, trauma or chemically induced inflammation, which allowed luminal secretion to escape into the lobular connective tissue, where it stimulated a granulomatous response and further damaged the lobular structures.⁸

Baslaim et al, described abscesses in GM as differing from acute pyogenic abscesses; in GM, they are more diffuse and composed of multiple small loculi that communicate through tiny channels. In our cases, USG revealed such architecture of abscesses and demonstrated fluid flow through those channels. Figure 6 shows the ultrasound images of all the loculi with fluid filled inside (usually pus) with intercommunicating channels, which are characteristic of granulomatous mastitis.

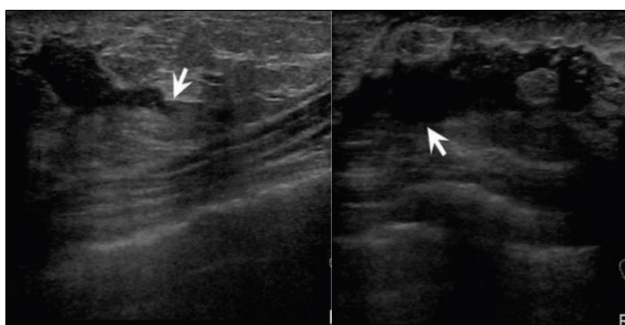


Figure 6: USG of the breast showing fluid filled loculi with intercommunicating channels.

There is yet to exist a noninvasive diagnostic tool to confirm the diagnosis of granulomatous mastitis. In one study, it has been shown that the IL-33 levels of patients with histological diagnosis of IGM have been found to be higher than those with breast cancer. Moreover, according to the ROC curves, IL-33 levels were both highly sensitive (93.75%) and specific (96%) in differentiating IGM from breast cancer. Therefore, IL-33 levels if used in conjugation with ultrasound and mammography can favor a diagnosis of IGM. However, the only method for definitive diagnosis at this point remains biopsy.⁹

There is still no generally accepted optimal treatment for GM. Wilson et al analyzed 116 cases of GM that were reported in the literature in 2007.¹⁰ A total of 9 patients were observed without medical intervention. The use of oral corticosteroids as primary therapy was reported in 26 patients, and 15 (58%) had only a partial response.

Complete excision, including partial mastectomy, was the most commonly reported approach (n ¼ 75), and 16 patients (21%) had recurrence. Mastectomy was reported in 3 patients. Although wide excision of the mass is traditionally performed, complete excision of the whole inflammatory mass with a negative margin might be impossible, especially when it involves more than one quadrant, because the cosmetic outcome would be unacceptable.

Dixon et al, argued that with a definitive diagnosis of GM, a nonsurgical approach is the ideal treatment option, with aspiration or Incision and Drainage of abscesses performed only when required.^{11,12} However, the role of Incision and Drainage is controversial because it may not improve the condition and may lead to intractable incision tracks, which subsequently lead to sinus formation.

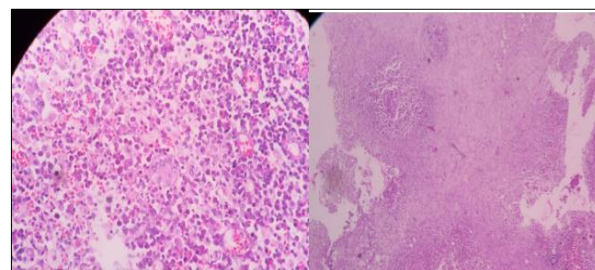


Figure 7: Marked cellularity in the form of densely scattered polymorphonuclear inflammatory cells, numerous foamy macrophages along with few singly scattered tiny clusters of necrotic ductal cells amidst an uncleared amorphous and necrotic background.

On histology, granulomatous mastitis is characterized by noncaseating granulomas in as well as around lobules and often in association with microabscess and fistula formation. The noncaseating granulomas are made up of epithelioid histiocytes, neutrophils, and lymphocytes. Multinucleated giant cells were found in almost 78.5% of the case studies. Moreover, plasma cells were also encountered in almost all the specimens studied. Almost 53.9% of the cases showed cystic vacuoles rimmed with neutrophils in the center of the granulomas.¹³ Figure 7 shows marked cellularity in the form of densely scattered polymorphonuclear inflammatory cells, numerous foamy macrophages along with few singly scattered tiny clusters of necrotic ductal cells amidst an uncleared amorphous and necrotic background. There is growing evidence of an association between corynebacteria infection and a distinct pattern termed cystic neutrophilic granulomatous mastitis (CNGM), characterized by lipogranulomas consisting of clear spaces rimmed by neutrophils and surrounding granulomatous inflammation.¹⁴

Steroids as a primary treatment have proved to be beneficial.¹⁵ Treatment with steroids is usually lengthy and can last for about 6 months; however, it is used for conservative management for its good success rates.¹⁶

This treatment has been shown to help in shrinking the lesion both pre- and postoperatively in persisting masses.¹⁷ Immunosuppressive drugs such as methotrexate and azathioprine have been considered as alternatives in case of recurrence or in case of deleterious side effects of prednisolone.¹⁸ Satisfactory results have reported with high dosages of prednisone (60 mg/d for 2-3 weeks); however, the recurrence rate can be as high as 50%.¹⁹

CONCLUSION

Idiopathic Granulomatous Mastitis is a clinico-pathological diagnosis of exclusion. The diagnosis of IGM must be based on a multidisciplinary approach. Since biopsy is the gold standard in diagnosing granulomas, all suspicious specimen should be sent for histopathological examination since there is no confirmatory radiological investigations. This emphasizes the awareness among surgeons, radiologists and pathologists of this unusual but distinctive entity. The common etiological factor being Tuberculosis in India should be excluded as it can also cause caseating granulomas. Surgical management followed by antibiotics is sufficient to treat the condition. Corticosteroids need not be administered in all cases of this benign breast disease. However an optimal treatment algorithm for IGM is yet to be formulated. A lot of research still has to be done to determine the best treatment options associated with the lowest recurrence rates. Increased awareness of these diseases will improve understanding and management of them.

Funding: No funding sources

Conflict of interest: None declared

Ethical approval: Not required

REFERENCES

- Kessler E, Wolloch Y. Granulomatous mastitis: a lesion clinically simulating carcinoma. Am J Clin Pathol. 1972;58(6):642-6.
- Inflammatory and reactive tumors. In: Rosen PP. Rosen's Breast Pathology. 3rd ed. Philadelphia, PA: Lippincott Williams and Wilkins; 2009:33-70.
- Lai EC, Chan WC, Ma TK, Tang AP, Poon CS, Leong HT. The role of conservative treatment in idiopathic granulomatous mastitis. Breast J. 2005 Nov;11(6):454-6.
- Bakaris S, Yuksel M, Crugil P, Guven MA, Ezberci F, Bulbuloglu E. Granulomatous mastitis including breast tuberculosis and idiopathic lobular granulomatous mastitis. Canadian J Surg. 2006 Dec;49(6):427.
- Going JJ, Anderson TJ, Wilkinson S, Chetty U. Granulomatous lobular mastitis. J Clin Pathol. 1987;40(5):535-40.
- Scoglietti V, Wooldridge R, Leitch AM, Euhus D, Sarode V, Huth J, et al. Development and initiation of a clinical protocol for the treatment of idiopathic granulomatous mastitis. J Rare Disorders. 2014;2(1):1-6.
- Jorgensen MB, Nielsen DM. Diagnosis and treatment of granulomatous mastitis. Am J Med. 1992;93:97-101.
- Fletcher A, Magrath IM, Riddell RH, Talbot IC. Granulomatous mastitis: a report of seven cases. J Clin Pathol. 1982 Sep 1;35(9):941-5.
- Yigitbasi MR, Guntas G, Atak T, Sonmez C, Yalman H, Uzun H. The role of interleukin-33 as an inflammatory marker in differential diagnosis of idiopathic granulomatous mastitis and breast cancer. J Invest Surg. 2017 Jul 4;30(4):272-6.
- Wilson JP, Massoll N, Marshall J, Foss RM, Copeland EM, Grobmyer SR. Idiopathic granulomatous mastitis: in search of a therapeutic paradigm. Am J Surg. 2007;73(8):798-802.
- Dixon JM, Bundred NJ. Management of disorders of the ductal system and infections. In: Harris JR, Lippman ME, Morrow M, Osborne CK, eds. Diseases of the Breast. 4th ed. Philadelphia, PA: Lippincott Williams & Wilkins; 2010:42-51.
- Dixon JM, Chetty U, Salam IMA, Sim AJW. Diagnosis and treatment of granulomatous mastitis. Brit J Surg. 1995;82(8):1143-4.
- Helal TE, Shash LS, El-Din SA, Saber SM. Idiopathic granulomatous mastitis: cytologic and histologic study of 65 Egyptian patients. Acta cytologica. 2016;60(5):438-44.
- Alibi S, Ferjani A, Gaillot O, Marzouk M, Courcol R, Boukadida J. Identification of clinically relevant Corynebacterium strains by Api Coryne, MALDI-TOF-mass spectrometry and molecular approaches. Pathologie Biologie. 2015 Sep 1;63(4-5):153-7.
- Velidedeoglu M, Kilic F, Mete B, Yemisen M, Celik V, Gazioglu E, et al. Bilateral idiopathic granulomatous mastitis. Asian J Surg. 2016 Jan 1;39(1):12-20.
- Aghajanzadeh M, Hassanzadeh R, Sefat SA, Alavi A, Hemmati H, Delshad MS, et al. Granulomatous mastitis: presentations, diagnosis, treatment and outcome in 206 patients from the north of Iran. Breast. 2015 Aug 1;24(4):456-60.
- Yau FM, Macadam SA, Kuusk U, Nimmo M, Laeken NV. The surgical management of granulomatous mastitis, Ann Plast Surg. 2010 Jan;64(1):9-16.
- Sheybani F, Sarvghad M, Naderi H, Gharib M. Treatment for and clinical characteristics of granulomatous mastitis. ObstetGynecol. 2015 Apr 1;125(4):801-7.
- Pereira FA, Mudgil AV, Macias ES, Karsif K. Idiopathic granulomatous lobular mastitis. Int J Dermatol. 2012 Feb;51(2):142-51.

Cite this article as: Karthik AH, Suraj L. Management of idiopathic granulomatous mastitis: a surgical experience of ten cases. Int J Res Med Sci 2020;8:2653-7.