

Case Report

Bone marrow involvement as a rare manifestation of relapsed choroidal melanoma

Nusrat Bashir*, Farzana Manzoor, Bilal Musharaf, Ruby Reshi

Department of Pathology, GMC, Srinagar, Jammu and Kashmir, India

Received: 12 June 2020

Accepted: 06 July 2020

***Correspondence:**

Dr. Nusrat Bashir,

E-mail: bashirrusrat@ymail.com

Copyright: © the author(s), publisher and licensee Medip Academy. This is an open-access article distributed under the terms of the Creative Commons Attribution Non-Commercial License, which permits unrestricted non-commercial use, distribution, and reproduction in any medium, provided the original work is properly cited.

ABSTRACT

Choroidal Melanoma is the most common primary intra-ocular malignancy. Incidence of primary choroidal melanoma is about 6 cases per 1 million population. It disseminates hematogenously. The most common site of metastasis is liver. Metastatic melanoma involving the bone marrow is rare, occurring in 5% of patients with disseminated disease. However, Choroid melanoma with bone marrow involvement is very rare. Only a few case reports are published in literature. Authors present a case of bone marrow metastasis from choroid melanoma in 55 years old female who has been treated for primary choroidal melanoma by enucleation of left eye three years back. In the evaluation of symptomatic anemia, features suggestive of bone marrow infiltration by choroidal melanoma were observed on bone marrow aspiration and biopsy. The diagnosis was confirmed by positivity of immunohistochemistry markers HMB-45 and Melana.

Keywords: Bone marrow, Choroidal, Melanoma, Metastasis

INTRODUCTION

Choroidal Melanoma is the most common primary malignant intra-ocular tumor and the second most common type of primary malignant melanoma after cutaneous. It is a type of uveal melanoma and arises from melanocytes within the choroid. Incidence of primary choroidal melanoma is about 6 cases per million population.

It occurs around the age of 55 years and more frequently in men. Choroidal melanoma can be fatal in 50% of patients because of metastatic disease.¹ It disseminates hematogenously, with a high propensity for liver, which is typical and most common (93%) site of metastasis, followed by lung (24%) and bones (16%).² Metastatic melanoma involving the bone marrow is rare, occurring in 5% of patients with disseminated disease.³ However,

Choroidal melanoma with bone marrow involvement is very rare.⁴

Bone marrow is a heterogeneous organ containing diverse cell types and it is a preferred metastatic site for several solid tumors such as breast and prostate cancer.⁵

Bone marrow metastasis results in cytopenias, thus presenting clinical features include fatigue, dizziness, orthostatic hypotension, bleeding and infections. Here we present a case of bone marrow involvement as a very rare manifestation of relapsed Choroidal melanoma.

CASE REPORT

Authors present a case of 55 year old female who had undergone enucleation of left eye three years back for choroidal melanoma. Patient was lost to follow up when 3 months back, she visited the oncology outpatient

department with easy fatigability and asthenia. She was emaciated and had severe pallor on general physical examination. Systemic examination was unremarkable. Complete blood count revealed hemoglobin of 7.2 mg/dl. Endoscopic examination of upper and lower gastrointestinal tract was normal. Bone marrow aspiration showed infiltration by non-hematopoietic cells scattered individually (Figure 1).

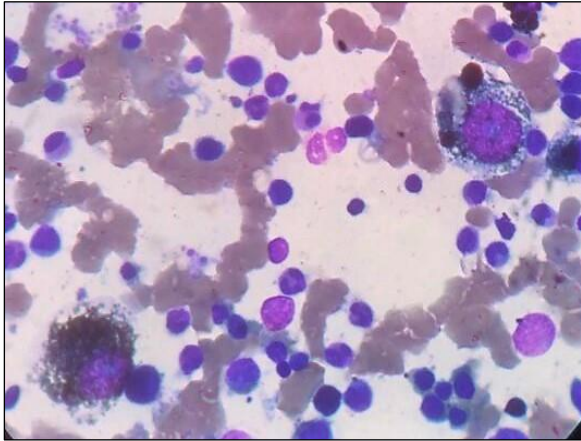


Figure 1: Bone marrow aspirate malignant cells with dense pigment deposits.

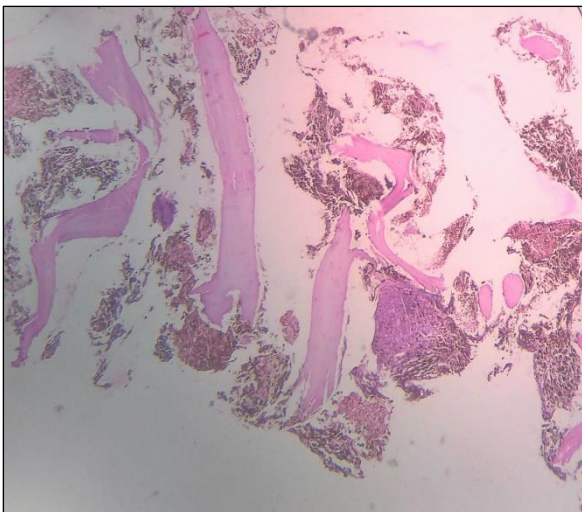


Figure 2: Bone marrow biopsy dense pigment obscuring the tumor cells.

The cells were pleomorphic with round nuclei, prominent nucleoli and abundant basophilic cytoplasm with cytoplasmic vacuoles and dense pigment deposits. Few of these cells showed binucleation and multinucleation. Iron stores were 4+ (increased). Bone marrow biopsy was done which revealed normal bony trabeculae and replacement of inter-trabecular marrow spaces by numerous black brown pigment laden tumor cells (Figure 2). The diagnosis of choroid melanoma metastatic deposition was confirmed by positivity of immunohistochemistry markers (HMB-45) (Figure 3).

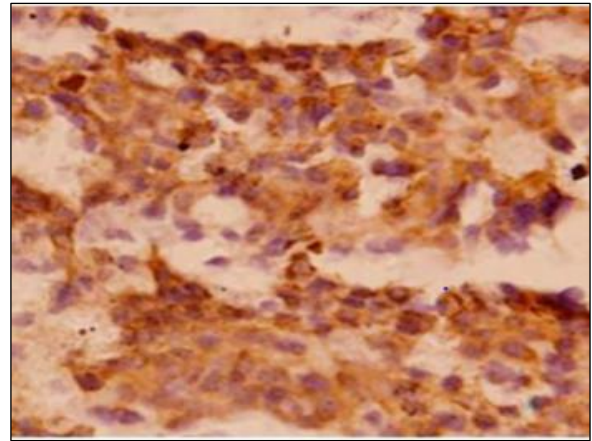


Figure 3: IHC (HMB-45) tumor cells are positive for HMB-45.

CECT of whole body showed two well-defined heterogeneously enhancing space occupying lesions in segment III and VII of liver. Rest of the metastatic work up was normal. Patient is now on regular follow up since 3 months and is receiving cisplatin based chemotherapy

DISCUSSION

The most frequent metastatic sites of choroidal melanoma are the liver, the lungs, and the bones. The majority of the recurrences and metastasis occur within 3 years; therefore, more frequent follow up in the early period is necessary.⁶ Bone marrow metastasis in the present case was diagnosed after 3 years of initial diagnosis.

In a retrospective review of 293 cases of stage IV melanoma patients during a 15-year period, 28 cases (9.5%) with bone metastases were identified out of which only 7.4% cases had bone marrow infiltration.⁷

The bone marrow is one of the sites in body involved by tumors that metastasize hematogenously. In adults the tumors most often seen are carcinomas of the prostate, breast and lung.^{8,9} In children neuroblastoma, rhabdomyosarcoma and retinoblastoma account for the majority of metastasis.¹⁰

Bone marrow (BM) aspirations and trephine biopsies are sensitive techniques for detecting bone marrow infiltration. Trephine biopsy is more sensitive than bone marrow aspiration and sensitivity is increased by performing bilateral biopsy or by obtaining a single large biopsy and therefore these two procedures should be regarded as complementary.⁷ Imaging techniques like radionuclide bone scan, magnetic resonance and computed tomography are usually ineffective and BM aspiration and biopsy remain the procedure of choice to document BM involvement.^{8,9}

Typically, melanoma is reactive for vimentin, S-100, HMB-45, Melan A, tyrosinase and microphthalmia

transcription factor.⁹ HMB-45 is a much more specific marker than S-100 protein. In our case there was strong positivity for HMB-45 and Melan A.¹⁰

CONCLUSION

Bone marrow involvement by malignant melanoma is very rare and treated patients should be kept on close and regular follow up for early diagnosis of metastasis.

Funding: No funding sources

Conflict of interest: None declared

Ethical approval: Not Required

REFERENCES

1. Damato B, Eleuteri A, Taktak AF, Coupland SE. Estimating prognosis for survival after treatment of choroidal melanoma. *Prog Retin Eye Res* 2011;30:285-95.
2. Collaborative Ocular Melanoma Study Group. Assessment of metastatic disease status at death in 435 patients with large choroidal melanoma in the Collaborative Ocular Melanoma Study (COMS): COMS report 15. *Arch Ophthalmol* 2001;119:670-6.
3. Serrier C, Lesesve JT. Metastatic malignant melanoma in bone marrow: *Am Soc Hematol, Blood*. 2013;121:721.
4. Hsiao SY, Chen TY. Uveal Melanoma with diffuse bone marrow involvement: *Am Soc Hematol Blood*. 2014;124:1996.
5. Shiozaw Y, Ebew MR, Berry JE, Taichman RS. Bone Marrow as amatastatic niche for disseminated tumor cells from solid tumors. *Bonekey Reports*. 2015;689.
6. Tas F. Metastatic behavior in melanoma: timing, pattern, survival, and influencing factors. *J Oncol*. 2012 Oct;2012.
7. Singh G, Krause JR, Breitfeld V. Bone marrow examination for metastatic tumor. *Cancer*. 1977;40:2317-21.
8. Bearden JD, Ratkin GA, Coltman CA. Comparison of the diagnostic value of bone marrow biopsy and bone marrow aspiration in neoplastic disease. *J Clin Pathol*. 1974;27:735-40.
9. Yaziji H, Gown AM. Immunohistochemical markers of melanocytic tumors. *Int J Surg Pathol*. 2003;11(1):11-5.
10. Bacchi CE, Bonetti F, Pea M, Martignoni G, Gown AM. HMB-45: A review. *Appl Immunohistochem* 1996;4:73-85.

Cite this article as: Bashir N, Manzoor F, Musharaf B, Reshi R. Bone marrow involvement as a rare manifestation of relapsed choroidal melanoma. *Int J Res Med Sci* 2020;8:3110-2.