

## Case Report

# Posterior cruciate ligament and posterolateral corner reconstruction in patient with multiple ligament injury of the knee: a case report

Putu Kermawan\*, I. Gusti Ngurah Wien Aryana

Department of Orthopedics and Traumatology, Sanglah General Hospital, Udayana University, Bali, Indonesia

**Received:** 29 June 2020

**Accepted:** 31 July 2020

### \*Correspondence:

Dr. Putu Kermawan,

E-mail: [putukermawan@yahoo.com](mailto:putukermawan@yahoo.com)

**Copyright:** © the author(s), publisher and licensee Medip Academy. This is an open-access article distributed under the terms of the Creative Commons Attribution Non-Commercial License, which permits unrestricted non-commercial use, distribution, and reproduction in any medium, provided the original work is properly cited.

## ABSTRACT

The treatment of posterolateral corner (PLC) knee injuries has always been a challenging topic due to the low healing capacity of PLC injuries. Authors performed posterior cruciate ligament reconstruction using semitendinosus tendon graft and reconstruction procedure of PLC using free gracilis tendon graft with LaPrade technique in a patient with multiple ligament injury of the knee. A 36-years-old male patient complained of pain on his right knee. On physical examination, the posterior drawer test, dial test, and varus stress test were positive. Magnetic resonance imaging (MRI) on right knee showed that the posterior cruciate ligament (PCL), lateral collateral ligament, and popliteofibular ligament were injured but the popliteus tendon was still intact. A semitendinosus tendon was harvested from the ipsilateral pes anserinus region for posterior cruciate ligament reconstruction. Posterolateral corner reconstruction was done by grafting two gracilis tendons from ipsilateral and contralateral sides using LaPrade technique. The semitendinosus tendon graft had been used for PCL reconstruction in some cases besides the hamstring tendon graft and provides a clinically evident reduction in symptoms and restores satisfactory stability. The LaPrade technique for PLC reconstruction was one of the earliest descriptions of a surgical option to recreate the anatomy of the three main static stabilizers of the PLC. We reported a reconstructive procedure for PCL and PLC injury of the knee by using semitendinosus and gracilis tendon graft with LaPrade technique.

**Keywords:** Multiple ligament injuries, Posterior cruciate ligament, Posterolateral corner, Reconstruction

## INTRODUCTION

The knee is a complex joint consisting of a capsule, ligaments, cartilage, tendons, and bony surfaces that keep the femur aligned with the tibia.<sup>1</sup> The knee is stabilised by both primary stabilisers and secondary stabilisers. Primary knee stabilisation is achieved through knee ligaments, while muscles around the knee play a secondary role, although both work congruently to help the knee function reliably. The secondary stabilisers of the knee joint are all the muscles surrounding the knee alongside the hip muscles and the gastrocnemius muscle. The ligaments of the knee such as the transverse, arcuate popliteal, oblique popliteal, anterior cruciate ligament (ACL), posterior cruciate ligament (PCL),

medial collateral ligament (MCL), lateral collateral ligament (LCL), and popliteofibular ligament (PFL) all act as knee stabilisers.<sup>2</sup>

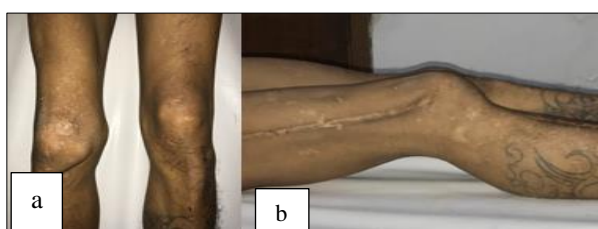
Multiple ligament injuries are rare but potentially disabling traumatic events that involve at least two of the four major ligaments of the knee. The four major ligaments are the ACL, PCL, posteromedial corner (PMC) including the MCL, and PLC including the LCL.<sup>3</sup> The PLC of the knee itself consists of important stabilizing structures that play a crucial role in varus and rotational stability through all ranges of motion.<sup>4,5</sup> The three major static stabilizers of the PLC are the fibular collateral ligament (FCL), popliteus tendon (PLT), and PFL.<sup>1,4</sup> The structures in the posterolateral corner of the

knee, which stabilize the joint, are often involved in injuries to the PCL.<sup>1</sup>

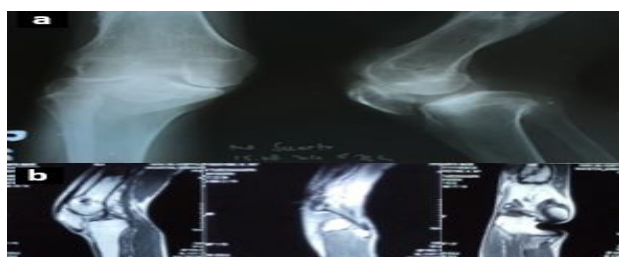
A recent systematic review of the literature demonstrated that early operative treatment of multiple ligament injury of the knee yields improved functional and clinical outcomes compared with nonoperation or delayed surgery.<sup>3</sup> For the PCL injury, surgery is indicated if it is accompanied with multiple ligament injuries such as PLC knee injuries.<sup>6</sup> The treatment of PLC knee injuries has always been a challenging topic due to the low healing capacity of PLC injuries.<sup>7</sup> The use of graft for multiple ligament reconstruction is still in debate all around the world. There are three choices of grafts, which are auto grafts, allografts, and synthetic grafts. By far the two most commonly used grafts are central third bone-patellar tendon-bone and hamstring tendon, either semitendinosus alone or semitendinosus combined with gracilis.<sup>8-10</sup> Authors performed posterior cruciate ligament reconstruction using semitendinosus tendon graft and reconstruction procedure of PLC using free gracilis tendon graft with LaPrade technique in a patient with multiple ligament injury of the knee.

### CASE REPORT

A 36-year-old male patient complained of pain on his right knee. The patient was referred to Sanglah Hospital with diagnosis of suspect multiple ligaments injury of the right knee (PCL injury, PLC injury, and lateral meniscus injury). He had a history of traffic accident in 2013. He underwent an operation with open reduction internal fixation with plate and screw on his right femur and tibia. On July 2014, he underwent a surgery to remove the plate and screw on his right femur. The surgery was done in Buleleng District Hospital. The plate and screw on his right tibia was removed on February 2015.



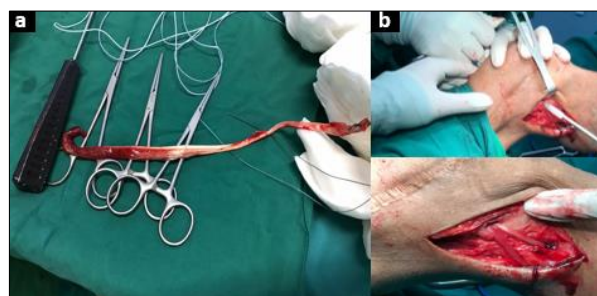
**Figure 1: Clinical picture of the patient.**



**Figure 2: The radiologic examination result of the patient, plain X-ray and b) MRI.**

The clinical picture of the patient is depicted in (Figure 1). On physical examination, posterior drawer test was positive. Assessment of the posterolateral structures was done with the tibial external rotation recurvatum and dial test and the results were positive. LCL was evaluated using varus stress test with knee in 30° flexion and the result was positive. Several imaging studies have been done to confirm the diagnosis (Figure 2). Radiographic imaging (plain x-ray) showed some abnormalities, such as narrowing of the right knee joint space with anteromedial translation of the right femur from the right tibia (Figure 2a). Magnetic resonance imaging (MRI) of right knee showed that the PCL, LCL, and PFL were injured but the PLT was still intact (Figure 2b).

Ligament reconstruction with LaPrade technique were planned to treat the injury. The patient underwent posterior cruciate ligament reconstruction by the semitendinosus tendon graft technique, simultaneously with two gracilis tendons grafting for posterolateral corner ligament reconstruction (Figure 3). A semitendinosus tendon was harvested from the ipsilateral pes anserinus region in the usual manner. First, a vertical paramedian incision is made at the level of the tibial tubercle and the sartorial fascia is exposed. An L-shaped incision in the sartorial fascia allows for reflection of the fascial layer, which will then expose the tendons. The gracilis should be released distally at its insertion and whip stitched using looped suture. The tendon is then placed through an open tendon stripper and released from its muscular attachment proximally. The gracilis tendon is then sized (Figure 3a), and if deemed insufficient in diameter, the semitendinosus tendon is harvested in an identical fashion.



**Figure 3: The intra-operative condition, a) gracilis tendon graft, b) LaPrade technique.**

The fibula-based construct used a gracilis auto graft to create a ‘figure-of-eight’ graft from the lateral condyle of the femur to the proximal fibula, reconstructing the LCL and PFL (figure 3b). A 7 mm anterior to- posterior fibular tunnel was created using a cannulated reamer maintaining a complete corticocancellous bone bridge around the margins of the tunnel, for anchoring at lateral femoral condyle we used a 2.5 mm drill to create a hole to a depth of approximately 30 mm, The doubled gracilis grafts were passed through the fibular tunnel where the anterior and posterior arms were brought proximal, the posterior

arm of the graft was passed over the anterior aspect of the screw and the anterior arm of the graft was passed over the posterior aspect of the screw. To test the stability of the knee, varus stress test, dial test, posterior sag test and posterior drawer test were done.

## DISCUSSION

In this case, authors performed simultaneous PCL and PLC reconstruction. PCL reconstruction was performed by using semitendinosus tendon graft technique, whereas the PLC reconstruction was performed based on LaPrade technique by using gracilis tendon graft technique. The semitendinosus tendon graft had been used for PCL reconstruction in some cases besides the hamstring tendon graft. A retrospective case series performed by Cury, et al showed that Double bundle arthroscopic PCL reconstruction based on the anatomical positioning of the tunnels, with double semitendinosus tendon and single quadriceps, provides a clinically evident reduction in symptoms and restores satisfactory stability, although no statistically significant difference was found due to the small sample.<sup>11</sup> In 2004, LaPrade, et al described an anatomic reconstruction of the PLC using the native attachments of the FCL, PLT, and PFL. This was one of the earliest descriptions of a surgical option to recreate the anatomy of the three main static stabilizers of the PLC. Performing simultaneous PCL and PLC reconstructions using semitendinosus and gracilis tendon auto grafts for combined multiple ligament injuries is an optimal method that is effective and reproducible for a timely return of motion, strength, and function with favourable outcome. It is a safe, reliable, time saving and cost-effective option with better patient compliance without compromising the functional results.

## CONCLUSION

Performing simultaneous PCL and PLC reconstructions using semitendinosus and gracilis tendon auto grafts for combined multiple ligament injuries is an optimal method that is effective and reproducible for a timely return of motion, strength, and function with favourable outcome. Authors reported a reconstructive procedure for PCL and PLC injury of the knee by using semitendinosus and gracilis tendon graft with LaPrade technique.

*Funding: No funding sources*

*Conflict of interest: None declared*

*Ethical approval: Not Required*

## REFERENCES

1. Schweller EW, Ward PJ. Posterolateral corner knee

- injuries: Review of anatomy and clinical evaluation. J American Osteop Asso Epub. 2015;148.
2. Jawed F Abdulhasan, Michael J. Gray. Anatomy and physiology of knee stability. J Funct Morphol Kinesiol. 2017;2(4):34.
  3. Levy BA, Dajani KA, Whelan DB, Stannard JP, Fanelli GC, Stuart MJ, et al. Decision making in the multiligament-injured knee: an evidence-based systematic review. Arthroscopy - J Arthroscopic Rel Sur. 2009;25(4):430-8.
  4. LaPrade RF, TV Ly, Wentorf FA, Engebretsen L. The posterolateral attachments of the knee. a qualitative and quantitative morphologic analysis of the fibular collateral ligament, popliteus tendon, popliteofibular ligament, and lateral gastrocnemius tendon. Am J Sports Med. 2003;31(6):854-60.
  5. RF LaPrade, Tso A, Wentorf FA. Force measurements on the fibular collateral ligament, popliteofibular ligament and popliteus tendon to applied loads. Am J Sports Med. 2004;32(7):1695-701.
  6. Chahla J, von Bormann R, Engebretsen L, LaPrade RF. Anatomic posterior cruciate ligament reconstruction: State of the Art. J ISAKOS Jt Disord Orthop Sport Med. 2016;1:5.
  7. Franciozi CE, Kubota MS, Abdalla RJ, Cohen M, Malheiros Luzo MV, et al. Posterolateral corner repair and reconstruction: overview of current techniques. Ann Jt. 2018;3:89.
  8. Panigrahi R, Mahapatra AK, Priyadarshi A, Das DS, Palo N, Biswal MR. Outcome of simultaneous arthroscopic anterior cruciate ligament and posterior cruciate ligament reconstruction with hamstring tendon autograft: a multicenter prospective study. Asian J Sports Med. 2016;7(1):e29287.
  9. Charalambous CP, Kwaees TA. Anatomical considerations in hamstring tendon harvesting for anterior cruciate ligament reconstruction. Muscles Ligaments Tendons J. 2013;2(4):253-7.
  10. Kern M, Love D, Cotter EJ, Postma W. Quadruple-bundle semitendinosus-gracilis graft technique for all-inside anterior cruciate ligament reconstruction. Arthrosc Tech. 2016;5(6):e1317-e1320.
  11. Cury R, Filho R, Sadatsune D, Prado D, Gonçalves R, Mestriner MB. Posterior Cruciate ligament reconstruction with auto graft of the double semitendinosus muscles and middle third of the quadriceps tendon with double femoral and single tibial tunnels: clinical results in two years follow-up. Rev Bras Ortop. 2012;52(2):203-9.

**Cite this article as:** Kermawan P, Aryana IGNW. Posterior cruciate ligament and posterolateral corner reconstruction in patient with multiple ligament Injury of the knee: a case report. Int J Res Med Sci 2020;8:3374-6.