

Original Research Article

In vivo experimental infection of sarcosporidiosis and toxoplasmosis of rabbits in Duhok Province, Kurdistan region, Iraq

Shivan N. Hussein, Mohammed S. Shukur*

Department of Veterinary Medicine and Surgery, College of Veterinary Medicine, University of Duhok, Iraq

Received: 23 July 2020

Revised: 04 Sep 2020

Accepted: 05 Sep 2020

*Correspondence:

Dr. Mohammed S. Shukur,

E-mail: mohammed.shukur@uod.ac

Copyright: © the author(s), publisher and licensee Medip Academy. This is an open-access article distributed under the terms of the Creative Commons Attribution Non-Commercial License, which permits unrestricted non-commercial use, distribution, and reproduction in any medium, provided the original work is properly cited.

ABSTRACT

Background: *Sarcocystis* species and *Toxoplasma gondii* are both zoonotic obligatory intracellular protozoan organisms and cyst-forming coccidian parasites that occur in domestic animals and human throughout the world.

Methods: Forty local breed rabbits were divided into four groups, each group ten. Group one were infected with *Sarcocystis*, group two with *Toxoplasma* and group three with both parasites and last group was non-infected control group. The LAT serological test was used for detection of anti-toxoplasma antibody in serum of *Toxoplasma* infected rabbits. The direct impression smears stained with Giemsa was prepared from different body organs including; liver, lung, heart, brain and skeletal muscle for detection of tissue cysts (Bradyzoites) of *T. gondii* and microcysts of *Sarcocystis*.

Results: In group one, 70% of infected rabbits were positive for toxoplasmosis by serological test; both are and by impression smear method 80% of the rabbits were positive for *T. gondii* with tissue cysts. Fifty percent of rabbits were positive for microcysts of *Sarcocystis* by direct impression smear method in group two. In group three, the impression smear and latex agglutination method were positive in 40% and 60% of rabbits, respectively. Statistically, there was no significant difference in detection of toxoplasmosis and sarcocystosis by LAT and impression smear method in group one and three.

Conclusions: Rabbits could be source of toxoplasmosis and sarcocystosis and have public health implications and hazard as source of food. They might be source of infection for cats and shed environmentally resistant oocysts.

Keywords: Oocysts and sporocysts, Protozoan parasites, Tissue cysts

INTRODUCTION

Sarcocystis species and *Toxoplasma gondii* both are zoonotic obligatory intracellular protozoan organisms and cyst-forming coccidian parasites that occur in domestic animals and human throughout the world. These parasites are classified in the phylum Apicomplexa, class Sporozoasida and of family Sarcocystidae.

Their life cycle include herbivorous (prey) as the intermediate hosts and Carnivorous (predators) as the

definitive hosts.¹ *Toxoplasma gondii* infection is a major cause of caprine and ovine perinatal mortality and abortion, but commonly it doesn't appear to cause significant disease in other ruminants. *Sarcocystis* species infection is most significant in growing ruminants that may cause subclinical anemia and weight loss.²

Recently, it has been suggested that certain species of *Sarcocystis* and *T. gondii* can cause severe and fatal diseases during their acute phases of infection in the intermediate hosts.^{3,4}

Toxoplasma gondii infection in rabbits was firstly discovered in 1908 by Splendore, since then several clinical cases of the disease among rabbits have been recorded by a number of authors in different countries.⁵

The life cycle of *Sarcocystis* in rabbits is unclear and still under investigations. Toxoplasmosis in rabbits exists in different forms including; latent infection, progressive chronic and acute infection. *T. gondii* in rabbits can cause severe and fatal infections.⁴

Sarcocystis infection is commonly found in heart and skeletal muscle of most vertebrate animals including; sheep, goats, cattle and rabbits.^{1,6}

The present study was undertaken to determine the role of rabbits as herbivorous intermediate hosts in the life cycle of Toxoplasmosis and Sarcocystosis. The transmission of *Sarcocystis* sporocysts and *T. gondii* oocysts from cats to rabbits was also investigated. In addition, the current study performed to determine the definitive host and pre-patent period for shedding of *Sarcocystis* sporocysts by experimental infection.

This is the first experimentally infected report in the area among rabbits through fecal oral route of oocysts of *T. gondii* and sporocysts of *Sarcocystis*.

METHODS

Eggs of parasites

Oocysts of *T. gondii* were obtained from an accidentally infected cat, and sporocysts of *Sarcocystis* were obtained from experimentally infected cat that fed with tissue cysts of macroparasite which teased out from esophageal organ (50 cysts/ two consecutive days) of naturally infected sheep slaughtered from local abattoir in Duhok/ Iraq.

Experimental animals

Forty local breed rabbits of three to four weeks of age were purchased from commercial markets in Duhok province/ Iraq for experimental infection. They weighed 750 gm to 1500 gm, kept in special cages, and divided into four groups (each group 10 animals) for three months.

The first group were given 20 ml of solution containing 3 gm of *T. gondii* oocysts feces dissolved in normal saline (Group 1), the second group were given 20 ml of solution containing 3gm of sporocysts of *Sarcocystis* in normal saline (group 2) and third group were given 20 ml of solution containing 3 gm of mixed feces from both infected cats (group 3).

Lastly, group four were given 20 ml of normal saline solution as control group. All groups were provided with rodent's food, vegetables and water during the period of the study. Two accidentally and experimentally infected

cats aged from 3 to 4 months were kept in special cages and prepared for the experimentation.

This study was conducted in laboratories of college of Veterinary Medicine, University of Duhok during the period from February 2019 to October 2019.

Ethical approval was obtained from ethics committee of the College of Veterinary Medicine, University of Duhok.

Before experimental infection the rabbits were examined by serological test (LAT) for detection of anti-*toxoplasma* antibody in blood serum and hypersensitivity reaction test by intradermal injection of *sarcocystis* antigen into the neck of rabbits that measured by caliber in order to exclude the positive animal.

The cat which prepared for experimental infection with macroscopic type of sarcocyst was examined by fecal flotation technique for two weeks to be insured that it has not been infected previously and free from infection.

Diagnostic techniques

Fecal samples

All fecal samples that collected from cats were processed by standard sucrose flotation and examined for the presence of oocysts of *T. gondii* and sporocysts and oocysts of *Sarcocystis*.^{7,8} Approximately 5 grams of feces were suspended in sheather's solution (specific gravity 1.26 for *Toxoplasma*, and 1.15 for *sarcocystis*), sieved by double layer of gauze before centrifuged at 1500 rpm for 10 min. A cover slide slip which was placed on top of centrifuged tube was removed and examined under light microscope at X10 and X40 magnification.

The Mac Master technique was used to estimate the intensity of infection by calculating the number of eggs/gram of feces. The White Lock Mac Master egg counting slide (the slide has 3*0.3 ml chambers, each chamber sub-divided into 2 counting areas of 0.15 ml) was used in this study according to Australian Standard Diagnostic Technique for Animal Diseases.

Two grams of feces was mixed with 2.5 ml of distilled water and 55.5 ml of sheather's solution, and left for 5 minutes. The two chambers of Mac Master Slide was filled with the mixture and left for 10 minutes again, then examined under the compound microscope X10 magnification for calculation of eggs number per gram of feces.

The numbers of eggs per gram (epg) of feces determined by multiplying the number of eggs of each chamber in the scanned area of the slide by:

Volume of (feces sample + water) + Flotation solution / feces sample Volume x Measurement volume used.

Hypersensitivity reaction test

The modified method of Hettiarachchi and Rajapakse in 2008 was used in this study to examine the hypersensitivity reaction.

Fifteen macroscopical cysts of *Sarcocystis* from naturally infected slaughtered sheep were teased out from the esophagus muscle with fine forceps.⁹ The collected cysts were washed with saline in a test tube to remove the attached tissue. They were macerated by using fine forceps. A drop of the suspension was examined under compound microscope (Figure 1) to confirm the existence of tachyzoites.



Figure 1: Tachyzoites of macrocysts of sarcocyst (Bulged cysts) from esophagus of sheep (X 40).

The suspension centrifuged and re-suspended with phosphate buffered saline (PBS). The supernatant was poured and 2.25 ml of PBS was added into 0.25 ml of the sediment.

The prepared suspension (*Sarcocystis* antigen) injected intradermally into the neck of the rabbit (Figure 2) to determine localized infection by thickness and edema of the skin. The skin was measured by Caliber before and after injection.

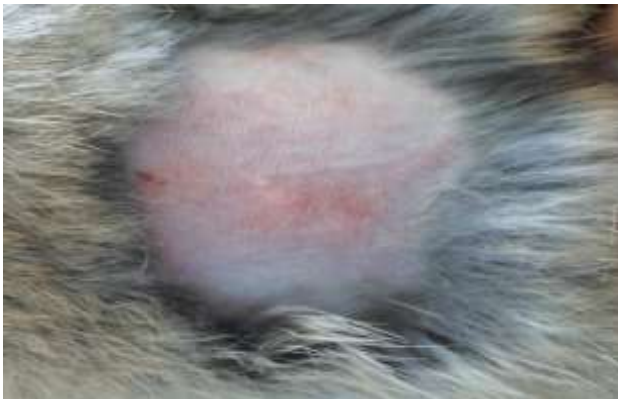

Figure 2: Rabbit skin showed no localized reaction including thickness and edema (1.15 mm by caliber).

Blood sample

Four to five ml of blood from experimentally infected rabbits in groups 1, 3 and control group directly after sacrificing were collected into anticoagulant-free tubes before centrifuging for 5 minutes at 3000 rpm for serological examination and detection of anti-*Toxoplasma* antibody.

Direct impression smear examination

The cut edge of tissue sample from different organ including lung, liver, heart, brain and skeletal muscle after touched with the filter paper to remove excess blood was pressed gently on to slide. The impression smear was dried and fixed in absolute methanol for five minutes before staining with 7% of Giemsa stain.

Finally the slide was examined under the compound microscope with power X40 and X100 oil immersion.¹⁰

Latex agglutination test (LAT)

The rapid LAT was performed with the serum samples of experimentally infected rabbits by using RF Latex Kit.¹¹ The technique was used according to the instruction of the manufactured company. Fifty μ l of each serum samples were placed on a slide and 50 μ l of the reagent added to each sample including the control sample after shaking the reagent container (vial).

Each 2 drops (100 μ l of sample and reagent) were separately mixed with a stick until the whole surface of the slide section was covered. The slide was rotated for two minutes manually to observe the agglutination.

Statistical analysis

Unpaired Student's t-test were used to compare the means of data sets. The statistical tests were stated as significant at 95% confidence interval.

RESULTS

Experimentally and naturally infected cats

Prior to the experiment, the cat that intended for inducing the sarcocysts experimental infection, was examined by Sheather's flotation test to ensure that the cat is free from oocysts and sporocysts. For experimental infection, two different macroscopic cysts were found on the esophagus of sheep measuring (Mean: 39.19 cm length/8.57 cysts) fed to the cat. The first type is called bulged cyst (fat type) which have different sizes and appeared rounded.

The second cystic type is called embedded (thin type) which appeared small, rice grain like and cylindrical in shape (Figure 3).

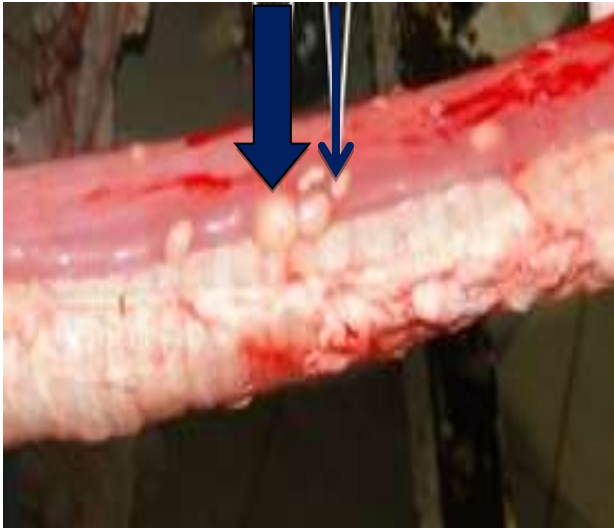

Figure 3: Bulged cyst (thick arrow) and embedded cyst (thin arrow) of macroscopic type of sarcocyst in esophagus of sheep.

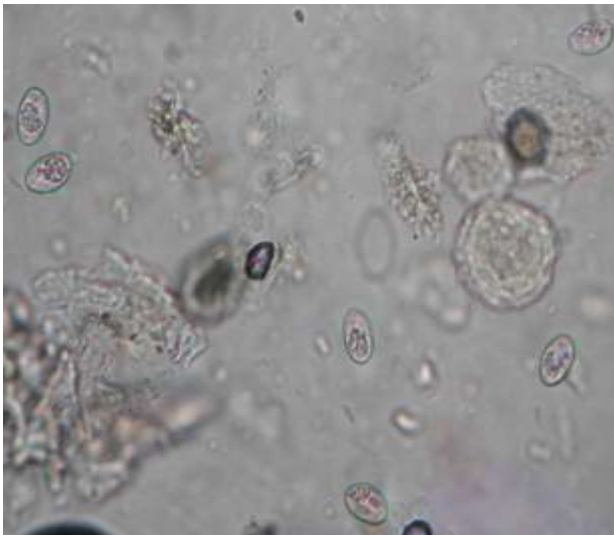


Figure 4: Free sporocysts with sporozoites and inclusion bodies (residuum) in the feces of cat (X 40).

The result of the experiment showed that the cat excreted large number of sporocysts in feces at pre-patent period of one week (Figure 4).

The number of the sporocysts in the feces of cat was about 17.7×10^3 per gram.

The accidentally infected cat was found positive with *Toxoplasma gondii* oocyst in the feces following examination by sheather's flotation method (Figure 5).

The intensity of oocysts of toxoplasmosis in eggs per gram of feces was 5.5×10^3 .

Experimentally infected rabbits

The selected rabbits for experimental infection before entering the experiment were examined by LAT and it was found that all rabbits were healthy and free from toxoplasma infection. Hypersensitivity test for detection of *Sarcocystis* antigen-antibody reaction was negative and there was no localized reaction, thickness or edema at the site of injection on the skin. The measurement of the skin by caliber before and after intradermal injection of the rabbits remained steady (1.15 millimeter).

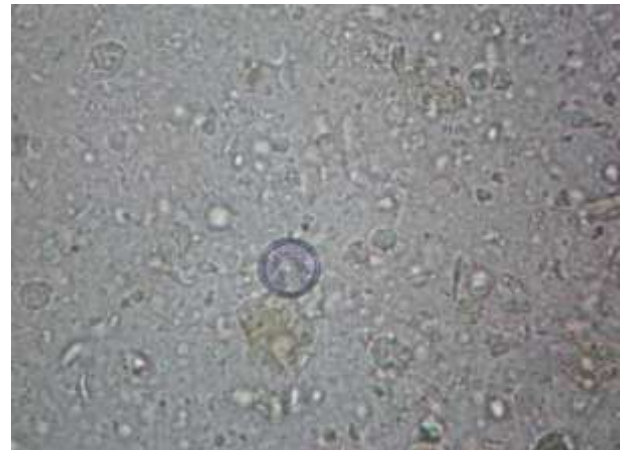

Figure 5: Oocyst of *Toxoplasma gondii* in the feces of naturally infected cat (X 40).

Clinical signs and necropsy findings

Through daily observation of the experimental rabbits and 30 days post infection (30 DPI), the animals in group one and three showed decreased appetite, depression, weight loss, emaciation, high fever (pyrexia) and slight diarrhea.

At the end of the study, necropsy findings revealed that all body flesh of the sacrificed animals specially group one and three illustrated whitish pale in colour and fluid in consistency (edema). The Internal organs including lung, liver, spleen, heart and kidneys were enlarged and congested. Petechial red foci (necrotic foci) were observed in various abdominal organs especially in heart. The brain showed severely congested and became very soft in texture (Encephalomalacia). The animals in group 2 showed no significant clinical signs. The animals in control group were clinically normal and no lesions and organ enlargement were found by autopsy.

Serological examination and impression smears

Two different techniques were used for detection of *T. gondii* and *Sarcocystis* infection (Table 1).

Table 1: Percentage of *sarcocysts* and *toxoplasma* infection in 3 groups of experimental rabbits by impression smear and latex agglutination test.

No. of Rabbits	Techniques	Toxoplasma% Group 1	Sarcocyst% Group 2	Mixed infection% Group 3
30	DISM	8 out of 10 80%	5 out of 10 50%	4 out of 10 40%
	LAT	7 out of 10 70%	-	6 out of 10 60%

DISM=Direct impression smear Method. LAT=Latex agglutination Test.

LAT was used to detect presence of anti-*toxoplasma* antibody in the serum of experimental animals. It is observed that 7 out of 10 (70%) in group one and 6 out of 10 (60%) in group three showed positive results.

For detection of toxoplasmosis direct impression smears was performed. The results showed that in group one, 8 out of 10 (80%) of the examined rabbits were positive. There was also typical bradyzoites (tissue cysts) in different sizes in various body organs (Figure 6).

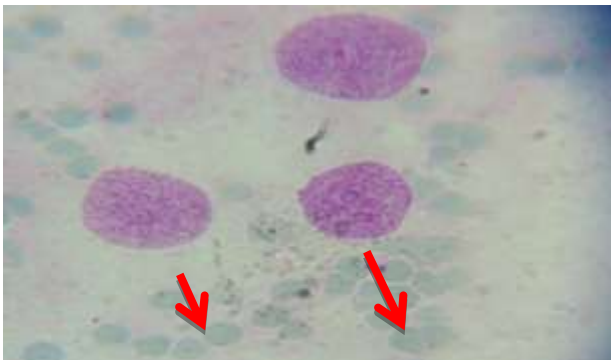


Figure 6: Bradyzoites of *T. gondii* in brain by impression smear stained with Giemsa stain (high power).

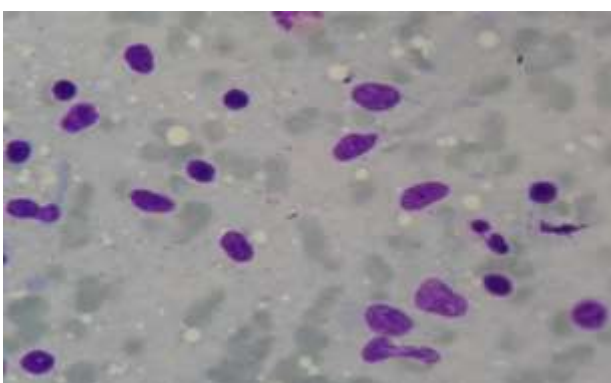


Figure 7: Elliptical, rounded and oval cysts of sarcocystosis by impression smear stained with Giemsa stain high power.

In addition, impression smear method was used for *Sarcocystis* bradyzoites detection. It was detected that in group two, 5 out of 10 (50%) of rabbits showed positive results with different shapes and size of tissue cysts of

Sarcocystis including elliptical, oval and rounded cysts (Figure 7).

In group three that infected with both *toxoplasma* and *sarcocystis* infection, 4 rabbits out of 10 (40%) were positive and both types of the protozoan parasitic tissue cysts were observed in different body organs (Figure 8). In control group both techniques for toxoplasmosis and sarcocystosis showed no positive cases.

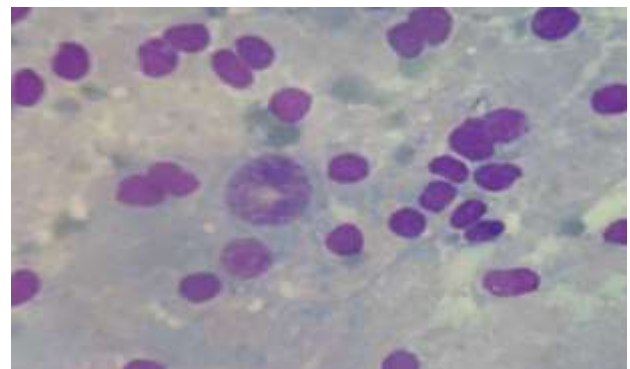


Figure 8: Bradyzoites of sarcocyst species (small cysts), Tissue cyst of *T. gondii* (large cyst at center) stained with Giemsa stain (high power).

The intensity of tissue cysts of *T. gondii* by direct impression smear was high and severe in brain of the examined rabbits, but it was low to moderate in other body organs including liver, lung, heart and skeletal muscle. The tissue cysts of *Sarcocystis* infection was high in intensity in body organs such as heart and muscle, while it was low in liver, kidneys and brain (Table 2).

Table 2: Intensity score of *sarcocystis* microcyst and *T. gondii* tissue cysts in different body organs by impression smear method.

Organs	<i>Toxoplasma</i> cysts	<i>Sarcocysts</i> cysts
Brain	+++	+
Heart	+	+++
Liver	++	++
Lung	++	++
Skeletal muscle	-	++

(+++) \geq 100 cysts/field. (++)=50-100 cysts/field. (+)=25-50 cysts/field.

Statistically there was no significant difference ($p>0.05$) in the detection of toxoplasmosis by LAT between group one and three, and between group two and three by impression smear method in detection of *Sarcocystis* infection.

DISCUSSION

The current study is the first experimental infection of two protozoan parasites sarcocystosis and Toxoplasmosis in rabbits by oro-fecal route in the area among rabbits. In this study the oocysts of *T. gondii* and *Sarcocystis* which are shed by cats are allowed to sporulate and are efficient of achieving infection in rabbits. It confirmed that rabbits could serve as a suitable intermediate hosts for sarcocystis and toxoplasma infection and might play a great role in the transmission and establishment of the parasitic infection.

In this study the diagnosis of both protozoan infection for detection of *Toxoplasma gondii* cycts (bradyzoites) and macroscopic cysts of *Sarcocystis* depended on direct impression smear method and serological examination.

In general, there are several other methods used for diagnosis of sarcocystosis and toxoplasmosis in different host including final and intermediate hosts. Commonly, they can be diagnosed by direct parasitic observation in stained tissue section and biopsy material, serological examination through IFAT, ELISA and Sabin-Feldman dye test, indirect haemagglutination test, LAT, complement fixation test and polymerase chain reaction (PCR) technique. Various techniques have been used by several authors Hussein and Zangana in 2017 and Aghwan et al in 2010, for detection of *Sarcocystis* and *Toxoplasma* infection. These include Pepsin digestion, squash preparation, tape adhesive, modified latex agglutination, latex agglutination, muscle biopsy and histopathological examination in different intermediate hosts.^{12,5}

Several reports have suggested that the LAT and impression smear examination are valuable techniques in the detection of *Toxoplasma* and *Sarcocystis* infection in different animals including rabbits. Sroka and Sukthana found that LAT was convenient and dependable as serological screening test to detect IgG and IgM antibodies in case of infection with *T. gondii*.^{13,14}

The experimental infection of group one was done by feeding (oro-fecal rout) of rabbits with *T. gondii* oocysts that obtained from accidentally infected cats. The present study found that 70% of examined rabbits in group one was positive in LAT, and 80% of them were positive by direct impression smear. Similar results have been reported in Mosul in 2010 by Aghwan and colleagues.⁵

They found that 82% of naturally infected rabbits were positive for *Toxoplasma gondii* infection by impression smear method that performed on samples from different

body organs, and 86% of the animals were positive by LAT.⁵

The result of serological response to toxoplasma antigen in rabbits varies among different countries in the world. In Germany, positive cases were 53%, in China were 2.2 - 8.3%, and in republic of Czech were 48.4 to 57.9%.¹⁵⁻¹⁸

In this study the experimentally infected rabbits with toxoplasmosis showed significant behavioral change and clinical signs including anorexia, emaciation, high fever, rapid breathing and diarrhea. Similar clinical signs have been reported by Hazirolu et al., in 2003.¹⁹ However no clinical signs of nervousness such as tremor were observed in experimentally infected rabbits by toxoplasmosis although high intensity of tissue cyst was found in the brain tissue of the animals. In contrast, reports by Ether Van Praag, Sroka and his colleagues.

Dubey and Carpenter (1993), and James and his colleagues (2004) revealed neurological signs similar to those of encephalitozoonosis which including; tremor, ataxia, epilepsy like attack and paralysis of the hind limbs.^{4,14,20,21}

The intensity of tissue cysts of *T. gondii* in brain were high and more than those in lung, liver, heart and skeletal muscle. This could be due to the localization of the parasite that mostly occur in brain.^{22,23} However, the pathological lesions of *Toxoplasma* infection commonly can be observed in liver and spleen.²⁴

In current study, 50% of rabbits that were infected by *Sarcocystis* (group two), showed positive results of sarcocystosis by direct impression smear from different body organs. This was in agreement with the results of other authors (Munday et al in 1980), who found the development of *sarcocystis* bradyzoites in different body organs including skeletal muscle and brain of rabbits.²⁴ So, it can be suggested that rabbit could be a good animal model for cases of *Sarcocystis* infection.

Furthermore, in third group of rabbits that were infected with both sarcocyst's oocysts and sporocysts and toxoplasma oocysts, bradyzoites of sarcocyst were detected in 40% by impression smear method and tissue cysts of *T. gondii* were detected in 60% by LAT of the examined animals. This is a new design of experimentation which has not been mentioned before by authors. Behavioral changes and clinical signs in this group were similar to those in first group which infected with *Sarcocystis* alone.

In this study, the experimental infection performed to determine the definitive host and pre-patent period for shedding sporocysts or infective stage of sarcocystosis. After the cat experimentally infected with macroscopic type sarcocystosis from esophagus of sheep, the definitive host (cat) shed eggs within the period of one week. The intensity of *Sarcocystis* sporocysts in feces of

definitive host by number of eggs/ gram of feces 17.7×10^3 is sufficient to cause infection in intermediate hosts as reported by Jeffrey in 1993.²⁵ In addition, the intensity of toxoplasmosis oocysts of 5.5×10^3 in gram of feces of definitive host is enough to make infection and abortion in pregnant intermediate hosts. This is identical with the David Buxton study in 1998, they determined that, the ingestion of total number of 2000 oocyst of *T. gondii* orally can cause abortion in pregnant ewes.²⁶

CONCLUSION

Depending on the study results, it is revealed that the rabbits are considered as the potential source of toxoplasmosis and sarcocystosis and have public health implications and hazard as they use as source of food. Rabbits could be infected with both protozoan parasites in a high ratio. They are also considered as a source of infection for cats and shed environmentally resistant oocysts.

ACKNOWLEDGEMENTS

Authors would like to thank Dr. Ihsan K. Zangana in sample processing, as well as for the support of College of veterinary medicine/University of Duhok.

Funding: No funding sources

Conflict of interest: None declared

Ethical approval: The study was approved by the Institutional Ethics Committee

REFERENCES

- Dubey J, Lindsay DS. Neosporosis, toxoplasmosis, and sarcocystosis in ruminants. *Veterinary Clinics of North America: Food Animal Practice* 2006;22(3):645-71.
- Ugla A, Buxton D. Immune responses against *Toxoplasma* and *Sarcocystis* infections in ruminants: diagnosis and prospects for vaccination. *Revue scientifique ET technique. International Office of Epizootics* 1990;9(2):441-62.
- Dubey J. Experimental Transmission of *Sarcocystis muris* (Apicomplexa: Sarcocystidae) sporocysts from a Naturally Infected Cat (*Felis catus*) to Immunocompetent and Immunocompromised Mice. *The Journal of parasitology* 2013;99(6):997-1001.
- Van Praag, Esther. Toxoplasmosis, an unrecognized parasitosis in rabbits. 2014; 10.13140/2.1.3251.9368. Available at: http://www.medirabbit.com/EN/Neurology/Toxoplasma/Toxo_rab_en.pdf.
- Aghwan SS, Al-Tae AF, Sulimam EG. Detection of *Toxoplasma gondii* infection in domestic rabbits by using multiple techniques. *Iraqi J Vet Sci* 2010;24(2):65-9.
- Dubey JP, Passos LM, Rajendran C, Ferreira LR, Gennari SM, Su C. Isolation of viable *Toxoplasma gondii* from feral guinea fowl (*Numida meleagris*) and domestic rabbits (*Oryctolagus cuniculus*) from Brazil. *J Parasitol* 2011;97(5):842-5.
- Coles, E.H. *Veterinary Clinical Pathology*, ed. 4th, London, W.B. Saunders Company 1986;374-77.
- Gajadhar AA, Measures L, Forbes L B, Kapel C, Dubey J P. *J Parasitol* 2019;90(2):255-9. Published by: Allen Press on behalf of The American Society of Parasitologists Stable. Available at: <https://www.jstor.org/stable/3286262> Accessed: 12-11-2019 17:08 UTC.
- Hettiarachchi DC, Rajapakse RPVJ. Antigenic analysis of bovine *Sarcocystis* spp. in Sri Lanka. *J Natn Sci Foundation Sri Lanka* 2008;36 (3):239-44.
- Soulsby E.J.L. *Helminths, Arthropods, and protozoa of domesticated animals*. 7th edition. Bailliere, Tindall, London 1986:680.
- Cortez-RF Latex Agglutination Kit. Diagnostic Automation / Cortez Diagnostic, Inc. Immuno Diagnosis. 2016 CORE CODE#2C. Available at: www.rapidtest.com.
- Hussein SN, Zangana IK. Prevalence of *Sarcocystis* species (*S. ovicanis* and *S. capricanis*) in tongue muscle of sheep and goats in Duhok province, Kurdistan Region/ North Iraq. *ARO-The Scientific Journal of Koya University* 2017;5(1):5.
- Sukthana Y, Chintara T, Supatanapong W, Siripan A, Lekkla A, Cheabchalrad R. 31G Predictive Value of latex agglutination test in serological screening for *Toxoplasma gondii* South east Asian J. Trop Med Public Health 32:314-8.
- Sroka J, Zwolinski J, Dutkiewicz J, Luty S.T, Latuszynska J. Toxoplasmosis in rabbits confirmed by strain isolation: A potential risk of infection among agricultural workers. *Ann Agric Evniron Med* 2003;10:125-8.
- Werner H. Spontaneous *Toxoplasma* infection in the domestic rabbit (*Oryctolagus cuniculus*). *Zbl Bakteriol Orig* 1966;199:259-63.
- Sima O, Rasin K. *Toxoplasma gondii* Nicolle ET Manceaux 1909- antibodies in domestic rabbits. *Vet Med. (Praha)*. 1973;18:633-40.
- Zhang GN. Epidemiological study on *Toxoplasma* infection in human beings and animals in Shandong Province. *Zhonghua Liu Xing Bing Xue Za Zhi* 1989;10:30-3.
- Lin S, Ling ZC, Zeng BC, Yang HY. Prevalence of *Toxoplasma gondii* infection in man and animals in Guangdong, peoples Republic of China. *Vet Parasitol*. 1990;34:357-60.
- Haziroglu R, Altintas K, Atasever A, Gulbahar MY, Tunca OR. Pathological and immune-histochemical studies in rabbits experimentally infected with *Toxoplasma gondii*. *Turk J Vet Anim Sci* 2003;27:285-93.
- Dubey JP, carpenter JL. Histopathological confirmed clinical toxoplasmosis in cat, 100 cases *J.AM Vet Med Assoc* 1993;203:1556-65.
- James W. Carpenter, MS, DVM, Diplomate ACZM. *Neurologic and Musculoskeletal Diseases. Ferrets Rabbits Rodents*. 2004;20(2):203-10.

22. Dubey JP, Brown CA, Carpenter JL, Moore JJ. Fatal Toxoplasmosis in domestic Rabbits in the USA. *Vet parasitol* 1992;44:305-9.
23. Gustafsson KE, Wattrang C, Fossum RMH, Heegaard R, Lind Uggla A. *Toxoplasma gondii* infection in the mountain hares (*Lepus timidus*) and domestic rabbit (*Oryctolagus cuniculus*). *Pathology J comparative Pathol.* 1997;117:351-60.
24. Munday BL, Smith DD, Frenkel JK. Sarcocystis and related organisms in Australian wildlife: iv. Studies on *Sarcocystis cuniculi* in European Rabbits (*Oryctolagus cuniculus*). *J Wildlife Dis.* 1980;16(2):201-4.
25. Jeffrey M. Sarcocystosis of sheep. *Journal of Comparative Pathology*; Florida, CRS press; 1993: 3-7.
26. Buxton D. Protozoan infections (*Toxoplasma gondii*, *Neospora caninum* and *Sarcocystis* spp.) in sheep and goats: recent advances. *Veterinary Research* 1998;29(3-4):289-310.

Cite this article as: Hussein SN, Shukur MS. *In vivo* experimental infection of sarcosporidiosis and toxoplasmosis of rabbits in Duhok Province, Kurdistan region, Iraq. *Int J Res Med Sci* 2020;8:3467-74.