

## Original Research Article

# Antiulcerogenic effect of *Capparis cartilaginea decne* on indomethacin induced gastric ulcer in wistar rats

Nancy W. Mugo<sup>1\*</sup>, Christine Wangia<sup>2</sup>, Gideon Kikvi<sup>3</sup>, Samuel Ngugi<sup>1</sup>

<sup>1</sup>Department of Medical Physiology, <sup>2</sup>Department of Pharmacology and Pharmacognosy, <sup>3</sup>Department of Environmental Health and Disease Control, Jomokenyatta University of Agriculture and Technology, Nairobi, Kenya

**Received:** 24 July 2020

**Accepted:** 03 September 2020

### \*Correspondence:

Nancy W. Mugo,

E-mail: [nancymugow@gmail.com](mailto:nancymugow@gmail.com)

**Copyright:** © the author(s), publisher and licensee Medip Academy. This is an open-access article distributed under the terms of the Creative Commons Attribution Non-Commercial License, which permits unrestricted non-commercial use, distribution, and reproduction in any medium, provided the original work is properly cited.

## ABSTRACT

**Background:** Peptic ulcer disease is a non-malignant, mucosal lesion of the stomach or duodenum. The mucosal defect reaches the muscularis mucosa and sometimes, beyond causing life threatening complications, including haemorrhage, perforations, gastrointestinal obstruction and malignancy.

**Methods:** The animals were pre-treated with omeprazole 20 mg/kg and 300 mg/kg of *Capparis cartilaginea decne* orally for 14 days. On the 15<sup>th</sup> day, ulcers were induced using indomethacin 30 mg/kg and 4 hours post ulcer induction, they were sacrificed. Ulcer index, pH, total acidity and volume were determined.

**Results:** Extensive lesions were seen in indomethacin ulcerated rats with mean ulcer score of (1.260±0.18). In comparison, there were minimal areas of erosion on animals pre-treated with omeprazole (0.14±0.025) and plant extracts (0.280±0.097). Indomethacin-induced ulcer treated animals showed the highest volume of gastric juice output (3.14±0.21 ml), whereas the animals pre-treated with omeprazole had lower gastric juice output (2.20±0.29 ml). This was comparable to animals pre-treated with the plant extract (1.80±0.13 ml). The pH was high in animals pre-treated with omeprazole (5.02±0.53). This was also seen in animals pre-treated with the extract (4.82±0.31). This was in comparison to the low pH seen in indomethacin ulcerated animals (2.20±0.16). Indomethacin-induced ulcer treated animals showed high levels of total acidity (88.64±1.71 mEq/L). Whereas the animals pre-treated with omeprazole had lower total acidity (55.26±3.77 mEq/L), which was also mirrored in animals pre-treated with the plant extracts (61.44±2.42 mEq/L).

**Conclusions:** The extracts of *Capparis cartilaginea decne* showed anti-ulcer effect on indomethacin induced ulcers in Wistar rats.

**Keywords:** Indomethacin, Omeprazole, *Caparris cartilaginea decne*, Peptic ulcers

## INTRODUCTION

Peptic ulcer disease is a non-malignant, mucosal lesion of the stomach or duodenum in which pepsin and acid plays a major pathogenic role.<sup>1</sup> The mucosal defect caused by peptic ulcers reaches the muscularis mucosa and sometimes, beyond. It is usually associated with life threatening complications, including haemorrhage, perforations, gastrointestinal obstruction and malignancy. The life-threatening complications may necessitate surgery, and if untreated, can cause death.<sup>2</sup>

Acid and pepsin plays an important role in peptic ulcer formation when *Helicobacter pylori*, NSAIDs or other uncommon factors like radiation, stress, chemotherapy and vascular insufficiency disrupt normal mucosal defence and healing mechanisms.<sup>3</sup> The mechanism of gastric-mucosal defence includes several local and neuro-hormonal protective factors, which allow the mucosa to resist exposure to damaging factors. This includes bicarbonates, prostaglandins and mucosal blood flow.<sup>4</sup> Non-steroidal anti-inflammatory drugs cause mucosal damage by recruiting circulating neutrophils and causing

endothelial adhesion through inhibition of prostaglandin biosynthesis.<sup>5</sup> These adhered neutrophils cause clogs in the micro vascular causing local decrease of mucosal blood flow and significant release of tissue damaging factors including proteolytic enzymes and leukotriene's, which lead to severe degrees of mucosal damage.<sup>6</sup>

## METHODS

*Capparis cartilaginea decne* plant was collected following identification of the plant among the Marakwet community through the guidance of a taxonomist. The leaves were cut into small pieces using a knife and air dried under shade in room temperature for two weeks. The leaves were then grinded and milled into course powder using an electric grinder made at the mechanical engineering department at JKUAT.<sup>7</sup> The crude aqueous extract of *Capparis cartilaginea decne* was prepared, whereby 50 g of plant powder was mixed with 500ml of distilled water in a 1 litre flask and boiled. The residue was then filtered using Whatman No.1 filter paper and evaporated to dryness by freeze dryer and stored at 4<sup>0</sup>c until ready for use.<sup>8</sup> Methanol extraction was done using 50 g of plant powder of *Capparis cartilaginea decne*, which was prepared by soaking in 500ml of methanol for 72 hours. The extract was concentrated using a rotary evaporator at 45<sup>0</sup>C and stored at 4<sup>0</sup>C until needed.

Female Wistar rats weighing 130-180 gm were used. Wistar rats were obtained and reared following approval from the ethical committee for use and care of laboratory animals. Twenty animals were used, grouped into four, with each group having five animals each. Group 1 was treated with phosphate buffered saline pH 7.4 (normal control), group 2 was treated with indomethacin only 30 mg/kg body weight (ulcerated control), group 3 was treated with indomethacin 30 mg/kg body weight, 30 minutes after pre-treatment with omeprazole 20 mg/kg body weight and group 4 was treated with indomethacin 30 mg/kg body weight, 1 hour after pre-treatment of 300 mg of extracts.

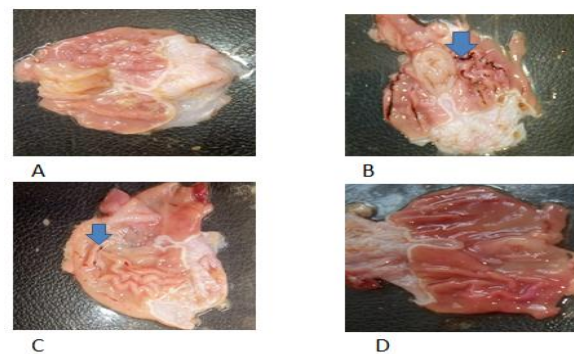
Ulcers induction by indomethacin was done by administering a single oral dose of 30 mg/kg body weight of indomethacin tablets.<sup>9</sup> Treatments with the reference drug and extracts lasted for 14 days prior to ulcer induction. These were orally administered once daily using oral intubator with provision of food and water throughout the experimental period.

On the fifteenth day (4 hours post ulcer induction) the animals were euthanized in the carbon-dioxide chamber. The stomachs were immediately removed and opened along the greater curvature and all gastric contents drained into a centrifuge tube. These were observed for macroscopic lesions and the ulcer index determined using the following formulae described by Adinortey et al.<sup>10</sup> The gastric content was then centrifuged and volume of supernatant measured. The pH was measured using a digital pH meter. To determine total acidity, 1 ml of

centrifuged and filtered gastric juice was diluted with 1 ml distilled water and taken into 50 ml conical flask. Then 2 drops of phenolphthalein indicator were added and titrated with 0.01N Sodium hydroxide until a permanent pink colour was observed. The volume of sodium hydroxide added was noted. The total acidity was expressed in mEq/L.<sup>11</sup>

## RESULTS

Plate A illustrates the appearance of the stomach lining of the rat that was treated with phosphate buffered saline only. The colour of the stomach lining is normal in appearance. In comparison, plate B shows the stomach lining of the rat that was treated with indomethacin only. It shows extensive areas of ulceration with mean ulcer index of (1.400±0.14). Plate C shows animals pre-treated with the extract of *Capparis cartilaginea decne* before administration of indomethacin. There is notable reduction in the ulcer index (0.280±0.097) compared to indomethacin treated only animals (1.40±0.14). The plate D above shows stomach lining of animals pre-treated with omeprazole before indomethacin administration. There are minimal areas of erosion as evident by the ulcer index (0.14±0.025).



**Figure 1: Macroscopic stomach lining of rats, (A) normal control, (B) indomethacin induced ulcer, (C) extract and indomethacin, (D) omeprazole and indomethacin.**

Gastric volume was significantly increased in indomethacin only treated group ( $p<0.001$ ) when compared to control group. This was significantly reduced after administration of *Capparis cartilaginea decne* ( $p<0.001$ ) and omeprazole ( $p<0.001$ ). The pH was significantly decreased in indomethacin group ( $p<0.001$ ) when compared to control group, while significantly increased after administration of (*Capparis cartilaginea decne* and indomethacin) ( $p<0.001$ ) and (omeprazole and indomethacin) ( $p<0.001$ ). Volume of gastric output was significantly increased in indomethacin treated group ( $p<0.001$ ), but was significantly decreased after administration of *Caparris cartilaginea decne* ( $p<0.001$ ) and omeprazole ( $p<0.001$ ) to indomethacin induced peptic ulcer (Table 1).

**Table 1: Gastric secretion parameters in control, indomethacin, (extract and indomethacin) and (omeprazole and indomethacin) groups.**

Parameters	Control	Indomethacin	Extract and indomethacin	Omeprazole and indomethacin
Volume (ml)	1.69±0.20	3.14±0.21	1.80±0.16	2.20±0.29
pH	2.93±0.45	2.20±0.16	4.82±0.31	5.02±0.53
Total acidity (mEq/l)	81.74±2.14	88.64±1.71	61.44±2.42	55.26±3.77

Values are shown as mean±S.E.M.

## DISCUSSION

Control of gastric acid secretion is the cornerstone in management and prevention of peptic ulcers.<sup>12</sup> Biochemical analysis of gastric secretions and mucosal integrity for stomach is usually employed to ascertain its status following administration of pharmacological agents.<sup>13</sup> The pH gives an idea of the level of acidity and this has been linked to the pathogenesis of gastric damage in experimental animals.<sup>14</sup>

This study observed that indomethacin administration to experimental animals caused macroscopic lesions to gastric tissue such as loss of normal colour, petechial and haemorrhagic streaks. The ulcer index was significant ( $p < 0.05$ ) and was further able to illustrate the macroscopic differences seen in indomethacin treated animals. Indomethacin treated animals (mean=1.400±0.14) had a higher ulcer index compared to animals pre-treated with standard drug (omeprazole+indomethacin=0.140±0.025). There were also significant reductions in the mean ulcer index of animals pre-treated with the extract *Capparis cartilaginea decne* (indomethacin+ extract=0.280±0.097). These lesions are most likely due to alteration of the protective barrier rendering the mucosa less able to resist damage by luminal acid.<sup>10</sup> These findings are in agreement with studies done by Abdelwahab et al.<sup>2</sup>

Indomethacin administration caused significant decreased in pH ( $p < 0.05$ ) with a corresponding significant ( $p < 0.05$ ) increase in gastric volume of gastric content. There was also notable significant ( $p < 0.05$ ) increase in total acidity. This agrees with submissions by other researchers where, indomethacin was reported to have caused alterations in gastric secretions of rats.<sup>13,15,16</sup> The surface of gastric mucosa is covered by a layer formed by mucus gel, bicarbonate anions and surfactant phospholipids.<sup>11</sup> The mucus-mucosa interface, an unstirred layer is capable of maintaining an environment with a pH near 7.<sup>17</sup> Indomethacin, a non-steroidal anti-inflammatory drug, interferes with cyclooxygenase pathway which leads to production of prostonoids. This disruption interferes with the effectiveness of mucus-bicarbonate barrier. These findings are in agreement with submissions by Sabiu et al.<sup>18</sup>

Pre-treatment of the animals with the extracts of *Capparis cartilaginea decne* before ulcer induction with indomethacin caused significant increase in pH, reduced gastric juice output and reduced total acidity ( $p < 0.05$ ). Since omeprazole is a proton pump inhibitor, then the effect produced by the extracts of *Capparis cartilaginea decne* might have perhaps mimicked its mechanism of action by modifying cells in mucosal lining of stomach against excess acid secretion hence the results seen in animals pre-treated with extracts comparable to omeprazole pre-treated animals.

## CONCLUSION

The extract of *Capparis cartilaginea decne* lowered the gastric acidity improving the ability of the stomach lining of experimental animals to resist damage induced by indomethacin. Therefore, further studies to establish the specific compounds and possible mechanism of action in ulcer inhibition is paramount.

## ACKNOWLEDGEMENTS

We acknowledge people involved in animals house caring and also we acknowledge our family members for their support and assistance during our research study.

*Funding: No funding sources*

*Conflict of interest: None declared*

*Ethical approval: The study was approved by the Institutional Ethics Committee*

## REFERENCES

1. Entitlement eligibility guidelines peptic ulcer disease. Available at: <https://gi.org/topics/peptic-ulcer-disease/>. Accessed on 25 May 2020.
2. Abdelwahab M, Abourehab S. Peptic Ulcer: Mini Review. Available at: <https://www.avidscience.com/wp-content/uploads/2017/09/peptic-ulcer-mini-review.pdf>. Accessed on 25 May 2020.
3. Kumar A, Ashwlayan V, Verma M. Diagnostic approach & pharmacological treatment regimen of Peptic Ulcer Disease. Phar Pharm Res Open Acc J. 2019;1(1):1-12.
4. Laine L, Takeuchi K, Tarnawski A. Gastric mucosal defense and cytoprotection: bench to bedside. Gastroenterology. 2008;135(1):41-60.

5. Whittle BJ. Gastrointestinal effects of nonsteroidal anti-inflammatory drugs. *Fundam Clin Pharmacol*. 2003;17(3):301-13.
6. Jiménez MD, Martín MJ, Alarcón de la Lastra C, Bruseghini L, Esteras A, Herreras JM, et al. Role of L-arginine in ibuprofen-induced oxidative stress and neutrophil infiltration in gastric mucosa. *Free Radic Res*. 2004;38(9):903-11.
7. Wangia CO, Orwa JA, Muregi FW, Kareru PG, Cheruiyot K, Kibet J. Comparative anti-oxidant activity of aqueous and organic extracts from kenyan ruellia lineari- bracteolata and ruellia bignoniiflora. *European Journal of medicinal plants*. 2017;17(1):1-7.
8. Iqbal Z, Lateef M, Jabbar A, Akhtar MS, Khan MN. Anthelmintic activity of vemonia anthelmintica seeds against trichostrongylid nematodes of sheep. *Pharmaceutical Biology*. 2006;44(8):563-7.
9. Sayanti RC, Susri C, Subrata KB. Healing properties of some Indian medicinal plants against indomethacin-induced gastric ulceration of rats. *J Clin Biochem Nutr*. 2007;41(2):106-14.
10. Adinortey MB, Ansah C, Galyuon I, Nyarko A. In vivo models used for evaluation of potential antigastroduodenal ulcer agents. *Ulcers*. 2013; 2013:1-12.
11. Wang GZ, Huang GP, Yin GL, Zhou G, Guo CJ, Xie CG, et al. Aspirin can elicit the recurrence of gastric ulcer induced with acetic acid in rats. *Cellular Physiology and Biochemistry. International Journal of Experimental Cellular Physiology, Biochemistry, and Pharmacology*. 2007;20(1-4):205-12.
12. Fornai M, Colucci R, Antonioli L, Awwad O, Ugolini C, Tuc-cori M, et al. Effects of esomeprazole on healing of nonsteroidalanti-inflammatory drug (NSAID)-induced gastric ulcers in the presence of a continued NSAID treatment: characterization of molecular mechanisms. *Pharmacol Res*. 2011;63(1): 59-67.
13. Biplab KY, Sudhir R, Kshama KB, Sandip C. Black tea and the aflavins assist healing of indomethacin-induced gastric ulceration in mice by antioxidative action. *Evid Based Complem Alt Med*. 2011;11:11-22.
14. Lüllmann H, Mohr K, Ziegler A, Bieger D. *Colour atlas of pharmacology*. 2nd ed. New York: Thieme Stuttgart; 2000:166.
15. Bech PL, Xavier R, Lu N, Nanda NN, Dinauer M, Podolsky DK, et al. Mechanisms of NSAID-induced gastrointestinal injury defined using mutant mice. *Gastroenterology*. 2000;119(3):699-705.
16. Muhammed AVK, Thamotharan G, Sengottuvelu S, Haja-Sherief S, Sivakumar T. Evaluation of antiulcer activity of Ficus pumila L. leaf extract in albino rats. *Glob J Res Med Plants Indig Med*. 2012;1(8):340-51.
17. Allen A, Flemström G. Gastro duodenal mucus bicarbonate barrier: Protection against acid and pepsin. *American journal of Cell physiology*. 2004;288:C1-19.
18. Sabiu S, Garuba T, Sunmonu T, Ajani E, Sulyman A, Nurain I, Abdulazeez B. Indomethacin-induced gastric ulceration in rats: protective roles of spondias mombin and ficus exasperata. *Toxicology Reports*. 2015;2:261-7.

**Cite this article as:** Mugo NW, Wangia C, Kikuvu G, Ngugi S. Antiulcerogenic effect of *Capparis cartilaginea decne* on indomethacin induced gastric ulcer in Wistar rats. *Int J Res Med Sci* 2020;8:3445-8.