

Original Research Article

Tinea capitis in adults: not so rare

Sheikh M. Ahmed¹, Suhail R. Rather^{1*}, Hina Kousar², Shahab-ud-din Bukhari¹

¹Department of Dermatology, ²Department of Ophthalmology, SKIMS-MCH, Srinagar, Jammu and Kashmir, India

Received: 17 October 2016

Accepted: 11 November 2016

***Correspondence:**

Dr. Suhail R. Rather,

E-mail: suhail.rather@yahoo.in

Copyright: © the author(s), publisher and licensee Medip Academy. This is an open-access article distributed under the terms of the Creative Commons Attribution Non-Commercial License, which permits unrestricted non-commercial use, distribution, and reproduction in any medium, provided the original work is properly cited.

ABSTRACT

Background: Tinea capitis is the dermatophyte infection of the scalp with varied clinical presentation. Tinea capitis is predominantly seen in preadolescent adults and is rare in adults. Growing number of authors have reported increase in incidence among adults. Clinical presentation in such case is often atypical leading to delay in diagnosis.

Methods: The study included all patients older than 18 years. Informed consent was obtained from all patients. Clinical material was microscopically examined with the use of 20% KOH for hyphae and arthroconidia. The Samples were also inoculated on Sabourauds Agar and Mycosel Agar for 15 days. For each patient we collected information about sex, menstrual status, predisposing factor, symptoms and etiological agent.

Results: Out of 457 cases of tinea capitis 14 patients were adults and represented 3.06% of all cases. All patients were females. The most common etiological agent was *T. violaceum* (35%), followed by *T. mentagrophytes* (21.43%), *T. tonsurans* (14.29%), *T. rubrum* (14.29%) and *T. schoenleinii* (14.29%).

Conclusions: Tinea capitis in adults is not so rare, particularly in post-menopausal women. The presentation is often atypical mimicking other inflammatory conditions of scalp and should be included as a differential diagnosis of inflammatory conditions not responding to conventional treatment.

Keywords: Adults, Clinical presentation, Immunity, Tinea capitis

INTRODUCTION

Tinea capitis is the dermatophyte infection of the scalp with varied clinical presentation. Tinea capitis is predominantly seen in preadolescent adults and is rare in adults. In adults cases generally occur in immunocompromised patients. Tinea capitis may be rare in adults due to the fungistatic activity of long chain saturated fatty acids in sebum which appear after puberty and unknown immunological factors.¹ Colonization by *Malassezia globosa* may interfere with dermatophyte contamination, and the thicker calibre of adult hair may protect against dermatophytic invasion.²

Tinea capitis presents clinically as irregularly shaped scaly alopecic patches, with hair broken off at varying levels from hair follicle.³⁻⁵ The clinical presentation in adults is often atypical; resembling impetigo, folliculitis

decalvans or scalp cellulitis.^{6,7} This atypical presentation along with rarity of the condition in adults often leads to delay in diagnosis.

METHODS

This is a prospective study conducted in Department of Dermatology of SKIMS-MCH from April 2015 to March 2016. The study included all patients older than 18 years. Ethical Clearance was taken from Institute Ethics Committee. Informed consent was obtained from all patients.

Clinically suspected cases of tinea capitis were confirmed by mycological examination. Clinical material was microscopically examined with the use of 20% KOH for hyphae and arthroconidia. The Samples

were also inoculated on sabourauds agar and mycosel agar for 15 days.

For each patient we collected information about sex, menstrual status, predisposing factor (immune status), symptoms and etiological agent.

RESULTS

Out of 457 cases of tinea capitis 14 patients were adults and represented 3.06% of all cases. All patients were females. Eleven were post-menopausal. Median age of diagnosis was, ranging from 39 to 70 years with mean age of 55.29 years. All patients were in good immunity except one patient who was on chronic corticosteroid therapy (Table 1). The most common etiological agent was *T. violaceum* (35%), followed by *T. mentagrophytes* (21.43%), *T. tonsurans* (14.29%), *T. rubrum* (14.29%) and *T. schoenleinii* (14.29%) (Figure 1).

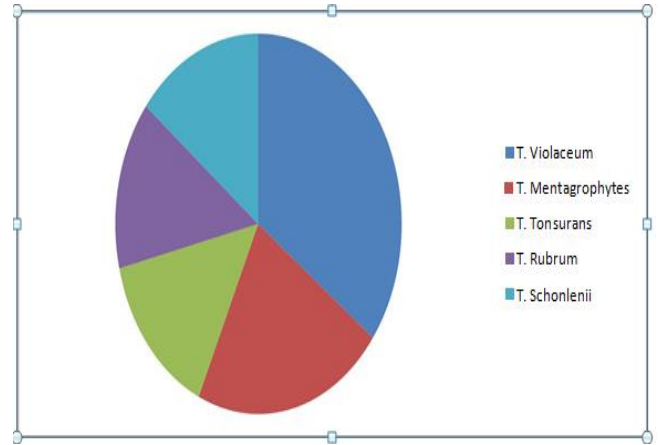


Figure 1: Proportion of dermatophytes cultured from patients of tinea capitis.

Table 1: Characteristics and clinical presentation of tinea capitis patients.

Age (years)	Sex	Delay in diagnosis	Clinical presentation	Culture	History
70	F	9m	Numerous pustules throughout scalp with scaling and alopecia, numerous scaly plaques all over body	<i>T. rubrum</i>	Corticosteroid therapy
50	F	2y	Multiple ulcerations covered with black eschar, which on removal showed purulent discharge	<i>T. violaceum</i> , <i>Candida</i> tropicals	-
60	F	5m	Diffuse yellow crusting with patches of cicatricial alopecia	<i>T. schoenleinii</i>	-
47	F	6m	Multiple patches of alopecia with pustules, slight scaling	<i>T. tonsurans</i>	-
64	F	1yr	Multiple patches of cicatricial alopecia with surrounding pustules and dirty yellow crusts	<i>T. mentagrophytes</i>	-
45	F	3m	Black dot	<i>T. violaceum</i>	-
39	F	2m	Multiple follicular papules and nodules, with slight scaling over occipital area	<i>T. mentagrophytes</i>	-
56	F	6m	Multiple crusted papules all over scalp with loss of hair	<i>T. violaceum</i>	-
64	F	1m	Multiple boggy swellings, studded with pustules	<i>T. mentagrophytes</i>	-
52	F	3m	Multiple patches of alopecia with pustules, slight scaling	<i>T. tonsurans</i>	-
61	F	2m	Patches hair loss covered with dirty yellow crusts	<i>T. schoenleinii</i>	-
44	F	1m	Patch of alopecia covered with scales and few pustules	<i>T. violaceum</i>	-
60	F	1.5m	Black dot	<i>T. violaceum</i>	-
62	F	1m	Solitary plaque covered with fine scales with loss of hair	<i>T. rubrum</i>	-

F = females, y = years, m = months, T= trichophyton.

DISCUSSION

Tinea capitis is invasion of the hair by dermatophytes. It is considered rare after puberty. The relative resistance of of adult hair to colonization by dermatophytes is believed to be due to fungistatic properties of long chain fatty acids of the sebum produced after puberty. Impairment of health and immunity is an important factor predisposing adults to tinea capitis. Some unknown immunological factors may also be involved in such rareness.¹ Although tinea capitis was once thought to be rare in adults, growing number of authors have reported increase in incidence among adults. Clinical presentation in such case is often atypical leading to delay in diagnosis. We had a relative frequency of 3.06% of tinea capitis in adults which is consistent with literature.^{4,8}

There have been conflicting reports about sexual predominance of tinea capitis in preadolescent children with some reporting predominance of boys, where shorter hair is believed to allow easy access for circulating spores, others have reported increased incidence in girls due to tight hair braiding.^{9,10} In adults tinea capitis has been particularly reported from elderly, post- menopausal females.² In our study all patients were females, 11 postmenopausal. This may be related to increased involution of sebaceous glands following decreased blood estrogen levels in post-menopausal women.³⁻⁵ Frequent visits to hairdresser and taking care of children has been proposed in some studies as a cause of higher incidence in females.^{11,12}

Impairment of immunity is an important predisposing factor for tinea capitis in elderly.¹³⁻¹⁵ One patient who was on chronic corticosteroid therapy for chronic autoimmune urticaria presented with widespread cutaneous lesions along with numerous pustules with scaling and alopecia on scalp. The culture was positive for *T. rubrum* and was hence diagnosed as *T. rubrum* syndrome.¹³

The epidemiology of Tinea Capitis varies within different geographical areas in the world. *M. canis* is the most common causative agent in the Europe, whereas *T. tonsurans* is most frequently isolated in the United States, the United Kingdom and Canada.¹⁶⁻¹⁸

In our study *T. violaceum* was most common causative agent responsible for 35% of cases. Similar results were seen in a study conducted on children in Northern India, though there are no such studies in adult population.¹⁹

Griseofulvin remains the treatment of choice for Tinea capitis, but both terbinafine and itraconazole are considered acceptable alternatives.^{2,20} All patients except one responded to 6-8 weeks course of terbinafine 250 mg OD. One patient which showed *candida tropicalis* and *T. violaceum* on culture was put on Itraconazole 100mg BD for 8 weeks, after which lesions healed with scarring.

CONCLUSION

Tinea capitis in adults is not so rare, particularly in post-menopausal women. The presentation is often atypical mimicking other inflammatory conditions of scalp and should be included as a differential diagnosis of inflammatory conditions not responding to conventional treatment.

Funding: No funding sources

Conflict of interest: None declared

Ethical approval: The study was approved by the Institutional Ethics Committee

REFERENCES

1. Sacchidanand S, Savitha A, Aparna A, Shilpa K. Significance of scraping scalp lesions in adults. Int J Trichology. 2012;4:48-9.
2. Morell L, Fuente MJ, Boada A, Carrascosa JM, Ferrandiz C. Tinea capitis en mujeres de edad avanzada: descripción de 4 caso. Actas Dermosifiliogr. 2012;103:144-8.
3. Elewski E. Tinea Capitis: A Current Perspective. J Am Acad Dermatol. 2000;42(1):1-20.
4. Mebazza A, Oumari KE, Ghariani N, Mili AF, Belajouza C, Nouria R, et al. Tinea Capitis in Adults in Tunisia. Int J Dermatol. 2010;49(5):513-6.
5. Gianni C, Betti R, Perrota E, Crosti C. Tinea Capitis in Adults. Mycosis. 1995;38(7-8):329-31.
6. Barlow D & Saxe N. Tinea capitis in Adults. Int J Derm. 1988;27:388-90.
7. Ahmad SM, Wani GM, Khursheed B. Kerion mimicking bacterial infection in an elderly patient. Indian Dermatol Online J. 2015;6(6):387-92.
8. Ziemer A, Kohl K, Schröder G. "Trichophyton Rubrum Induced Inflammatory Tinea Capitis in a 63-Year Old Man. Mycoses. 2005;48(1):76-9.
9. Friedlander SF, Rueda M, Chen BK, Caceres- Rios HH. Fungal, Protozoal and Helminthic infections. In: Schachner LA, Hansen RC, editors. Pediatric Dermatology. 3rd ed, Mosby; 2003:1093-140
10. Chen BK, Friedlander SF. Tinea Capitis update; a continuing conflict with an old adversary. Curr Opin Pediatr. 2001;13:331-5.
11. Vidimos AT, Camisa C, Tomecki KJ. Tinea capitis in three adults. Int J Dermatol. 1991;30(3):206-8.
12. Takwale A, Agarwal S, Holmes SC, Berth-Jones J. Tinea capitis in two elderly women: Transmission at the Hairdresser. Br J Dermatol. 2001;144(4):898-900.
13. Piñeiro L, Larruskain J, Idigoras P, Pérez-Trallero E. "Trichophyton rubrum Syndrome: The Tip of the Iceberg and a Preventable Outcome. Mycoses. 2010;53(2):186.
14. Lateur N, André J, De Maubeuge J, Poncin M and Song M. "Tinea Capitis in Two Black African Adults with HIV Infection. Br J Dermatol. 1999;140(4):722-4.

15. Narang K, Pahwa M, Ramesh V. Tinea Capitis in the Form of Concentric Rings in an HIV Positive Adult on Antiretroviral Treatment. *Indian J Dermatol.* 2012;57(4):288-90.
16. Ginter-Hanselmayer G, Weger W, Ilkit M, Smolle J. Epidemiology of tinea capitis in Europe: current state and changing patterns. *Mycoses.* 2007;50;6-1.
17. Babel DE, Baughman SA. Evaluation of adult carrier state in Juvenile tinea capitis caused by *Trichophyton tonsurans*. *J Am Acad Dermatol.* 1989;21:1209-12.
18. Trivino- Duran L, Torres- Rodriguez JM, Martinez-Roig A, Cortina C, Bolver V, Perez-Gonzekz M, et al. Prevalence of tinea capitis and tinea pedis in Barcelona School children. *Pediatr Infect dis J.* 2005;24:137-41.
19. Grover C, Arora P, Manchanda PV. Tinea capitis in the pediatric population: A study from North India. *Indian J Dermatol Venereol Leprol.* 2010;76:527-32.
20. Cevetti O, Albini P, Arese V, Ibba F, novarino M, Panzone M. Tinea capitis in Adults. *Adv Microbiol.* 2014;4:12-4.

Cite this article as: Ahmed SM, Rather SR, Kousar H, Bukhari S. Tinea capitis in adults: not so rare. *Int J Res Med Sci* 2016;4:5426-9.